

Medical Science

To Cite:

Kołodziejczyk A, Świątko M, Sosnowski P, Rybak J, Grzebyk M, Tokarska A, Arnista A, Gawrońska K, Waszczuk A, Łapiński P. Methods used in the rehabilitation and treatment of scoliosis. *Medical Science* 2025; 29: e143ms3642
doi: <https://doi.org/10.54905/disssi.v29i162.e143ms3642>

Authors' Affiliation:

Aleksandra Kołodziejczyk, District Hospital in Grójec, 05-600 Piotra Skargi 10, Grójec, Poland

*Corresponding author:

Aleksandra Kołodziejczyk, District Hospital in Grójec, 05-600 Piotra Skargi 10, Grójec, Poland, email: aleksandra.kolodziejczyk19@gmail.com

Peer-Review History

Received: 09 April 2025
Reviewed & Revised: 18/April/2025 to 09/August/2025
Accepted: 18 August 2025
Published: 25 August 2025

Contact list:

Aleksandra Kołodziejczyk	aleksandra.kolodziejczyk19@gmail.com
Mateusz Świątko	mateusz.swiatko@gmail.com
Paweł Sosnowski	pawelsosno@gmail.com
Joanna Rybak	asia.rybak307@gmail.com
Marcin Grzebyk	marcin.grzebyk@gmail.com
Anna Tokarska	aniatokarska.98@gmail.com
Aleksandra Arnista	aleksandra.arnista0605@gmail.com
Katarzyna Gawrońska	gawronskakatarzyna1@gmail.com
Agnieszka Waszczuk	waszczukaga@gmail.com
Piotr Łapiński	piotr.konstanty13@gmail.com

ORCID list:

Aleksandra Kołodziejczyk	0009-0001-3955-724X
Mateusz Świątko	0009-0003-0467-1290
Paweł Sosnowski	0009-0008-0097-3669
Joanna Rybak	0009-0005-3815-4149
Marcin Grzebyk	0000-0002-7647-1226
Anna Tokarska	0009-0003-8601-4269
Aleksandra Arnista	0009-0000-1274-1373
Katarzyna Gawrońska	0009-0004-7378-1626
Agnieszka Waszczuk	0009-0009-9201-1391
Piotr Łapiński	0009-0005-5740-3016

Peer-review Method

External peer-review was done through double-blind method.

Medical Science

pISSN 2321-7359; eISSN 2321-7367



© The Author(s) 2025. Open Access. This article is licensed under a [Creative Commons Attribution License 4.0 \(CC BY 4.0\)](https://creativecommons.org/licenses/by/4.0/), which permits use, sharing, adaptation, distribution and reproduction in any medium or format, as long as you give appropriate credit to the original author(s) and the source, provide a link to the Creative Commons license, and indicate if changes were made. To view a copy of this license, visit <http://creativecommons.org/licenses/by/4.0/>.



Methods used in the rehabilitation and treatment of scoliosis

Kołodziejczyk A*, Świątko M, Sosnowski P, Rybak J, Grzebyk M, Tokarska A, Arnista A, Gawrońska K, Waszczuk A, Łapiński P

ABSTRACT

The aim of this paper is to review and characterize the current rehabilitative and conservative methods used in the treatment of scoliosis. The importance of diagnosis is discussed and special attention is given to the effectiveness of modern physiotherapeutic methods, such as the Schroth method, FITS and SEAS. These methods show great effectiveness in stabilizing and slowing the progression of curvature. The role of corset treatment and indications for surgical treatment are also presented. The paper emphasizes the importance of an individual approach to the patient.

Keywords: idiopathic scoliosis, rehabilitation, scoliosis treatment, Cobb angle

1. INTRODUCTION

Scoliosis is primarily classified based on its underlying cause. Congenital scoliosis results from defects in vertebral formation or segmentation that may lead to progressive spinal deformity as the child grows. Neuromuscular scoliosis arises due to disorders of the central nervous system (e.g., spastic quadriplegia), peripheral neuromuscular unit (e.g., muscular dystrophies or spinal muscular atrophy), or combined motor and sensory dysfunctions (e.g., syringomyelia). Scoliosis is also frequently observed in patients with neurofibromatosis and certain connective tissue disorders such as Marfan syndrome or Ehlers–Danlos syndrome. In most cases, the cause remains unknown, resulting in a diagnosis of idiopathic scoliosis, which is further subdivided into infantile (birth to 3 years), juvenile (3–10 years), adolescent (>10 years), and adult types.

In adulthood, scoliosis may develop secondary to degenerative disc disease. First-degree relatives of affected individuals carry approximately a 10% risk, suggesting a genetic contribution, although the exact genes involved remain unidentified. Trunk and chest asymmetry, the key element of physical screening for scoliosis, is relatively common in otherwise healthy school-age children (Wawrzyniak et al., 2017). Complete postural symmetry is seen in only about 1.6% of adolescents. In a school-based screening of over 2000 children, 4.1% demonstrated abnormal findings on visual inspection and Adams forward-bend test, 1.8% had idiopathic scoliosis exceeding 10° and 0.4% required active treatment. In growing children, the primary consequence of scoliosis is trunk deformity, with

shoulder or waist asymmetry, trunk imbalance, and rib rotation. A 50-year natural history study of untreated idiopathic scoliosis revealed that cosmetic disfigurement remained the dominant concern into adulthood. Mild discomfort is frequent in children with significant curves, whereas severe pain that interferes with sleep or function is uncommon and warrants evaluation for underlying conditions, including spinal tumors, infection, Chiari I malformation with syrinx, or tethered cord syndrome (Wawrzyniak et al., 2017). For most patients, idiopathic scoliosis does not progress. Progression risk increases in girls, in those with larger curves, and in the presence of remaining growth potential. Natural history studies indicate that curves $<30^\circ$ at skeletal maturity rarely worsen, whereas curves $>50^\circ$ progress in adulthood at a rate of $0.75\text{--}1^\circ$ per year. Thus, an immature patient with a curve of $>25\text{--}30^\circ$ is considered at risk for progression. Lung development requires normal thoracic growth, and pulmonary volume nearly doubles from age 10 to skeletal maturity. Adolescents with thoracic scoliosis exceeding 50° face a markedly increased risk of later-life dyspnea (odds ratio ~ 15 at 30 years and ~ 4 at 50 years).

When thoracic idiopathic scoliosis reaches 70° , lung volumes decline below normal, and symptomatic restrictive pulmonary disease becomes familiar with curves exceeding 100° . Proper posture is the effortless alignment of the various sections of the body, unaffected by changes (Wawrzyniak et al., 2017). It is fundamental to the maintenance of musculoskeletal health and overall well-being. The term postural defects, on the other hand, can be interpreted in various ways. In a broad sense, it is a condition that deviates from the physiological state. Postural defects are also deviations that allow themselves to be actively or passively corrected, however, significant deviations from normal posture can nevertheless become fixed and lead to obvious structural changes (Zielinska, 2011). Scoliosis is three-dimensional spinal deformity characterized by lateral curvature of the spine. It is classified based on etiology into several types, including idiopathic and neuromuscular (Negrini et al., 2018). Progressive curves may lead to chronic pain, reduced pulmonary function, visible deformity and diminished quality of life.

As a result, early detection is essential. Screening protocols use clinical tools like the Adams Test and radiographic confirmation to identify scoliosis early. Management strategies are typically individualized based on curve severity, patient age, skeletal maturity and risk of progression. Conservative treatment such as scoliosis-specific exercise, bracing, and physiotherapy are widely used in growing individuals to prevent curve progression. Rehabilitation plays a vital role both as a non-surgical treatment and in the postoperative recovery process (Monticone et al., 2014).

The purpose of this paper is to provide an overview of the diagnosis and the most commonly used rehabilitation methods for the treatment of scoliosis and their effectiveness at different stages of the disease.

2. REVIEW METHODS

To conduct this review, we analyze the literature in with literature databases such as “PubMed”, “Google Scholar” and scientific databases to treatment of scoliosis. Our focus was on paper published between January 2011 and November 2024 using phrases “idiopathic scoliosis”, “rehabilitation”, “scoliosis treatment”, “Cobb angle”, “etiology”. The selected study duration reflects both foundational research and the most advanced in the understanding of scoliosis. We assessed the articles by titles, abstracts, and full texts. Publications that did not fall within the mentioned date range were excluded.

Objective

The aim of this systematic review was to collect and critically analyze current evidence on conservative management strategies for idiopathic scoliosis, with particular emphasis on contemporary physiotherapeutic approaches, including the Schroth, FITS, and SEAS methods.

Eligibility Criteria

We included original and review articles published between January 2011 and November 2024 that evaluated non-pharmacological, non-surgical interventions for idiopathic scoliosis. Studies involving children, adolescents, and adults were considered if the primary goal was to halt curve progression or improve functional and postural outcomes. Exclusion criteria comprised publications outside the specified date range, studies focused on other scoliosis types, and those solely addressing surgical management.

Information Sources

A systematic search was conducted in PubMed and Google Scholar databases. The last search was performed in November 2024.

Search Strategy

The search was performed in English and Polish, applying filters to limit results to studies published within the last 13 years. Clinical trials, observational studies, systematic reviews, and meta-analyses were eligible.

Selection Process

The selection process was carried out in three stages:

1. title screening,
2. abstract evaluation,
3. full-text review for eligibility. Two independent reviewers screened the studies, and disagreements were resolved through discussion.

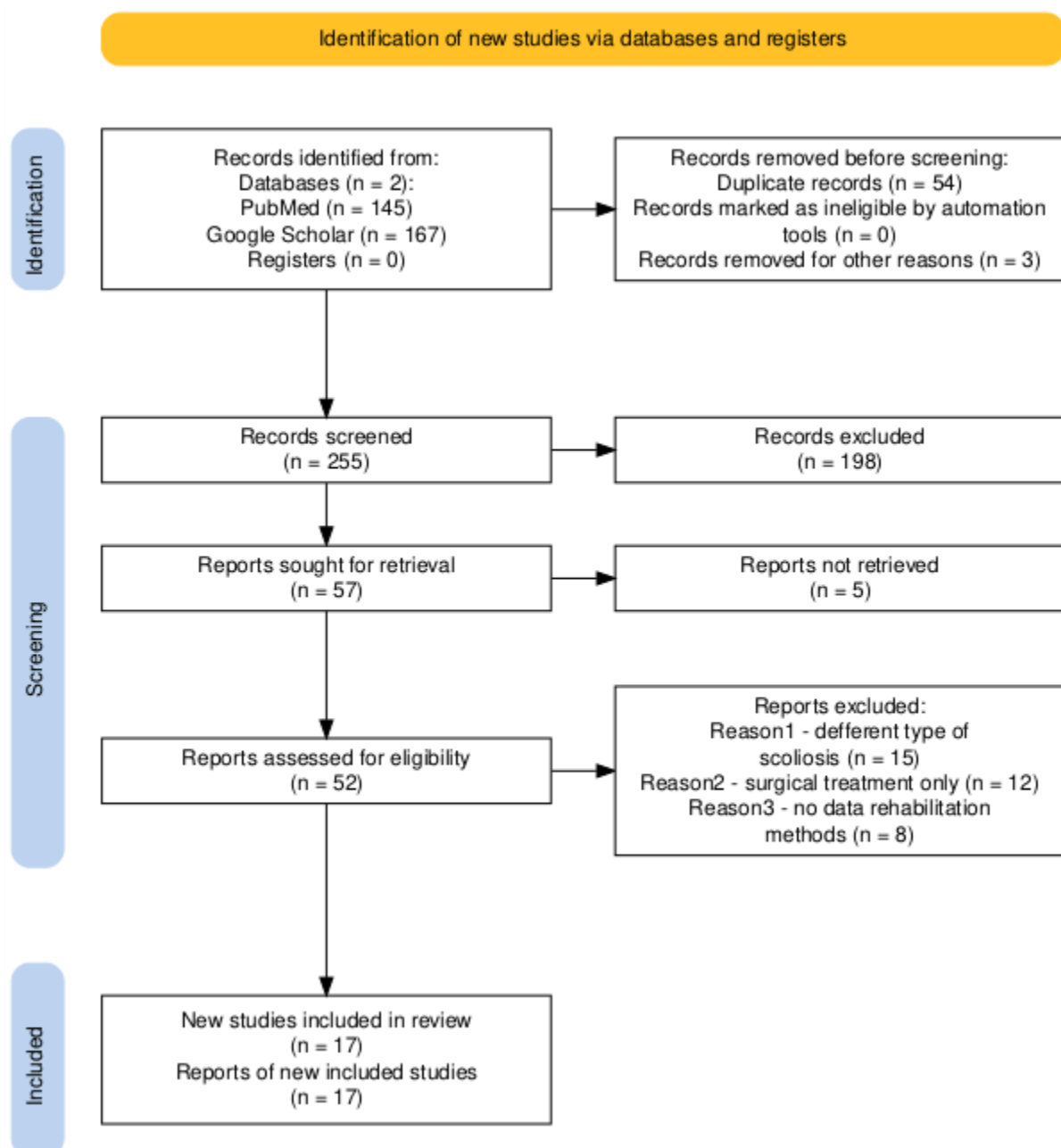


Fig. 1. The flow diagram of the study selection process

Data Collection Process

From each included study, we extracted data on: study population characteristics (age, sample size, baseline Cobb angle), intervention type, therapy duration, primary clinical outcomes, and reported effects.

Risk of Bias Assessment

The risk of bias was assessed based on methodological clarity, sample selection, and result consistency.

Effect Measures

For each study, we reported key effect measures, including change in Cobb angle (°), percentage of patients with halted curve progression, improvement in functional test results, and quality-of-life scores.

Synthesis Methods

Due to heterogeneity in study designs, a narrative synthesis was conducted to compare the effectiveness of different interventions.

Certainty Assessment

The certainty of evidence was assessed based on the number of high-quality studies, consistency of findings, and sample sizes. The selection process is shown in Figure 1.

3. RESULTS AND DISCUSSION

3.1. Epidemiology

Scoliosis is a three-plane curvature of the spine, which can include lateral curvature (in the frontal plane), vertebral rotation (in the transverse plane) and physiological curvature abnormalities (in the sagittal plane; Negrini et al., 2021). As established by the Scoliosis Research Society, the medical definition of scoliosis, describes a spinal curvature that exceeds 10 degrees when viewed through X-ray images (Kuliński, 2023). The deformity may also involve the thorax, pelvis, limbs, as well as internal organs, and the consequence of the deformity may be circulatory and respiratory disorders (Barczyk et al., 2009).

3.2. Etiology

There are different types of scoliosis in terms of etiology (Jarman and Arlet, 2022).

Idiopathic scoliosis - the most common form of scoliosis, the cause of which is unknown but often occurs during adolescence.

Congenital scoliosis - caused by abnormalities in the development of the bones and spine. Neuromuscular scoliosis is associated with neurological and muscular diseases, such as cerebral palsy or muscular dystrophy.

Idiopathic scoliosis is a multifactorial disease and accounts for more than 90% of all scoliosis, but to date the cause has not been established. Many studies are devoted to the genetic basis of this disease, but none of the formulations have found definitive confirmation as the main cause (Peng et al., 2023).

3.3. Pathogenesis

Scoliosis is a multifactorial disease, consisting of both genetic factors, which have been shown to have a familial occurrence, nervous system disorders, biomechanical factors and hormonal. Postural defects can also result from chronic medical conditions or improper weight-bearing by the child and metabolic factors. In some patients with idiopathic scoliosis, we observe reduced bone mineral density. The formation of the curvature of the spine is observed at school age around 7- 8 years. The period that will most affect the deterioration of posture up to this point is the time of sexual maturation. Mental and physical fatigue appear at that time, which causes changes in the care of proper maintenance of the figure. The most common cause of postural defects is muscle hypotonia, which causes weakness, difficulty in working properly and lack of postural control. Postural defects can also result from chronic medical conditions or improper weight-bearing by the child (Barczyk et al., 2009). The lack of physical activity stands as one of the causes because it leads to muscle laxity and prevents proper muscle strength development (Li et al., 2024).

3.4. Diagnosis

The diagnosis of scoliosis requires a complete evaluation that combines medical history with clinical assessment and imaging studies. The following are essential in establishing a diagnosis (Hutchins et al., 2021).

a. Medical history: Inquire about the family history of scoliosis or other spinal deformities. Age of symptom onset, pain complaints, or discomfort.

b. Clinical trials: Visual inspection of posture: asymmetry of shoulders, shoulder blades or pelvis tilt. Measurement of lower limb length, assessment of muscle tone. Adams test - assessment of trunk rotation to visualize any spinal deformities. The patient ends forward while the examiner observes for asymmetry in the back.

c. Measurement of the trunk rotation angle

d. Imaging diagnostics: Radiology and other imaging techniques (X-ray, MRI, CT), the most useful is an X-ray in the anterolateral plane covering the entire spine (Gustowski, 2019). The X-ray is presented as a measure of skeletal maturity in the Risser category from 0 to 5 (Chopra et al, 2020). Cobb angle -the basic parameter that determines the degree of curvature (Table 1).

e. Bone maturity assessment: Risser scale - determines the degree of ossification of the hip plates, which aids in predicting the likelihood of curve progression.

f. Advanced Imaging Techniques: MRI and CT scans can be valuable tools in evaluating spinal cord involvement in complex cases.

Table 1. Definition of Cobb angle

Cobb angle	Definition
0°–10°	Spinal curve
10°–20°	Mild scoliosis
20°–40°	Moderate scoliosis
>40°	Severe scoliosis

3.5. Differential Diagnosis

Differential diagnosis from other spinal abnormalities such as kyphosis, vertebral deformities due to tumors, trauma, or infections is a critical step in clinical evaluation. While these conditions may present with spinal asymmetry, they often have a distinct cause.

3.6. Treatment

The primary objectives of treatment involve decreasing respiratory distress while treating pain syndrome and enhancing patient appearance through posture improvement (Dimirijevic et al., 2022). The treatment of scoliosis should be divided into conservative and surgical, which depends on the size of the curvature angle, the child's age and progressive features (Gao et al., 2021). Other features that characterize specific therapy include individualized therapy selection, considering scoliosis pattern and size, progression risk, and patient needs. Educate the patient, inform caregivers and students about the indications and consequences of scoliosis.

Active corrective spine movement:

Maintaining a corrected spinal position throughout the day, reducing sedentary behavior and encouraging regular movement breaks, ergonomic adjustments in daily activities - wearing backpacks on both straps, Stability training conducted in a properly corrected posture (Białek, 2014). Rehabilitation for scoliosis focuses on stabilizing the spinal curvature, improving posture, increasing range of motion and muscle strength, and reducing pain. Tailored to the individual condition and degree of Cobb's angle, these interventions play a vital role in conservative treatment.

1) *Kinesitherapy*

- The exercises should be asymmetrical to match each person's muscle tension levels.
- The corrective exercises function to position the trunk correctly while maintaining proper posture alignment.

- The breathing exercises enhance lung ventilation because they are essential for people with chest deformities.
- The exercises should include stretching and strengthening of back muscles and abdominal muscles and buttock muscles.

2) Specialized methods

- Schroth method: the most well-known specialized therapy based on exercises to correct spinal curvature through specially designed positions and breaths. The exercises developed in this method are designed to improve spinal alignment, spinal capacity and reduce pain (Table 2). The patient learns to visualize their deformities through a mirror which enables them to perform self-correction of posture (Dimitrijević, 2022).
- The SEAS method is a program of individual exercises based on self-correction and PS.
- Klapp method: exercises in supporting positions, strengthening the spinal muscles
- PNF: A technique for improving neuromuscular control and coordination

3) Physical therapy - ancillary to relieve pain and muscle tension:

- Electrostimulation
- Laser therapy
- Cryotherapy
- Ultrasound
- Cryotherapy
- Magnetotherapy

4) **Manual therapy:** Manual techniques such as joint mobilization, tight muscle relaxation, and spine range of motion improvement, orthopedic treatments.

5) **Correction with orthopedic corsets** - using corsets, such as the Cheneau corset, for scoliosis with a curvature angle of more than 20-30 degrees to stop the progression of the deformity, and the Milwaukee corset used mainly in thoracic scoliosis. According to a 2013 study by Bracing in Adolescent Idiopathic Scoliosis Trial, showed that corsets can significantly slow the progression of mild to moderate curvature (Kuznia et al., 2020).

6) **Surgical methods** - used in cases of advanced scoliosis when other methods are unsuccessful, it is the treatment of choice for curvatures above 45 to 50 degrees (Chopra et al., 2020).

Table 2. Summary of reviewed studies on Treatment Methods for Idiopathic Scoliosis.

Method	Study Type	Patient Group	Key Findings	Effectiveness
Schroth	RCT (Ceballos-Laita et al., 2023)	Adolescents	Improved Cobb angle, posture, and quality of life.	High
SEAS	Systematic Review (Negrini et al., 2015)	Children and adolescents	Curve progression halted in 88% of patients.	Very High
FITS	Observational (Białek et al., 2014)	Children with mild/moderate scoliosis	Reduced pain, improved muscle balance.	High
Bracing	Clinical Trial (Kuznia et al., 2020)	Adolescents	Bracing effective for curves 20–40°, especially with daily use ≥18 hrs.	Moderate–High
Manual Therapy	Case Series (Dimitrijević, 2022)	Mixed (10–18 years)	Improvement in spinal flexibility and reduced discomfort.	Moderate
Kinesitherapy	Longitudinal Study (Dimitrijević, 2022)	Children 8–14 years	Enhanced muscle strength, posture, and balance.	Moderate

3.7. Prognosis

Early introduction of rehabilitation, especially in the Schorth method, can significantly reduce the degree of spinal curvature, enhance postural alignment, and alleviate discomfort. Studies show a reduction in Cobb angle by several degrees using the method for min. 6 months, significant improvements in body symmetry, respiratory function and subjective quality of life (Weiss et al., 2016). Influencing the effectiveness of rehabilitation are:

- a. Patient age:* The best results are obtained in children and adolescents during the growth period.
- b. Cobb angle:* Curvature up to 25° - often manages to stabilize completely. 25-40 - intensive rehabilitation and often required treatment with an orthopedic corset. Above 45-50 - indications for surgery but supportive value of rehabilitation.
- c. Type and frequency of therapy:* SEAS method - in comparative studies, scoliosis progression has been shown to be arrested in more than 88% of cases (Negrini et al., 2015). FITS - have shown high efficacy, with clinical reports showing improved muscle balance and reduced pain (Białek, 2014).
- d. Performing exercises every day &* involving the patient and family, it is also worthwhile to provide adequate psychosocial support to promote the overall well-being of individuals diagnosed with scoliosis.

In particular, it has been proven to halt the progression of curvature in patients with mild scoliosis. Patients with a Cobb angle of 10 to 45 degrees have been reported to have an improved quality of life with appropriately tailored rehabilitation (Watanabe et al., 2020). Orthopedic corsets play an effective role in managing the progression of the defect of idiopathic scoliosis in children and adolescents. When conservative treatments fail, surgical procedures can stabilize the spine and improve quality of life.

4. CONCLUSION

Scoliosis is a condition that requires multi-stage and individualized treatment. Physical rehabilitation, including the Schroth method, is an effective therapy for reducing scoliosis symptoms and improving posture. SEAS method - has proven results in stopping the progression of curvature without the need for surgical intervention. Tailoring the rehabilitation approach to the patient's age and the severity of their scoliosis can play a decisive role in enhancing overall quality of life and in effectively preventing further progression of the spinal deformity. As a result, well-chosen rehabilitation can halt the progression of scoliosis, reduce curvature, alleviate pain, and improve posture and symmetry, ultimately enhancing respiratory capacity.

Acknowledgments

The authors have no acknowledgments to disclose.

Informed consent

Not applicable.

Ethical approval

Not applicable.

Funding

This study has not received any external funding.

Conflict of interest

The authors declare that there is no conflict of interest.

Data and materials availability

All data associated with this work are present in the paper.

REFERENCES

1. Barczyk K, Zawadzka D, Hawrylak A, Bocheńska A, Skolimowska B, Małachowska-Sobieska M. The influence of corrective exercises in a water environment on the shape of the antero-posterior curves of the spine and on the functional status of the locomotor system in children with Io scoliosis. *Ortop Traumatol Rehabil.* 2009;11(3):209-21.

2. Białek M. FITS concept: functional individual therapy of scoliosis. *Scoliosis*. 2014;9 (Suppl 1):O50 135, 250–261.
3. Ceballos-Laita L, Carrasco-Uribarren A, Cabanillas-Barea S, Pérez-Guillén S, Pardos-Aguilella P, Jiménez Del Barrio S. The effectiveness of Schroth method in Cobb angle, quality of life and trunk rotation angle in adolescent idiopathic scoliosis: a systematic review and meta-analysis. *Eur J Phys Rehabil Med* 2023;59(2):228-236. doi: 10.23736/S1973-9087.23.07654-2
4. Chopra S, Larson AN, Kaufman KR, Milbrandt TA. Accelerometer based assessment of daily physical activity and sedentary time in adolescents with idiopathic scoliosis. *PLoS One* 2020;15(9):e0238181. doi: 10.1371/journal.pone.0238181.
5. Dimitrijević V, Šćepanović T, Jevtić N, Rašković B, Milankov V, Milosević Z, et al. Application of the Schroth method in the treatment of idiopathic scoliosis: A systematic review and meta-analysis. *Int J Environ Res Public Health* 2022;19(24):16730. doi:10.3390/ijerph192416730.
6. Gao A, Li J-Y, Shao R, Wu T-X, Wang Y-Q, Liu X-G, et al. Schroth exercises improve health-related quality of life and radiographic parameters in adolescent idiopathic scoliosis patients. *Chin Med J (Engl)* 2021;134(21):2589–96. doi: 10.1097/CM9.0000000000001799.
7. Gustowski D. Trunk muscle strength of girls with idiopathic scoliosis treated conservatively with a corset and kinesitherapy [Doctoral dissertation]. 2019.
8. Hutchins TA, Peckham M, Shah LM, Parsons MS, Agarwal V, Boulter DJ, Burns J, Cassidy RC, Davis MA, Holly LT, Hunt CH, Khan MA, Moritani T, Ortiz AO, O'Toole JE, Powers WJ, Promes SB, Reitman C, Shah VN, Singh S, Timpone VM, Corey AS. ACR Appropriateness Criteria® Low Back Pain: 2021 Update. *J Am Coll Radiol*. 2021;18(11S):S361-S379. doi: 10.1016/j.jacr.2021.08.002.
9. Jarman JP, Arlet V. The etiology of idiopathic scoliosis: Genetic, biomechanical and neuromuscular factors. *Curr Rev Musculoskelet Med* 2022;15(2):105–116.
10. Kuliński W. Physical therapy in the prevention of disability in the elderly. *OAJ Gerontol & Geriatric Med* 2023;7(4). doi: 10.19080/OAJGGM.2023.07.555717.
11. Kuznia AL, Hernandez AK, Lee LU. Adolescent idiopathic scoliosis: Common questions and answers. *Am Fam Physician* 2020;101(1):19–23.
12. Li J, Gao J, Zhao Z, Canavese F, Cai Q, Li Y. Quantitative computed tomography assessment of bone mineral density in adolescent idiopathic scoliosis: correlations with Cobb angle, vertebral rotation, and Risser sign. *Transl Pediatr* 2024;13(4):610–23. doi: 10.21037/tp-24-74.
13. Monticone M, Ambrosini E, Cazzaniga D, Rocca B, Ferrante S. Active self-correction and task-oriented exercises reduce spinal deformity and improve quality of life in subjects with mild adolescent idiopathic scoliosis: results of a randomised controlled trial. *Eur Spine J* 2014;23(6):1204–1214. doi: 10.1007/s00586-014-3241-y.
14. Negrini S, Donzelli S, Aulisa AG, Zaina F, Romano M, Negrini A. 2016 SOSORT guidelines: Orthopaedic and Rehabilitation treatment of idiopathic scoliosis during growth. *Scoliosis Spinal Disord* 2015;10:3. doi: 10.1186/s13013-017-0145-8.
15. Negrini S, Donzelli S, Aulisa AG, Zaina F, Romano M, Negrini A. 2016 SOSORT guidelines: Orthopaedic and rehabilitation treatment of idiopathic scoliosis during growth. *Scoliosis Spinal Disord* 2018;13:3. doi: 10.1186/s13013-017-0145-8.
16. Negrini S, Donzelli S, Zaina F, Romano M, Negrini A, Aulisa AG. The 2021 SOSORT guideline on scoliosis conservative treatment. *Scoliosis Spinal Disord* 2021;16(1):1–48.
17. Peng Y, Wang SR, Qiu GX, Zhang JG, Zhuang QY. Research progress on the etiology and pathogenesis of adolescent idiopathic scoliosis. *Chin Med J (Engl)* 2020;133(4):483–93. doi: 10.1097/cm9.0000000000000652
18. Watanabe K, Masayuki M, Hirano T, Katsumi K, Mizouchi T, Tashi H, Minato K, Hasegawa K, Endo N. Health Related Quality of Life in Nonoperated Patients with Adolescent Idiopathic Scoliosis in the Middle Years. A mean 25-year follow-up study. *Spine (Phila Pa 1976)* 2020;45(2):E83–9. doi: 10.1097/BRS.0000000000003216.
19. Wawrzyniak A, Tomaszewski M, Mews J, Jung A, Kalicki B. Postural defects in children and teenagers as one of the major issues in psychosomatic development. *Pediatr Med Rodz* 2017; 13 (1):72–78. doi: 10.15557/PiMR.2017.0007
20. Weiss HR, Moramarco M. Outcomes of scoliosis-specific exercise therapy – a review of the literature. *J Phys Ther Sci* 2016;28(7):2087–2095. doi: 10.13172/2052-9287-1-1-
21. Zielinska I. Thoracic deformity and respiratory mobility in children with idiopathic scoliosis [Doctoral dissertation]. 2011. <https://tiny.pl/02nwhcc2>