

Medical Science

To Cite:

Al-Bluwi BM, Alabdullah AA, Alsaeed MI. Skin Manifestation of COVID-19: A systematic review. *Medical Science* 2024; 28: e136ms3457
doi: <https://doi.org/10.54905/disssi.v28i153.e136ms3457>

Authors' Affiliation:

¹Dermatology Consultant, Dammam Medical Complex, Eastern Province, Saudi Arabia

²Dermatology Senior Registrar, Alahsa Health Cluster, Saudi Arabia

³MBBS, King Abdulaziz Medical City, Alahsa, Eastern Province, Saudi Arabia

Peer-Review History

Received: 01 August 2024

Reviewed & Revised: 05/August/2024 to 26/October/2024

Accepted: 30 October 2024

Published: 12 November 2024

Peer-review Method

External peer-review was done through double-blind method.

Medical Science

pISSN 2321-7359; eISSN 2321-7367



© The Author(s) 2024. Open Access. This article is licensed under a [Creative Commons Attribution License 4.0 \(CC BY 4.0\)](https://creativecommons.org/licenses/by/4.0/), which permits use, sharing, adaptation, distribution and reproduction in any medium or format, as long as you give appropriate credit to the original author(s) and the source, provide a link to the Creative Commons license, and indicate if changes were made. To view a copy of this license, visit <http://creativecommons.org/licenses/by/4.0/>.

Skin Manifestation of COVID-19: A systematic review

**Bushra Mohammed Al-Bluwi¹, Ali Ahmed Alabdullah²,
Mohammed Ibrahim Alsaeed³**

ABSTRACT

Introduction: The SARS-CoV-2 virus causes COVID-19, a disease linked to skin symptoms including rash, erythema, and urticaria. However, the exact mechanisms by which COVID-19 leads to these skin changes are not fully understood. Our review aimed to analyze the main skin issues linked to COVID-19 and any possible underlying biological pathways in COVID-19 patients. **Design of the study:** Systematic review. **Methods:** Between January 1, 2020, and December 10, 2022, the authors conducted a bibliographic search in the databases PubMed, B-on, Scopus, and Web of Science, in order to collect relevant studies. Inclusion criteria included case series or comparative studies of COVID-19 cutaneous manifestations in various age ranges. **Results:** The evaluation found 26 articles that met the inclusion criteria, including case reports, series, and observational studies. The investigations comprised 547 people with COVID-19 who had skin symptoms. A systematic analysis of the literature on skin manifestations in COVID-19 discovered that erythema was the most common skin symptom, occurring in 44.18% of the 547 individuals included in the research. Skin lesions appeared 9.92 days after the onset of systemic symptoms such as fever, cough, and trouble breathing. Other skin signs were chilblain-like lesions, urticaria-like lesions, vesicular lesions, livedo/necrosis, and petechiae. 44.77% of patients reported significant itching. The most common systemic symptom among the 431 patients with information on this was fever, followed by coughing, exhaustion, difficulties breathing, headaches, gastrointestinal issues, and a loss of smell or taste. **Conclusion:** Understanding of the most common skin issues related to the infection of COVID-19 would help in early diagnosis of COVID-19 and improve the patients outcomes. The current review provided a comprehensive overview of the skin disorders related to COVID-19 and its potential causes. Future studies should be large and well-designed.

Keywords: COVID-19, Skin Manifestations, Erythema, Urticaria, Chilblain- Like Lesions, Vesicular Lesions, Livedo/Necrosis, Petechiae

1. INTRODUCTION

COVID-19, caused by the SARS-CoV-2 virus, had had a significant influence on worldwide public health (Pollard et al., 2020). The virus primarily affects the respiratory system; however, infection can also occur in other organs and systems in the body. The condition can be minor or severe, and it can cause significant complications such as pneumonia and mortality (Bozzalla-Cassione et al., 2020). The virus spreads by respiratory droplets and close contact with infected individuals (Dan et al., 2021). SARS-CoV-2 is a Beta coronavirus with a unique enclosed, positive-sense, single-stranded RNA structure. Its primary mode of entry and infection is ACE2, a protein present in various human tissues (Shukla and Banerjee, 2021). Although the virus primarily affects the respiratory system, ACE2 expression has also been observed in the gastrointestinal tract and skin.

A recent investigation of 31 distinct human tissues discovered that the small intestine, testis, kidneys, heart, thyroid, and adipose tissue had the highest levels of ACE2 expression. In contrast, blood, spleen, bone marrow, brain, blood vessels, and muscle had the lowest levels (Lubbe et al., 2020). One of the most common COVID-19 cutaneous symptoms is a rash that might appear on the trunk, face, or extremities (Genovese et al., 2021). These rashes frequently have a papular or erythematous appearance and may be followed by itching or burning. In some situations, the rash might be more severe and appear as diffuse erythema, purpuric, or urticarial lesions (Drenovska et al., 2020). Another typical skin symptom of COVID-19 is acral erythema, characterized by redness and warmth in the palms and soles (Tsai et al., 2021).

Inflammation and vasodilation in the tiny vessels of the hands and feet are the cause of this manifestation, and it may be accompanied by other symptoms like fever and myalgia. In addition to rashes and eruptions, COVID-19 can cause additional skin abnormalities, such as furunculosis, which creates painful boil-like blisters on the skin. Bacterial infection is usually causing these lesions which could associate with fever and malaise (Wollina et al., 2020). The aim of the current systematic review is to assess the prevalence of these manifestations in COVID-19 patients as well as its clinical features.

2. METHODS

Protocol and Registration

This systematic review was filed in PROSPERO under a specific number and reported using the PRISMA-NMA statement based on the study's scope, objectives, hypotheses, and methodology.

Eligibility Criteria

The inclusion criteria comprised patients of any age group who had COVID-19 and reported skin symptoms. The Newcastle-Ottawa Scale was used to evaluate the quality of observational studies. Exclusion criteria included studies reported patients with a history of skin conditions or diseases unrelated to COVID-19, studies that did not report skin manifestations specifically related to COVID-19, studies that used different methods or scales to evaluate the quality of the study, studies that did not report results for all age groups, or studies that did not include patients diagnosed with COVID-19.

Information Sources and Search

To find relevant articles and answer the review's query, the following search terms were utilized in PubMed, B-on, Scopus, and Web of Science: “(COVID-19 OR SARS-COV 2) AND (DERMATOLOGIC OR CUTANEOUS OR SKIN OR RASH OR URTICARIA OR ACRAL OR PERNIO OR CHILBLIAN OR VESICLE OR VESICULAR)” from November 2019 to November 2022 by two independent reviewers. We also manually verified the reference lists of all publications included in the final data to guarantee that no articles were overlooked during the electronic search.

Study Selection

Two independent reviewers identified studies by screening records by title and abstract, applying strict inclusion and exclusion criteria. The two independent reviewers examined the complete text of all eligible articles. Our systematic review comprised studies, case reports, and series that addressed matching criteria.

Data Collection Process

Data extraction includes patient age, gender, COVID-19 status, cutaneous manifestations, timing of cutaneous manifestation, and COVID-19 systemic symptoms.

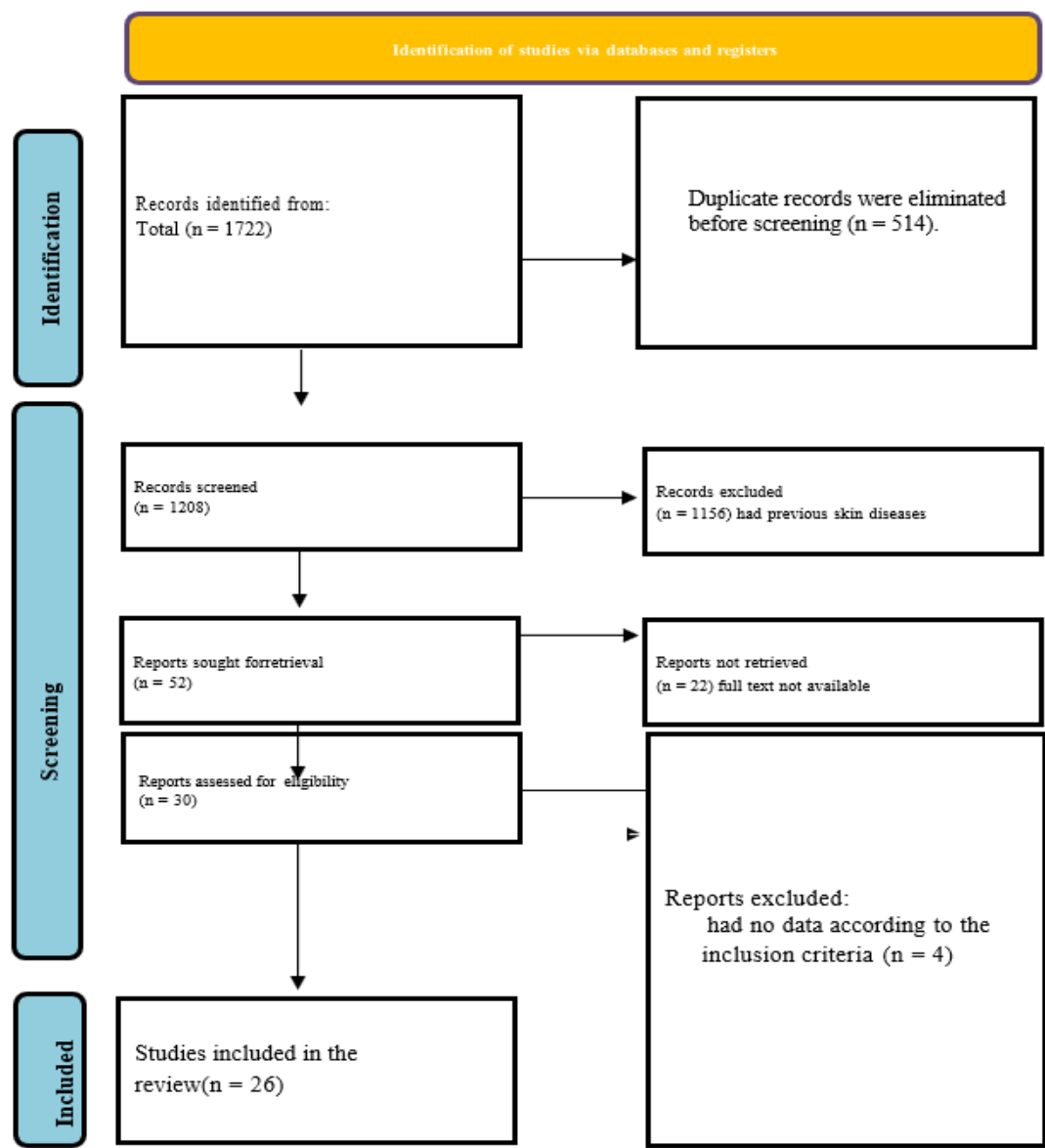


Figure 1 Identification of studies via databases and registers

3. RESULTS

Initially, the literature search yielded 1722 results, of which 514 were duplicates. Finally, 26 publications made it through the eligibility and inclusion criteria screening process (Figure 1). 78 of the 547 COVID-19 patients that included in this investigation supplied information regarding the start of cutaneous symptoms. On average, 9.92 ± 2.24 days passed following the onset of systemic symptoms such as fever, cough, dyspnea, diarrhea, and exhaustion before these lesions appeared. Thirty days was the most prolonged incubation period for the emergence of skin lesions. Patients with COVID-19 were discovered to have a wide range of skin complaints. The most frequent skin lesion was erythema which appeared on the face, flexural areas, trunk, extremities, and mucous membranes as presented in 44.18% of patients.

There were also vesicular lesions (13.02%), livedo/necrosis (6.11%), chilblain-like lesions (19.72%), urticaria-like lesions (16.37%), and petechiae (1.58%) among the other cutaneous signs. Remarkably, a considerable 44.77% of patients reported severe itching. Of the 547 patients, 431 had data regarding systemic symptoms; fever accounted for the most of these, occurring in 75.87% of cases. Cough (69.37%), asthenia or weariness (58.47%), dyspnea (46.64%), headache (30.39%), gastrointestinal problems (26.91%), and loss of taste or smell (22.27%) were among the other systemic symptoms. Table 1 shows details of all included studies.

Table 1 Characteristics of the studies included (n=26)

Study	Country	Cases with Cutaneous Involvement	Rash type	Rash location
(Ahouach et al., 2020)	France	1	Urticaria	Trunk
(Aghazadeh et al., 2020)	Iran	1	Oral vesicular eruption with erythematous plaques and papules in the face	Oral
(Alramthan and Aldaraji, 2020)	Qattar	2	Chilblain-like	Hands
(Amatore et al., 2020)	France	1	Urticaria	Upper limbs, chest, neck, abdomen
(Andina et al., 2020)	Spain	1	Chilblain-like	Acral
(Annunziata et al., 2020)	Italy	4	Macular, vesicular, vesicular, urticarial	Trunk, abdomen, trunk, legs
(Avellana-Moreno et al., 2020)	Spain	1	- Maculopapular	Generalized
(Bouaziz et al., 2020)	France	14	Four macular erythema, two vesicular, one cold urticaria, seven vascular	Trunks, upper
(Chaabane et al., 2021)	Tunisia	3	Erythema multiforme has a polymorphic pattern with a rash on the upper chest and livedo reticularis on the arm. It is also maculopapular.	-
(Dalal et al., 2020)	India	13	Maculopapular, urticaria	Trunk
(De-Masson et al., 2020)	France	7	Chilblain-like	Acral
(Droesch et al., 2020)	USA	4	Retiform purpura	Hands
(Fernandez-Nieto et al., 2020)	Spain	24	Vesicular	Trunk
(Fernandez-Nieto et al., 2020)	31 countries	135	Morbilliform, erythema, vesicular	
(Freeman et al., 2020a)	8 countries	14	Chilblain-like	Acral
(Freeman et al., 2020b)	Spain	234	-	-
(Galván-Casas et al., 2020)	Italy	3	Maculopapular	Trunk
(Hassan, 2020)	Scotland	1	Urticaria	Limbs
(Hedou et al., 2020)	France	5	Erythema	-
(Henry et al., 2020)	France	1	Urticaria	Generalized

(Hunt and Koziatek, 2020)	Usa	1	Maculopapular	Generalized
(Marzano et al., 2020)	Italy	22	Vesicular	Trunk
(Wu et al., 2020)	China	28	Conjunctivitis	Ocular
(Recalcati, 2020)	Italy	18	Erythema	-
(Young and Fernandez, 2020)	USA	2	Morbilliform	Trunk
(Zhang et al., 2020)	China	7	-	-

4. DISCUSSION

The most prevalent cutaneous symptom in COVID-19 individuals was erythematous maculopapular rash. Skin biopsies on only two of these individuals revealed that the skin abnormalities were the result from a medication reaction (Rosell-Díaz et al., 2020). However, the actual reason for the erythema in COVID-19 patients remains unknown. According to some research, herpes simplex virus (HSV) may be responsible for a subtype of erythema multiforme EM lesions (Aurelian et al., 2003). In addition, lymphocytes have been detected in COVID-19 individuals' skin lesions. These findings imply that the cutaneous rash could be induced by virus-specific T lymphocytes (Fernández-Lázaro and Garrosa, 2021).

Urticaria is another prevalent skin condition in COVID-19 patients who develop rashes. Previous study suggested that viral IgM and IgG may cross-react with mast cell IgE, resulting in mast cell degranulation and urticaria (Imbalzano et al., 2016). The prevalence of hives in COVID-19 varies widely, with frequencies ranging from 0.3% to 15.4% (Watashi et al., 2021). Most people with COVID-19 who develop hives have mild to moderate symptoms, and self-limited symptoms within several days. However, a tiny proportion of people may encounter severe symptoms or complications, such as anaphylaxis. The SARS-CoV-2 virus has induced chilblain-like lesions in particular people with COVID-19.

These lesions appear as red, swollen, and painful patches on the skin, usually on the toes or fingers, and may be accompanied by a burning or itching feeling. Blood clotting has been observed to be altered in COVID-19 patients, and, probably, reduced blood flow to the extremities (acro-ischemia) in severe COVID-19 cases is associated with an increased tendency for blood clotting (hypercoagulation) (Zhang et al., 2020). The specific reason for skin alterations in COVID-19 remains unknown. Some experts assume that these alterations are caused by the virus's direct effects on the skin, including reproduction and inflammation (Fernández-Lázaro and Garrosa, 2021). Others argue that skin alterations are indirectly related to the virus's immunological response, such as an autoimmune or hypersensitive reaction (Drago et al., 2021).

Skin alterations in COVID-19 may be the result from a mix of the virus's direct and indirect effects on the skin. Unfortunately, the precise causes of skin abnormalities in COVID-19 are merely speculations. It is worth noting that the prevalence of skin rashes among COVID-19 patients varies by country. In addition, it is important to note that skin rashes might appear in the general population as a previous studies showed that up to 1 % of individuals may get chronic hives at some point during their lives (Hon et al., 2019).

5. CONCLUSION

In conclusion, investigation of skin conditions related to COVID-19 may be critical for early detection and potentially improvement of the prognosis for patients with the condition. The current review provided a complete summary of the most common skin disorders related to COVID-19 and their potential underlying causes. More research is necessary to understand the connection between COVID-19 and skin problems and to develop evidence-based guidelines for managing these conditions. Future studies should include large, well- designed clinical trials to produce more reliable data on this topic.

Funding

This study has not received any external funding.

Conflict of interest

The authors declare that there is no conflict of interests.

Informed consent

Not applicable.

Ethical approval

Not applicable.

Data and materials availability

All data sets collected during this study are available upon reasonable request from the corresponding author.

REFERENCES

1. Aghazadeh N, Homayouni M, Sartori-Valinotti JC. Oral vesicles and acral erythema: report of a cutaneous manifestation of COVID-19. *Int J Dermatol* 2020; 59(9):1153-1154. doi: 10.1111/ijd.15047
2. Ahouach B, Harent S, Ullmer A, Martres P, Bégon E, Blum L, Tess O, Bachmeyer C. Cutaneous Lesions in a Patient with COVID-19: Are They Related? *Br J Dermatol* 2020; 183(2):e31. doi: 10.1111/bjd.19168
3. Alramthan A, Aldaraji W. Two cases of COVID-19 presenting with a clinical picture resembling chilblains: first report from the Middle East. *Clin Exp Dermatol* 2020; 45((6)):746-8. doi: 10.1111/ced.14243
4. Amatore F, Macagno N, Mailhe M, Demarez B, Gaudy-Marqueste C, Grob JJ, Raoult D, Brouqui P, Richard MA. SARS-CoV-2 infection presenting as a febrile rash. *J Eur Acad Dermatol Venereol* 2020; 34(7):e304-e306. doi: 10.1111/jdv.16528
5. Andina D, Noguera-Morel L, Bascuas-Arribas M, Gaitero-Tristán J, Alonso-Cadenas JA, Escalada-Pellitero S, Hernández-Martín Á, De-la-Torre-Espi M, Colmenero I, Torrelo A. Chilblains in children in the setting of COVID-19 pandemic. *Pediatr Dermatol* 2020; 37(3):406-411. doi: 10.1111/pde.14215
6. Annunziata MC, Patri A, Ruggiero A, Di-Guida A, Menicanti C, Greco V, Fabbrocini G. Cutaneous involvement during COVID-19 pandemic: an emerging sign of infection. *J Eur Acad Dermatol Venereol* 2020; 34(11):e680-e682. doi: 10.1111/jdv.16769
7. Aurelian L, Ono F, Burnett J. Herpes simplex virus (HSV)-associated erythema multiforme (HAEM): a viral disease with an autoimmune component. *Dermatol Online J* 2003; 9(1):1.
8. Avellana-Moreno R, Estela-Villa LM, Avellana-Moreno V, Estela-Villa C, Moreno-Aparicio MA, Avellana-Fontanella JA. Cutaneous manifestation of COVID-19 in images: a case report. *J Eur Acad Dermatol Venereol* 2020; 34(7):e307-e309. doi: 10.1111/jdv.16531
9. Bouaziz JD, Duong TA, Jachiet M, Velter C, Lestang P, Cassius C, Arsouze A, Domergue-Tham-Trong E, Bagot M, Begon E, Sulimovic L, Rybojad M. Vascular skin symptoms in COVID-19: a French observational study. *J Eur Acad Dermatol Venereol* 2020; 34(9):e451-e452. doi: 10.1111/jdv.16544
10. Bozzalla-Cassione E, Zanframundo G, Biglia A, Codullo V, Montecucco C, Cavagna L. COVID-19 infection in a northern-Italian cohort of systemic lupus erythematosus assessed by telemedicine. *Ann Rheum Dis* 2020; 79(10):1382-1383. doi: 10.1136/annrheumdis-2020-217717
11. Chaabane I, Loukil M, Amri R, Badri I, Baha H, Lajmi M, Bouzaidi K, Ghairi H. Cutaneous manifestations of COVID-19: report of three cases. *Arch Dermatol Res* 2021; 313(9):805-808. doi: 10.1007/s00403-020-02112-y
12. Dalal A, Jakhar D, Agarwal V, Beniwal R. Dermatological findings in SARS-CoV-2 positive patients: An observational study from North India. *Dermatol Ther* 2020; 33(6):e13849. doi: 10.1111/dth.13849
13. Dan JM, Mateus J, Kato Y, Hastie KM, Yu ED, Faliti CE, Grifoni A, Ramirez SI, Haupt S, Frazier A, Nakao C, Rayaprolu V, Rawlings SA, Peters B, Krammer F, Simon V, Saphire EO, Smith DM, Weiskopf D, Sette A, Crotty S. Immunological memory to SARS-CoV-2 assessed for up to 8 months after infection. *Sci* 2021; 371(6529):eabf4063. doi: 10.1126/science.abf4063
14. De-Masson A, Jean-David B, Sulimovic L, Cassius C, Jachiet M, Jachiet M, Marius-Anton I, Rybojad M, Bagot M. Chilblains Is a Common Cutaneous Finding during the COVID-19 Pandemic: A Retrospective Nationwide Study from France. *J Am Acad Dermatol* 2020; 83(2):667-70.
15. Drago F, Ciccarese G, Merlo G, Trave I, Javor S, Rebora A, Parodi A. Oral and cutaneous manifestations of viral and bacterial infections: Not only COVID-19 disease. *Clin Dermatol* 2021; 39(3):384-404. doi: 10.1016/j.clindermatol.2021.01.021

16. Drenovska K, Enno S, Snežina V. Covid-19 Pandemic and the Skin. *Int J Dermatol* 2020; 59(11):1312–19. doi: 10.1111/ijd.15189
17. Drosch C, Hoang M, DeSancho M, Lee E, Magro C, Harp J. Livedoid and Purpuric Skin Eruptions Associated With Coagulopathy in Severe COVID-19. *JAMA Dermatol* 2020; 156(9):1022–1024. doi: 10.1001/jamadermatol.2020.2800
18. Fernández-Lázaro D, Garrosa M. Identification, Mechanism, and Treatment of Skin Lesions in COVID-19: A Review. *Viruses* 2021; 13(10):1916. doi: 10.3390/v13101916
19. Fernandez-Nieto D, Ortega-Quijano D, Jimenez-Cauhe J, Burgos-Blasco P, De-Perosanz-Lobo D, Suarez-Valle A, Cortes-Cuevas JL, Carretero I, Garcia-Del Real C, Fernandez-Guarino M. Clinical and histological characterization of vesicular COVID-19 rashes: a prospective study in a tertiary care hospital. *Clin Exp Dermatol* 2020; 45(7):872–875. doi: 10.1111/ced.14277
20. Freeman EE, McMahon DE, Lipoff JB, Rosenbach M, Kovarik C, Takeshita J, French LE, Thiers BH, Hruza GJ, Fox LP; American Academy of Dermatology Ad Hoc Task Force on COVID-19. Pernio-like skin lesions associated with COVID-19: A case series of 318 patients from 8 countries. *J Am Acad Dermatol* 2020a; 83(2):486–492. doi: 10.1016/j.jaad.2020.05.109
21. Freeman EE, McMahon DE, Lipoff JB, Rosenbach M, Kovarik C, Desai SR, Harp J, Takeshita J, French LE, Lim HW, Thiers BH, Hruza GJ, Fox LP. The spectrum of COVID-19-associated dermatologic manifestations: An international registry of 716 patients from 31 countries. *J Am Acad Dermatol* 2020b; 83(4):1118–1129. doi: 10.1016/j.jaad.2020.06.1016
22. Galván-Casas C, Català A, Carretero-Hernández G, Rodríguez-Jiménez P, Fernández-Nieto D, Rodríguez-Villa Lario A, Navarro Fernández I, Ruiz-Villaverde R, Falkenhain-López D, Llamas Velasco M, García-Gavín J, Baniandrés O, González-Cruz C, Morillas-Lahuerta V, Cubiró X, Figueras Nart I, Selda-Enriquez G, Romaní J, Fustà-Novell X, Melian-Olivera A, Roncero Riesco M, Burgos-Blasco P, Sola Ortigosa J, Feito Rodriguez M, García-Doval I. Classification of the cutaneous manifestations of COVID-19: a rapid prospective nationwide consensus study in Spain with 375 cases. *Br J Dermatol* 2020; 183(1):71–77. doi: 10.1111/bjd.19163
23. Genovese G, Chiara M, Emilio B, Angelo VM. Skin Manifestations Associated with COVID-19: Current Knowledge and Future Perspectives. *Dermatology* 2021; 237(1):1–12. doi: 10.1159/000512932
24. Hassan K. Urticaria and Angioedema as a Prodromal Cutaneous Manifestation of SARS-CoV-2 (COVID-19) Infection. *BMJ Case Rep* 2020; 13(7):e236981. doi: 10.1136/bcr-2020-236981
25. Hedou M, Carsuzaa F, Chary E, Hainaut E, Cazenave-Roblot F, Masson Regnault M. Comment on 'Cutaneous manifestations in COVID-19: a first perspective' by Recalcati S. *J Eur Acad Dermatol Venereol* 2020; 34(7):e299–e300. doi: 10.1111/jdv.16519
26. Henry D, Ackerman M, Sancelme E, Finon A, Esteve E. Urticarial eruption in COVID-19 infection. *J Eur Acad Dermatol Venereol* 2020; 34(6):e244–e245. doi: 10.1111/jdv.16472
27. Hon KL, Leung AKC, Ng WGG, Loo SK. Chronic Urticaria: An Overview of Treatment and Recent Patents. *Recent Pat Inflamm Allergy Drug Discov* 2019; 13(1):27–37. doi: 10.2174/1872213X13666190328164931
28. Hunt M, Koziatsek C. A Case of COVID-19 Pneumonia in a Young Male with Full Body Rash as a Presenting Symptom. *Clin Pract Cases Emerg Med* 2020; 4(2):219–221. doi: 10.5811/cpcem.2020.3.47349
29. Imbalzano E, Casciaro M, Quartuccio S, Minciullo PL, Cascio A, Calapai G, Gangemi S. Association between urticaria and virus infections: A systematic review. *Allergy Asthma Proc* 2016; 37(1):18–22. doi: 10.2500/aap.2016.37.3915
30. Lubbe L, Cozier GE, Oosthuizen D, Acharya KR, Sturrock ED. ACE2 and ACE: Structure-Based Insights into Mechanism, Regulation and Receptor Recognition by SARS-CoV. *Clin Sci* 2020; 134(21):2851–71. doi: 10.1042/CS20200899
31. Marzano AV, Genovese G, Fabbrocini G, Pigatto P, Monfrecola G, Piraccini BM, Veraldi S, Rubegni P, Cusini M, Caputo V, Rongioletti F, Berti E, Calzavara-Pinton P. Varicella-like exanthem as a specific COVID-19-associated skin manifestation: Multicenter case series of 22 patients. *J Am Acad Dermatol* 2020; 83(1):280–285. doi: 10.1016/j.jaad.2020.04.044
32. Pollard CA, Morran MP, Nestor-Kalinoski AL. The COVID-19 pandemic: a global health crisis. *Physiol Genomics* 2020; 52(11):549–557. doi: 10.1152/physiolgenomics.00089.2020
33. Recalcati S. Cutaneous manifestations in COVID-19: a first perspective. *J Eur Acad Dermatol Venereol* 2020; 34(5):e212–e213. doi: 10.1111/jdv.1638
34. Rosell-Díaz AM, Mateos-Mayo A, Nieto-Benito LM, Balaguer-Franch I, Hernández-De-la-Torre-Ruiz E, Lainez-Nuez A, Suárez-Fernández R, Bergón-Sendín M. Exanthema and eosinophilia in COVID-19 patients: has viral infection a role in drug induced exanthemas? *J Eur Acad Dermatol Venereol* 2020; 34(10):e561–e563. doi: 10.1111/jdv.16709

35. Shukla AK, Banerjee M. Angiotensin-Converting-Enzyme 2 and Renin-Angiotensin System Inhibitors in COVID-19: An Update. *High Blood Press Cardiovasc Prev* 2021; 28(2):129-139. doi: 10.1007/s40292-021-00439-9
36. Tsai PH, Lai WY, Lin YY, Luo YH, Lin YT, Chen HK, Chen YM, Lai YC, Kuo LC, Chen SD, Chang KJ, Liu CH, Chang SC, Wang FD, Yang YP. Clinical manifestation and disease progression in COVID-19 infection. *J Chin Med Assoc* 2021; 84(1):3-8. doi: 10.1097/JCMA.0000000000000463
37. Watashi DM, Sene DR, Garófalo JB, Merlini RH, Merlini AB. Acute Urticaria as the First Symptom of COVID-19: A Case Report. *Cureus* 2021; 13(12):e20806. doi: 10.7759/cureus.20806
38. Wollina U, Karadağ AS, Rowland-Payne C, Chiriac A, Lotti T. Cutaneous signs in COVID-19 patients: A review. *Dermatol Ther* 2020; 33(5):e13549. doi: 10.1111/dth.13549
39. Wu P, Duan F, Luo C, Liu Q, Qu X, Liang L, Wu K. Characteristics of Ocular Findings of Patients With Coronavirus Disease 2019 (COVID-19) in Hubei Province, China. *JAMA Ophthalmol* 2020; 138(5):575-578. doi: 10.1001/jamaophthalmol.2020.1291
40. Young S, Fernandez AP. Skin manifestations of COVID-19. *Cleve Clin J Med* 2020. doi: 10.3949/ccjm.87a.ccc031
41. Zhang Y, Cao W, Xiao M, Li YJ, Yang Y, Zhao J, Zhou X, Jiang W, Zhao YQ, Zhang SY, Li TS. [Clinical and coagulation characteristics of 7 patients with critical COVID-2019 pneumonia and acro-ischemia]. *Zhonghua Xue Ye Xue Za Zhi* 2020; 41(0):E006. Chinese. doi: 10.3760/cma.j.issn.0253-2727.2020.0006