

Medical Science

To Cite:

Rahimi SN, Nordin NS. Reviving smiles: Periodontal care for a diabetic geriatric patient with tooth surface loss. *Medical Science* 2024; 28: e97ms3397

doi: <https://doi.org/10.54905/dissci.v28i150.e97ms3397>

Authors' Affiliation:

¹Department of Conservative Dentistry and Prosthodontics, Universiti Sains Islam Malaysia, 55100, Kuala Lumpur, Malaysia

²Periodontics Unit, School of Dental Sciences, Universiti Sains Malaysia, 16150, Kubang Kerian, Kelantan, Malaysia

*Corresponding Author

Periodontics Unit, School of Dental Sciences, Universiti Sains Malaysia, 16150, Kubang Kerian, Kelantan, Malaysia

Email: nusaibahsakinah@usm.my

Peer-Review History

Received: 09 May 2024

Reviewed & Revised: 13/May/2024 to 29/July/2024

Accepted: 02 August 2024

Published: 09 August 2024

Peer-review Method

External peer-review was done through double-blind method.

Medical Science

pISSN 2321-7359; eISSN 2321-7367



© The Author(s) 2024. Open Access. This article is licensed under a [Creative Commons Attribution License 4.0 \(CC BY 4.0\)](https://creativecommons.org/licenses/by/4.0/), which permits use, sharing, adaptation, distribution and reproduction in any medium or format, as long as you give appropriate credit to the original author(s) and the source, provide a link to the Creative Commons license, and indicate if changes were made. To view a copy of this license, visit <http://creativecommons.org/licenses/by/4.0/>.

Reviving smiles: Periodontal care for a diabetic geriatric patient with tooth surface loss

Siti Nadia Rahimi¹, Nusaibah Sakinah Nordin^{2*}

ABSTRACT

A compromised medical condition may affect the progression of periodontal disease due to the strong association between oral and systemic health. Uncontrolled diabetes can result in significant periodontal damage, potentially leading to severe complications such as tooth loss. This case report highlights the management of an elderly patient diagnosed with 'Generalised Periodontitis Stage IV Grade C,' complicated by uncontrolled Type 2 Diabetes Mellitus (T2DM), partial edentulous arches, reduced vertical dimension, and tooth surface loss. A comprehensive approach was employed, emphasising the interplay between periodontal health and systemic conditions, particularly diabetes. Initial management included debridement and the prescription of antibiotics, followed by extraction of hopeless teeth and the provision of an upper immediate overdenture. Non-surgical periodontal therapy was conducted alongside restorative and prosthodontic treatments. The patient's HbA1c levels improved from 8.5% to 7.0% over three months, demonstrating the positive impact of periodontal therapy on glycemic control. A multidisciplinary treatment plan was formulated, addressing defective restorations and constructing provisional and definitive prostheses. Emphasis was placed on maintaining excellent oral hygiene, which was reinforced during follow-ups. This case underscores the importance of integrated dental care in managing complex cases, particularly in elderly patients with multiple comorbidities, to enhance overall quality of life. Comprehensive dental management, meticulous periodontal care, and collaboration among specialists were crucial in restoring the patient's oral health and function, highlighting the bidirectional relationship between periodontal disease and diabetes management. This approach ensures long-term treatment success and improved oral health-related quality of life (OHRQoL) for the patient.

Keywords: Periodontitis, Diabetes, Tooth surface loss, Geriatric, Shortened Dental Arch

1. INTRODUCTION

A compromised medical condition can significantly alter the progression of periodontal disease due to the close association between oral and systemic health (Grusovin, 2019). Elderly patients often present with multiple chronic illnesses, with Type 2 Diabetes Mellitus (T2DM) being a common one. T2DM, formerly known as non-insulin-dependent diabetes, results from the body's ineffective use of insulin. Uncontrolled diabetes leads to advanced periodontal destruction, with tooth loss as one of the severe complications. Tooth loss can result in occlusal disharmony, interfering with the patient's appearance's functional and aesthetic aspects. A systematic review and meta-analysis conducted in 2010 found strong evidence linking tooth loss with the deterioration of oral health-related quality of life (OHRQoL) Gerritsen et al., (2010), such as impairment in the masticatory process. This case report discusses the management of an elderly patient diagnosed with 'Generalised Periodontitis Stage IV Grade C,' complicated by uncontrolled Type 2 Diabetes Mellitus, partial edentulous arches with reduced vertical dimension, and tooth surface loss.

2. CASE REPORT

History taking and clinical presentation

A 69-year-old lady came to the Universiti Teknologi MARA Dental Clinic complaining of mobile lower front teeth with swelling at the gum. Medically, she had been diagnosed with multiple comorbidities such as ischaemic heart disease, hypertension, T2DM, hyperlipidemia, and chronic kidney disease. She was compliant with regular medical follow-up. The latest Haemoglobin A1c (HbA1c) result was one month before the visit to the periodontal clinic, with a reading of 8.5%. Intra-oral examination revealed multiple periodontal abscesses at the mesiobuccal of 12, labial of 11, mesiolabial of 31, labial of 43, and 44 (Figure 1). All remaining lower dentition were severely attrited. Intraoral periapical radiographs revealed that tooth 11 has periapical radiolucency, while tooth 31 has vertical bone loss up to the apical region (Figure 2). A comprehensive periodontal charting is recorded as shown in (Figure 3).

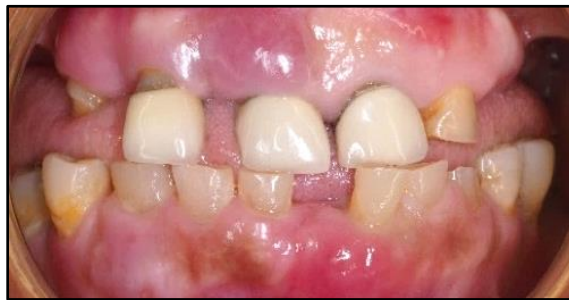

Figure 1 Baseline intra-oral photograph (anterior view) depicting periodontal abscess on 12, 11, 31, and 43, multiple missing teeth, and severe tooth wear on the remaining dentition.

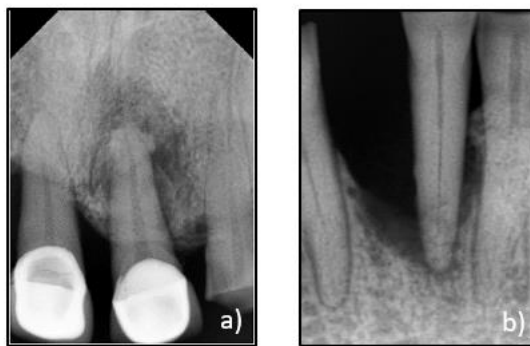


Figure 2 Baseline intra-oral periapical radiograph. a) Radiolucency noted at periapical of 11 & vertical bone loss at mesial of 12 up to $\frac{1}{2}$ of root length. b) Vertical bone loss up to the apex at the mesial of 31.

Diagnosis and treatment plan

After a thorough clinical examination and investigations, diagnoses were established. Periodontally, she was diagnosed with Generalised Periodontitis Stage IV Grade C, currently unstable, with uncontrolled T2DM as the modifying factor. She also had periodontal abscesses on 12, 11, 31, 43, and 44. Prosthodontic diagnoses include defective fixed dental prostheses from 12 to 21, partial edentulism with missing teeth from 18 to 14, 24 to 27, 38 to 36, and 46 to 48, and localized tooth surface loss on mandibular teeth associated with attrition. Endodontically, pulp necrosis was diagnosed for 23 & 31. A multidisciplinary treatment plan was constructed.

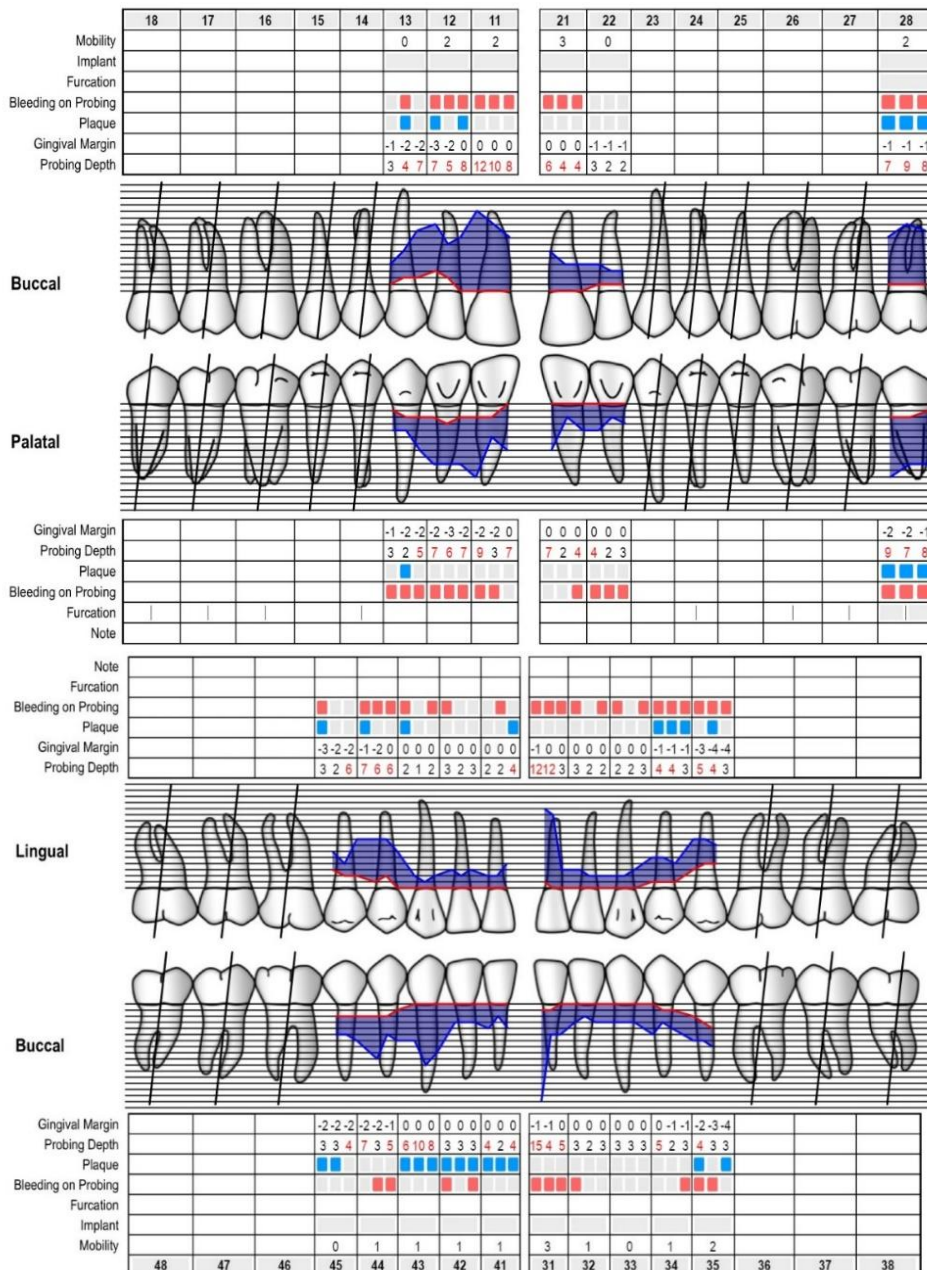


Figure 3 Baseline periodontal charting. (Periodontal charting form was adapted from perio-tools.com.)

As part of emergency intervention, localized debridement is performed on teeth with periodontal abscesses (12, 11, 31, 43, and 44). Initial phase therapy includes extraction of 12, 11, 21, 23, and 31, followed by the issuance of an upper immediate complete overdenture. Full mouth scaling and root planning are performed under local anaesthesia for probing pocket depths of 5 mm and

more. In the corrective phase, elective endodontics are performed on 13 and 22. A thorough restorative and prosthodontic assessment was conducted with a mounted study cast and diagnostic wax-up. Restorative procedures include addressing the defective amalgam restoration on tooth 45 with composite resin and performing composite build-ups on mandibular anterior teeth to correct attrition according to the new vertical dimension.

The provisional prosthodontics were provided with partial coverage restorations, a fixed-fixed bridge on 32 to 41, and a maxillary immediate acrylic denture as an interim solution. The phase was completed with the construction and cementation of fixed dental prostheses, including metal copings on teeth 13 and 22, and a lithium disilicate fixed dental prosthesis from tooth 45 to tooth 34 at the increased vertical dimension, as well as the construction and delivery of a maxillary cobalt-chromium (Co-Cr) complete denture. Reassessment of periodontal condition was performed every three months, and she was placed under maintenance care after becoming periodontally stable.

Treatment progress

Debridement and pus drainage at 12, 11, 21, 23, and 31 were performed, and the prescription of Tab Augmentin 625 mg twice daily with Tab Metronidazole 400 mg three times daily for five days was given on her first visit. At another visit, extraction of hopeless teeth was performed, and upper immediate overdenture was prescribed. Non-surgical periodontal therapy was performed concurrently with restorative and prosthodontic treatments, and reassessment of the patient's periodontal status was done after three months. During the first reassessment visit, the status of HbA1c one month before the visit was recorded as 7.0%.

Intra-oral examination revealed improved oral hygiene status based on the reduced plaque and bleeding on probing scores. No probing pocket depth of more than 4 mm was noted on the remaining teeth. However, due to the presence of temporary composite build-up of the remaining lower teeth (Figure 4), oral hygiene care was reinforced, emphasizing the interdental brush and superfloss to clean the interdental area. Non-surgical periodontal therapy was continued. The second reassessment visit was done after three months, and she could maintain good oral hygiene. At this stage, the patient has been wearing her upper overdenture and completed the fixed prosthesis for her lower teeth (Figure 5). As the patient could maintain her good oral hygiene, she was assigned supportive periodontal therapy for the maintenance of her periodontal status.

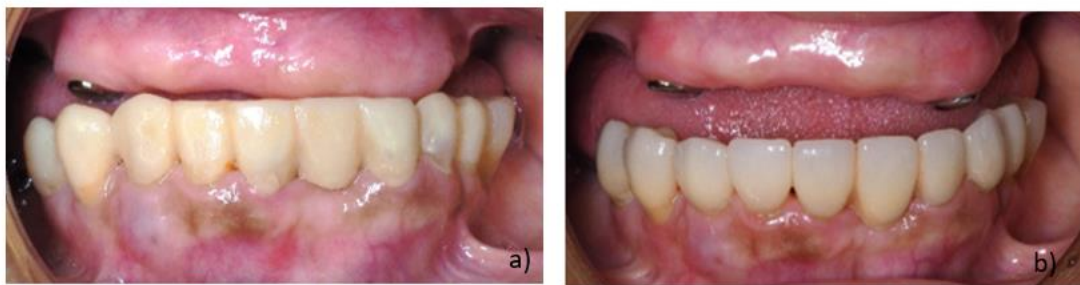


Figure 4 Comparison of the intra-oral clinical photograph at the first and second reassessments. a) All upper teeth are extracted except tooth 13 & 22 that were restored with metal coping for upper immediate overdenture. b) The remaining lower teeth were permanently restored with lithium disilicate fixed dental prosthesis at the newly established vertical dimension.

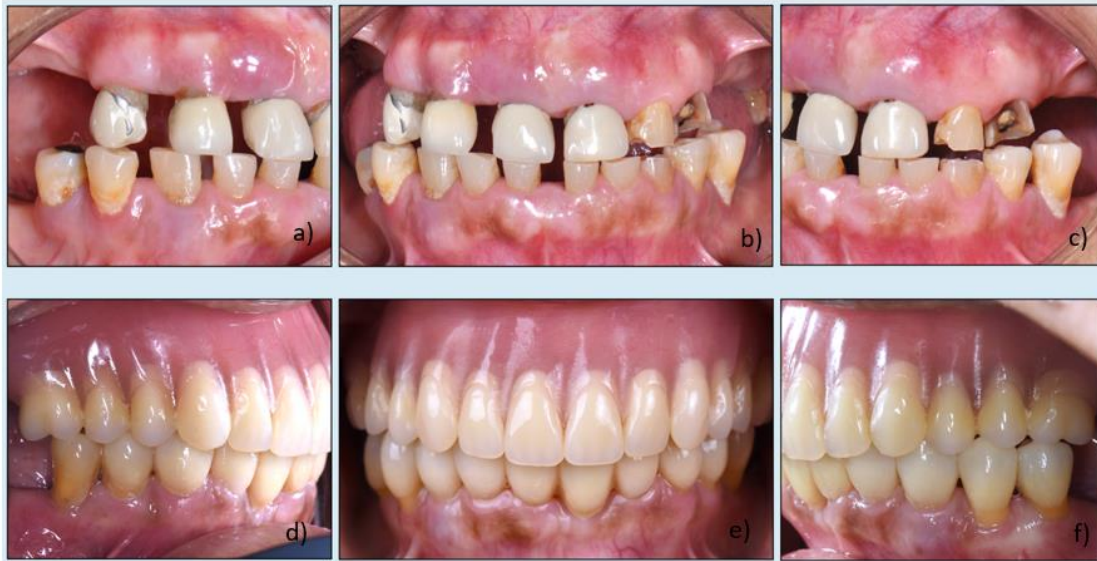

Figure 5 Comparison of intra-oral photographs during the baseline and supportive maintenance visit. a) right lateral view at the baseline. b) anterior view at the baseline. c) left lateral view at the baseline. d) right lateral view at the supportive periodontal visit. e) anterior view at the supportive periodontal visit. f) left lateral view at the supportive periodontal visit.

3. DISCUSSIONS

Periodontal therapy and hba1c levels

There is established evidence of the bidirectional relationship between periodontal disease and diabetes (Preshaw et al., 2012; Taylor, 2001). Studies have shown that treating periodontal disease may reduce HbA1c levels and vice versa (Altamash et al., 2016). A classic study of people from the Gila River Indian community reveals the relationship between severe periodontitis at baseline with an increased risk of poor glycemic control of more than 9% HbA1c levels at follow-up (Emrich et al., 1991). A study on German populations found that the elevated levels of periodontal disease and its progression are predictors of HbA1c progression over five years of follow-up (Demmer et al., 2010).

For this reason, periodontal treatment is expected to improve patients' blood glucose levels. A meta-analysis in 2010 reported a significant weighted mean reduction in HbA1c levels of 0.40% over three to nine months after periodontal treatment (Teeuw et al., 2010). Similarly, such improvement was depicted in the HbA1c levels of the patient from this case report, with her HbA1c levels measured around 7.0% three months after a round of non-surgical periodontal therapy with improved periodontal status.

The importance of optimum oral hygiene in a multidisciplinary case

The inter-relationship between the periodontist and prosthodontist or restorative specialist is crucial in managing periodontitis patients with prosthetic needs. The patient must achieve a high standard of oral hygiene so the prosthetic part of the treatment plan can be constructed. Plaque retentive factors such as caries and defective restorative margins should be addressed along with periodontal therapy. Any restorations not conducive to good oral hygiene should be removed, temporary replacements of hopeless teeth done, and temporary prosthetic planning is best done in collaboration with the prosthodontist (Erpenstein, 1986). In this patient's case, we performed non-surgical periodontal therapy and established good oral hygiene care by the patient. Simultaneously, the prosthetics were constructed to improve her oral health-related quality of life (OHRQoL).

Prosthesis and restorative therapy in periodontitis patients

Several factors need consideration if patients require prosthetics during periodontal therapy. The first is treatment planning. After proper assessment and diagnosis, the clinician should devise a treatment plan incorporating the prosthetic replacement for the dentition. Hence, multidisciplinary management is inevitable even early on. The second consideration is patient factors. Plaque control is crucial, especially in patients wearing prostheses, as it can become a risk factor in the progression of periodontal disease. Patient

compliance with oral hygiene instructions and dental visits plays a role in positively associating with periodontal health (Axelsson et al., 2004). In managing the present case, metal coping was provided on 13 and 22 as the definitive restorations on the overdenture abutments.

Therefore, plaque control in the area is crucial because the overdenture covers the root stumps. Neglect in the area may cause the progression of periodontal disease. Besides that, clinicians should also consider patients' functional and aesthetic needs. Some periodontitis patients may need teeth removal, which may impair their functional and aesthetic needs, as there is strong evidence of the association between tooth loss and deterioration of OHRQoL (Gerritsen et al., 2010). The decrease in occlusal support significantly accelerates tooth loss, primarily due to the excessive burden on the remaining teeth from bite forces (Fushida et al., 2021). Similarly, this abnormal pressure can cause the front teeth to move or splay outward, creating spaces, altering the bite, affecting chewing and, the aesthetic harmony of the smile.

Another consideration is the design of removable or fixed prostheses. In the case of fixed prostheses, the designs of the provisional crowns or bridge abutments should consider the crowns or abutments' emergence profile to prevent unfavourable overhangs that may contribute to plaque retention (Becker and Kaldahl, 2005). In this case report, we applied the Shortened Dental Arch (SDA) concept to the patient, which has proven sufficient to enhance her quality of life. The SDA approach suggests that maintaining anterior teeth and a few posterior occlusal pairs can provide adequate function for essential daily activities such as eating and speaking (Antunes et al., 2016; Witter et al., 2001). This strategy is particularly beneficial for elderly patients as it balances functionality with a less invasive treatment approach, simplifying dental care (Schierz et al., 2021).

4. CONCLUSIONS

In conclusion, this case highlights the critical importance of comprehensive dental management in elderly patients with uncontrolled T2DM by ensuring optimal HBA1c levels with proper restoration of periodontal health and occlusal support. Meticulous attention to periodontal care at this stage sets a solid foundation for the long-term success of the definitive prosthesis. Additionally, the provisional phase was rehabilitated at an increased vertical dimension to provide adequate posterior support for the patient's function. All fixed prostheses on the upper and lower arches were designed to have good margin adaptability to facilitate the patient's hygiene care. This is crucial to ensure the long-term prognosis of both periodontal health and overall treatment success.

Acknowledgment

We would like to thank our patient for allowing us to share her case and, we would also like to acknowledge the dental surgery assistants who have helped us with the management of this case.

Authors contribution

Siti Nadia Rahimi: Involved in the patient management and writing part of prosthodontic care in the manuscript.

Nusaibah Sakinah Nordin: Involved in the patient management and writing part of periodontal care in the manuscript.

Informed Consent

Written and oral informed consent was obtained from the patient who was involved in this report.

Funding

This study has not received any external funding.

Conflict of interest

The authors declare that there is no conflict of interests.

Data and materials availability

All data sets collected during this study are available upon reasonable request from the corresponding author.

REFERENCES

1. Altamash M, Klinge B, Engström PE. Periodontal Treatment and HbA1c Levels in Subjects with Diabetes Mellitus. *J Oral Rehabil* 2016; 43(1):31-38. doi: 10.1111/joor.12339
2. Antunes JLF, Tan H, Peres KG, Peres MA. Impact of Shortened Dental Arches on Oral Health-related Quality of Life. *J Oral Rehabil* 2016; 43(3):190–197. doi: 10.1111/JOOR.12364
3. Axelsson P, Nyström B, Lindhe J. The Long-term Effect of a Plaque Control Program on Tooth Mortality, Caries and Periodontal Disease in Adults: Results After 30 Years of Maintenance. *J Clin Periodontol* 2004; 31(9):749–757. doi: 10.1111/j.1600-051X.2004.00563.x
4. Becker C, Kaldahl W. Current Theories of Crown Contour, Margin Placement, and Pontic Design. *J Prosthet Dent* 2005; 93(2):107-15. doi: 10.1016/j.prosdent.2004.11.005
5. Demmer RT, Desvarieux M, Holtfreter B, Jacobs DR, Wallaschofki H, Nauck M, Volzke H, Kocher T. Periodontal Status and A1C Change: Longitudinal Results from the Study of Health in Pomerania (SHIP). *Diabetes Care* 2010; 33:1037–1043. doi: 10.2337/dc09-1778
6. Emrich LJ, Shlossman M, Genco RJ. Periodontal Disease in Non-Insulin-Dependent Diabetes Mellitus. *J Periodontol* 1991; 62(2):123–131. doi: 10.1902/jop.1991.62.2.123
7. Erpenstein H. The Role of the Prosthodontist in the Treatment of Periodontal Disease. *Int Dent J* 1986; 36(1):18-29.
8. Fushida S, Kosaka T, Kida M, Kokubo Y, Watanabe M, Higashiyama A, Miyamoto Y, Ono T, Ikebe K. Decrease in Posterior Occlusal Support Area can Accelerate Tooth Loss: The Suita Study. *J Prosthodont Res* 2021; 65(3):321–326. doi: 10.2186/JPR.JPR_D_20_00005
9. Gerritsen AE, Allen F, Witter DJ, Bronkhorst EM, Creugers NH. Tooth Loss and Oral Health-related Quality of Life: A Systematic Review and Meta-analysis. *Health Qual Life Outcomes* 2010; 8:126. doi: 10.1186/1477-7525-8-126
10. Grusovin MG. Treatment of Periodontal Diseases in Elderly Patients. *Clin Dent Rev* 2019; 3(1):1-12. doi: 10.1007/s41894-019-0057-5
11. Preshaw PM, Alba AL, Herrera D, Jepsen S, Konstantinidis A, Makrilakis K, Taylor R. Periodontitis and Diabetes: A Two-way Relationship. *Diabetologia* 2012; 55(1):21–31. doi: 10.1007/s00125-011-2342-y
12. Schierz O, Reissmann DR, Rauch A, John MT, Marre B, Luthardt RG, Mundt T, Hannak W, Kohal R, Kern M, Nothdurft F, Hartmann S, Boning K, Boldt J, Stark H, Edelhoff D, Wostmann B, Wolfart S, Jahn F, Walter MH. Impact of Shortened Dental Arch on Oral Health-related Quality of Life. *J Evid Based Dent Pract* 2021; 21(4):101622. doi: 10.1016/J.JEB DP.2021.101622
13. Taylor D. Bidirectional Interrelationships between Diabetes and Periodontal Diseases: An Epidemiologic Perspective. *Ann Periodontol* 2001; 6:99–112. doi: 10.1902/annals.2001.6.1.99
14. Teeuw WJ, Gerdes VEA, Loos BG. Effect of Periodontal Treatment on Glycemic Control of Diabetic Patients: A Systematic Review and Meta-analysis. *Diabetes Care* 2010; 33(2):421–427. doi: 10.2337/dc09-1378
15. Witter DJ, Creugers NHJ, Kreulen CM, De-Haan AF. Occlusal Stability in Shortened Dental Arches. *J Dent Res* 2001; 80(2):432–436. doi: 10.1177/00220345010800020601