

Medical Science

To Cite:

Elgeyoushy F, Aljezeri AY, Qari AS, Albouq SG. A rare case report of Angiosarcoma of Gallbladder in adult. *Medical Science* 2024; 28: e30ms3323
doi: <https://doi.org/10.54905/dissii.v28i146.e30ms3323>

Authors' Affiliation:

¹Consultant of General Surgery, Department of General Surgery King Fahad Hospital, Medina, KSA
²General Surgery Resident, Department of General Surgery in King Fahad Hospital, Medina, KSA
³Medical Intern, King Fahad Hospital, Taibah University, Medina, KSA

*Corresponding Author

Medical Intern, King Fahad Hospital, Taibah University, Medina, KSA
Email: amalqari123@gmail.com

Contact List

Fathi Elgeyoushy	felgeyoushy@gmail.com
Abdulaziz Yousef Aljezeri	azzo.azooz@hotmail.com
Amal Sayfuldeen Qari	amalqari123@gmail.com
Shireen Ghazi Albouq	Shireen.albouq@gmail.com

ORCID List

Fathi Elgeyoushy	0009-0002-4145-6314
Abdulaziz Yousef Aljezeri	0009-0007-6306-0990
Amal Sayfuldeen Qari	0009-0008-4347-1175
Shireen Ghazi Albouq	0000-0002-6766-7884

Peer-Review History

Received: 19 January 2024
Reviewed & Revised: 23/January/2024 to 12/April/2024
Accepted: 15 April 2024
Published: 18 April 2024

Peer-review Method

External peer-review was done through double-blind method.

Medical Science

pISSN 2321-7359; eISSN 2321-7367



© The Author(s) 2024. Open Access. This article is licensed under a [Creative Commons Attribution License 4.0 \(CC BY 4.0\)](https://creativecommons.org/licenses/by/4.0/), which permits use, sharing, adaptation, distribution and reproduction in any medium or format, as long as you give appropriate credit to the original author(s) and the source, provide a link to the Creative Commons license, and indicate if changes were made. To view a copy of this license, visit <http://creativecommons.org/licenses/by/4.0/>.

A rare case report of Angiosarcoma of Gallbladder in adult

Fathi Elgeyoushy¹, Abdulaziz Yousef Aljezeri², Amal Sayfuldeen Qari^{3*}, Shireen Ghazi Albouq²

ABSTRACT

Gallbladder cancer accounts for 80–95% of biliary system malignancies, even though it is the fifth most frequent gastrointestinal tract cancer and the most common biliary tract malignancy. A delayed diagnosis allows this cancer to spread silently. Consequently, prompt diagnosis is essential. American Indians have an abnormally high incidence, Southeast Asians have an elevated incidence, and the prevalence is relatively low in other parts of the Americas and the world. Environmental triggers, such as cholelithiasis, chronic inflammation from the biliary tract, and parasite infections, are essential factors in gallbladder cancer's growth. Over the past ten years, advances in radical, aggressive surgery and imaging methods have produced better results and extended survival times for gallbladder cancer patients. We report an unusual case of a 74-year-old female patient who had a lap cholecystectomy and was admitted from the outpatient clinic due to a severely inflamed gallbladder. An ultrasound shows that the gallbladder has many stones. Gallbladder cancer patients who received R0 curative resection had an overall survival rate over five years of 21% to 69%. One of the uncommon forms of gallbladder cancer that our patients have is sarcoma, a cancer that affects connective tissues, which includes blood vessels, muscles, and nerves. The rarity of gallbladder sarcoma is shown in this case. Sadly, it is difficult to diagnose this cancer early, and in most cases that have been documented, the tumor was discovered to be progressed when it was discovered.

Keywords: Angiosarcoma, Cancer, Gallbladder Carcinoma, gallbladder

1. INTRODUCTION

Gallbladder cancer accounts for 80-95% of cancers of the biliary system globally, making it the most frequent cancer of the biliary system. Among gastrointestinal malignancies, it is sixth. However, there is notable variation in the worldwide incidence of gallbladder cancer, with specific areas and racial groups experiencing epidemic proportions. Variations in exposure to the environment and innate hereditary predisposition to cancer most likely cause this variation.

Those danger indicators differ between ethnic groups and geographically. Gallbladder cancer often proceeds from metaplasia to dysplasia, carcinoma in situ, and finally, invasive disease throughout 5 to 15 years. A poor prognosis is usually indicated by rapid and silent progression. Early diagnosis and surgical resection are essential for a favorable result. Fewer than 10% of patients have tumors that are respectable at the time of surgery, despite this possibility for recovery, and over 50% had lymph node metastases.

Most patients develop metastatic illness even after surgery, underscoring the significance of developing adjuvant treatments (Hundal and Shaffer, 2014). Variations in environmental exposure and innate genetic susceptibility to carcinogenesis likely cause this variation. Gallbladder cancer risk factors include congenital biliary cysts, gallstone disease, porcelain gallbladder, gallbladder polyps, chronic Salmonella infection, and aberrant pancreaticobiliary duct junction. These disorders are linked to chronic inflammation. 0.5–1.5% of patients who undergo a straightforward cholecystectomy for suspected gallbladder stone illness go on to receive a gallbladder cancer diagnosis. Gallbladder cancer often proceeds from metaplasia to dysplasia, carcinoma in situ, and finally, invasive disease between five and fifteen years from now (Rakić et al., 2014).

2. CASE PRESENTATION

A 74-year-old female with a known case of diabetes mellites (DM) type 2 and post-per cholecystectomy tube before eight weeks due to severe inflamed Gallbladder was admitted from the outpatient clinic for lap cholecystectomy due to acute epigastric pain associated with nausea and vomiting. She had no prior exposure to arsenic chemicals, vinyl chloride, or thoracoplasty. Physical examination showed tenderness in the right upper quadrant and a positive murphy sign; a cholecystectomy was performed on her.

laboratory findings before surgery: White blood cells (WBCs): 4.5, hemoglobin (HGB):15, Platelet: 244

laboratory findings after surgery: WBC: 17, HGB: 12, Platelet: 282

Ultrasound is shown in (Figure 1 and 2). Gallbladder demonstrates multiple stones in the dependent portion with acoustic shadowing, and there is a tube seen at the fundus of the Gallbladder with the mild pericholecystic fluid collection, common bile duct (CBD) patient (1 mm).

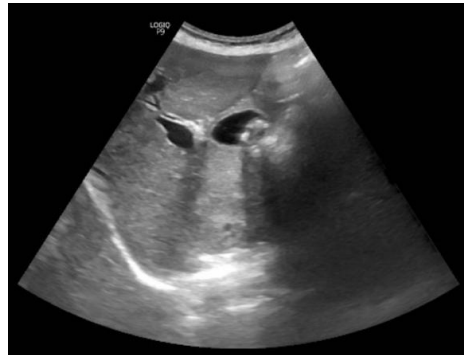

Figure 1 Abdominal ultrasound showed multiple stones.

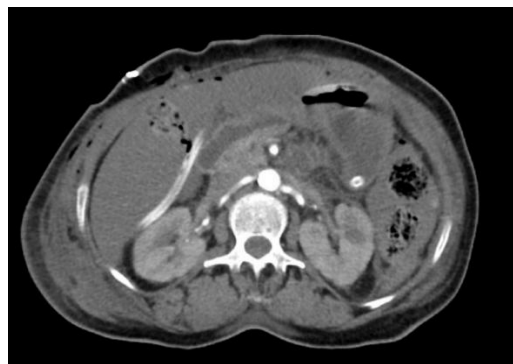


Figure 2 Abdominal CT without showed a diffuse colonic edematous wall with a decreased enhancement, not suggesting post-operative changes/ischemia.

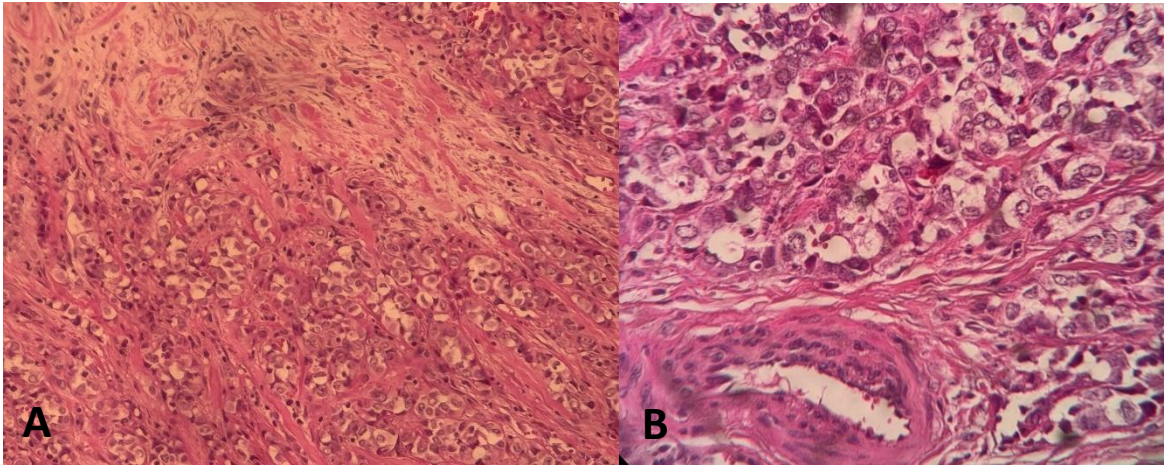


Figure 3 A: Show Specimen from the gallbladder tumor. angiosarcoma with an epithelioid pattern revealing sheets of cuboidal, pleomorphic cells with perineural invasion. B: A smaller component of the tumor consists of irregular vascular spaces lined by focal glandular epithelial reactive atypia.

Histological examination of the Gallbladder showed (Figure 3)

Tumor type: Angiosarcoma.

Tumor size: 4x3 cm, located at the fundus.

Cystic duct margin is clear.

Perineural invasion is noted.

Lymph vascular invasion is identified.

Focal glandular epithelial reactive atypia.

Background of Gallbladder with chronic cholecystitis and ulceration.

Cholelithiasis

Day one postoperative

The patient was having severe abdominal pain with vomiting multiple times. Abdomen soft and lax, drain 200 ml bloody, blood pressure: 89 /56 pulse: 120, respiratory rate: 20, oxygen saturation: 95%.

The rapid response team activated due to decreased loss of consciousness.

The patient was arrested, cardiopulmonary resuscitation (CPR) was done for 4 min, and the patient was revived.

The patient was shifted to the operative room (OR) for exploratory laparotomy via Kocher incision; there was a substantial mesenteric hematoma of the transverse colon but no bleeding from the liver bed.

Right hemicolectomy was done with ileotransverse anastomosis.

The patient was shifted to the Intensive care unit (ICU) and given one unit of packed red blood cells (PRBC), three units of platelets, and three units of fresh frozen plasma (FFP).

They were intubated on mechanical ventilation.

Histopathology of the colon

Ischemic bowel Disease of mesenteric vascular occlusive

Her abdominal computed tomography

Diffuse colonic edematous wall with a decreased enhancement, suggesting postoperative changes/ischemia.

Mild intraluminal hyperdense leveling at the descending colon's dependent portion and splenic flexure suggests intra-luminal hematoma with no contrast extravasation at the current computed tomography (CT) scan (Figure 2).

Multifocal peripheral hepatic hypodensity suggesting postoperative contusion/hepatic infarction.

The patient had a cardiac arrest. CPR was done for 9 min.

Cardiac arrest again; CPR was done for 6 min.

Cardiac arrest for the third time for 10 min, then declared death.

The patient expired two days post-surgery due to hypovolemic shock.

3. DISCUSSION

The precise incidence of gastrointestinal tract angiosarcomas is still unknown due to their rarity. Mainly, angiosarcomas of the Gallbladder have only been reported four times in the literature, leaving knowledge regarding their genesis, clinical manifestation, development, and mode of treatment lacking. The frequent association of gallbladder tumors with cholelithiasis has led to the suggestion that the condition may play a role in the etiology of gallbladder tumors in general. For example, Vaittinen observed that 79% of gallbladder sarcomas had cholelithiasis. Gallbladder angiosarcoma symptoms mimic those of carcinomas. However, they last less time because the tumor is said to progress considerably faster (Costantini et al., 2005). The World Health Organization classifies sarcomas into more than 50 histologic subtypes: Soft tissue and bone tumors.

The patients showed a palpable abdominal mass and right hypochondrial abdominal pain, which suggested they had acute cholecystitis. Their Gallbladder was histologically verified after varying in duration from three to eight weeks of abdominal pain (Odashiro et al., 2005). When patients report significant stomach symptoms and greater tumor size, carcinosarcoma of the gall bladder should be taken into consideration as a differential diagnosis of gall bladder neoplasms. The prognosis may be improved by race, tumor size, genetic diversity, earlier discovery, and more comprehensive surgery. Gallstones, epithelial and mesenchymal components, age, and sex have minimal predictive significance (Shi et al., 2020). Only a histopathologic test may definitively diagnose angiosarcoma; other conventional instrumental examinations, such as CT scans, ultrasounds, or X-rays, can only, at most, raise a suspicion of a tumoral mass.

According to recent research, positron emission CT scanning can help distinguish between benign and malignant diseases when radiopharmaceutical agents enhance the disease's pathophysiology identification and characterization. Fusing positron emission CT-acquired pictures with magnetic resonance imaging (MRI) or CT scans has dramatically increased sarcoma diagnostic accuracy. The gold standard for diagnosis is still liver resection or biopsy histopathology. If the lesions are surgically resectable, histological analysis of the complete lesion is more trustworthy than a biopsy because necrotic tissues that are abundant, missing, or insufficient may not indicate the entire lesion. Preoperative liver biopsy is not advised for further reasons, including needle-tract insertion and problems (such as prolonged internal bleeding, bile leakage, and infection) (Costantini et al., 2005; Shi et al., 2020). There currently needs to be set therapy recommendations due to the minimal expertise.

Cholecystectomy with or without wedge resection, extended right hepatic resection, and regional lymph node dissection where necessary continue to be the preferred surgical procedure. The wisdom and efficacy of chemotherapy and radiation therapy following surgery are still unknown. After resection of locally extensive cancers that invade nearby organs or involve regional lymph nodes, we consider adjuvant therapy due to the significant risk of both systemic and regional recurrence in locally progressed tumors. However, no randomized trials have been conducted to measure the efficacy of such adjuvant therapy. In the absence of metastatic disease, retrospective studies have indicated that postoperative chemoradiotherapy improves survival in patients with high-risk tumors, i.e., tumors with extensive local infiltration outside the gall bladder wall or those with involvement of regional lymph nodes (Costantini et al., 2005; Botros et al., 2009).

Gallbladder angiosarcoma has a dismal prognosis, however, and its clinical appearance can be confused with acute cholecystitis. Accurate early diagnosis using pathological examination and imaging methods is crucial. As far as we know, this is the only instance of gallbladder angiosarcoma (Park et al., 2020). Research on gallbladder sarcoma is still being conducted to understand the condition better and discover potential new treatment options. Clinical trials testing immunotherapies and targeted medicines are now being conducted, which could lead to more successful treatments in the future. Furthermore, improvements in genetic profiling and imaging methods could improve individualized treatment plans and early detection.

4. CONCLUSION

Gallbladder sarcoma is a rare and aggressive form of cancer that arises from the cells of the Gallbladder. Its rapid progression and poor prognosis characterize it. Throughout this discussion, we have explored the key features, diagnostic methods, and treatment options for gallbladder sarcoma. Due to its rarity and aggressive nature, gallbladder sarcoma presents considerable difficulties for both patients and healthcare providers. Early disease detection is crucial, allowing for timely intervention and potentially improving patient outcomes. However, the diagnosis of gallbladder sarcoma remains challenging due to its nonspecific symptoms and the lack of specific diagnostic markers. Imaging studies, such as ultrasound, CT scans, and MRI, play a vital role in detecting gallbladder abnormalities, while biopsy and histopathological examination confirm the diagnosis.

Unfortunately, due to the aggressive nature of gallbladder sarcoma, the prognosis is often poor. Surgical intervention, including radical cholecystectomy, is the primary treatment option. However, complete surgical resection is often challenging due to the advanced stage at which most cases are diagnosed. Adjuvant therapies, such as chemotherapy and radiation therapy, may be considered to improve the chances of disease control and prolong survival, although their effectiveness in gallbladder sarcoma is still limited. In conclusion, gallbladder sarcoma is a rare and aggressive malignancy with a poor prognosis. Early detection, accurate diagnosis, and aggressive surgical intervention remain the mainstay of treatment. Collaboration between healthcare providers, researchers, and patients is essential to further our knowledge of gallbladder sarcoma and develop innovative therapeutic modalities to improve patient outcomes.

Author Contributions

Fathi Elgeyoushy, Abdulaziz Yousef Aljezeri, Amal Sayfuldeen Qari, and Shireen Ghazi Albouq participated in the protocol design, data collection, analysis, and writing the study. All authors reviewed and approved the final manuscript.

Informed Consent

Oral informed consent was obtained from participant included in the study. Additional informed consent was obtained from participant for whom identifying information is included in this manuscript.

Acknowledgment

We thank the participants who all contributed samples to the study.

Ethical approval

Not applicable.

Funding

This study has not received any external funding.

Conflict of interest

The authors declare that there is no conflict of interests.

Data and materials availability

All data sets collected during this study are available upon reasonable request from the corresponding author.

REFERENCES

1. Botros M, Quevedo JF, Miller R. Angiosarcoma of the liver after multimodality therapy for gallbladder carcinoma. *Radiat Oncol* 2009; 43(2):126–131. doi: 10.2478/v10019-009-0012-1
2. Costantini R, Di-Bartolomeo N, Francomano F, Angelucci D, Innocenti P. Epithelioid angiosarcoma of the gallbladder: case report. *J Gastrointest Surg* 2005; 9(6):822-5. doi: 10.1016/j.gassur.2005.01.286
3. Hundal R, Shaffer EA. Gallbladder cancer: epidemiology and outcome. *Clin Epidemiol* 2014; 6:99-109. doi: 10.2147/CLEP.S37357

4. Odashiro AN, Pereira PR, Mijji LNO, Nguyen G. Angiosarcoma of the gallbladder: Case report and literature review. *Can J Gastroenterol* 2005; 19(4):257-259. doi: 10.1155/2005/794869
5. Park G, Park WS, Lee SK, Kim JO. A rare collision tumor comprising intracystic papillary neoplasm associated with adenocarcinoma and angiosarcoma in the gallbladder. *Korean J Intern Med* 2020; 35(3):732-733. doi: 10.3904/kjim.2018.394
6. Rakić M, Patrlj L, Kopljar M, Kliček R, Kolovrat M, Loncar B, Basic Z. Gallbladder cancer. *Hepatobiliary Surg Nutr* 2014; 3(5):221-6. doi: 10.3978/j.issn.2304-3881.2014.09.03
7. Shi Y, Chen J, Chen H, Hong X. Sarcomatoid carcinoma of the gallbladder: a case report. *J Int Med Res* 2020; 48(6):300060520935283. doi: 10.1177/0300060520935283
8. Zeig DA, Memon MA, Kennedy DR, Suzette A, Fitzgibbons Jr RJ. Leiomyosarcoma of the Gallbladder: A Case Report and Review of the Literature. *Acta Oncol* 2009; 37(2):212–214. doi: 10.1080/028418698429810