

# MEDICAL SCIENCE

## To Cite:

Kaskova LF, Honcharenko VA, Kitsak TS. The state of the periodontal tissue in children with insulin dependent diabetes mellitus. *Medical Science* 2023; 27: e347ms3056  
doi: <https://doi.org/10.54905/disssi.v27i139.e347ms3056>

## Authors' Affiliation:

<sup>1</sup>Department of Pediatric Therapeutic Dentistry, Poltava State Medical University, Poltava, Ukraine

<sup>2</sup>Department of Pediatric Dentistry, Bukovinian State Medical University, Chernivtsi, Ukraine

## \*Corresponding author

Department of Pediatric Dentistry, Bukovinian State Medical University, Chernivtsi, Ukraine

Email: [honcharenko\\_valentyna@bsmu.edu.ua](mailto:honcharenko_valentyna@bsmu.edu.ua); [honcharenko1204@ukr.net](mailto:honcharenko1204@ukr.net)

## Contact List

Liudmyla F Kaskova	<a href="mailto:kaskova@ukr.net">kaskova@ukr.net</a>
Valentyna A Honcharenko	<a href="mailto:honcharenko_valentyna@bsmu.edu.ua">honcharenko_valentyna@bsmu.edu.ua</a> ; <a href="mailto:honcharenko1204@ukr.net">honcharenko1204@ukr.net</a>
Tetiana S Kitsak	<a href="mailto:kitsak_tetiana@bsmu.edu.ua">kitsak_tetiana@bsmu.edu.ua</a>

## ORCID List

Liudmyla F Kaskova	0000-0003-0855-2865
Valentyna A Honcharenko	0000-0001-7276-9052
Tetiana S Kitsak	0000-0003-1253-8919

## Peer-Review History

Received: 12 May 2023

Reviewed & Revised: 16/May/2023 to 08/September/2023

Accepted: 12 September 2023

Published: 15 September 2023

## Peer-review Method

External peer-review was done through double-blind method.

Medical Science

pISSN 2321-7359; eISSN 2321-7367



© The Author(s) 2023. Open Access. This article is licensed under a [Creative Commons Attribution License 4.0 \(CC BY 4.0\)](https://creativecommons.org/licenses/by/4.0/), which permits use, sharing, adaptation, distribution and reproduction in any medium or format, as long as you give appropriate credit to the original author(s) and the source, provide a link to the Creative Commons license, and indicate if changes were made. To view a copy of this license, visit <http://creativecommons.org/licenses/by/4.0/>.

# The state of the periodontal tissue in children with insulin dependent diabetes mellitus

Liudmyla F Kaskova<sup>1</sup>, Valentyna A Honcharenko<sup>2\*</sup>,  
Tetiana S Kitsak<sup>2</sup>

## ABSTRACT

The study aimed was to study the state of periodontal tissues in 18 somatically healthy children and 109 children with type 1 diabetes, taking into account the duration and severity of the underlying disease. The examination results showed that changes in periodontal tissues are more pronounced in children with somatic pathology than in children without concomitant pathology. We have established that with a duration of diabetes more than five years, the papillary-marginal index was probably higher than in children with a duration of diabetes less than five years. The dependence of periodontal tissues on the level of glycemic control was monitored. In children with an optimal level of glycemic control, a soft degree of chronic catarrhal gingivitis was found, suboptimal - mild and moderate, and in children with a high level of glycemic control, a soft, moderate and severe course of HCG was detected. The number of sextants with bleeding also depended on the duration and severity of the course main disease.

**Keywords:** Children, diabetes mellitus, periodontal tissue state, gingival bleeding, chronic catarrhal gingivitis.

## 1. INTRODUCTION

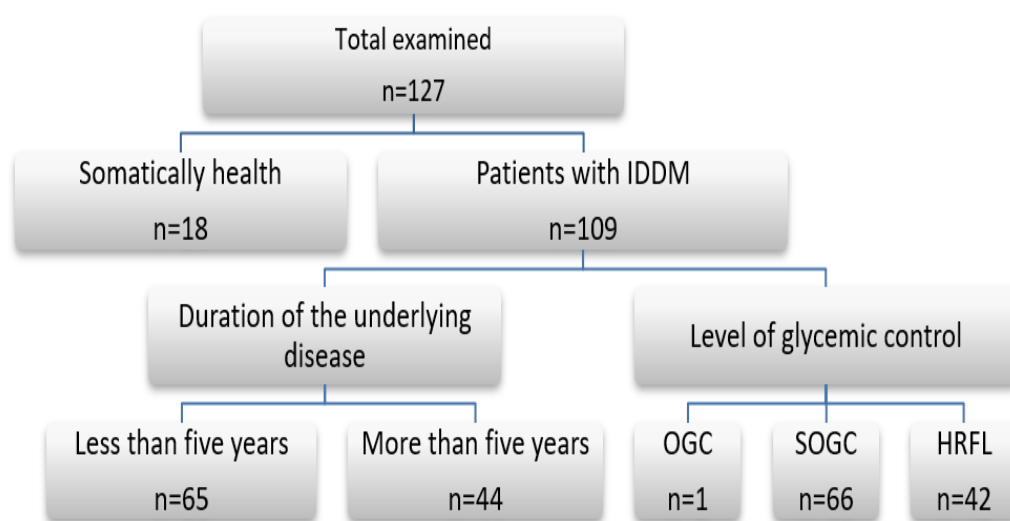
Dental diseases are quite common among children. Their number and intensity are increasing compared to other historical periods (Yanko et al., 2017; Kaskova et al., 2020; Sorochenko et al., 2016). Diseases of periodontal tissues are an actual problem of modern dentistry due to their widespread and progressive course. Local and general factors were differentiated in the etiology of periodontal tissue diseases. However, such a distribution is conventional since these diseases can be associated both with themselves and the child's body on the whole. Condition of somatic health plays a considerable role in the pathogenesis of periodontal tissue diseases (Khomenko et al., 2016; Kaskova et al., 2019).

The data from clinical and experimental studies indicate close relations between periodontal tissue diseases and functional disorders of the endocrine glands. Periodontal pathology is known to be one of the first manifestations of diabetes mellitus (DM) (Casavalle et al., 2016; Godovanets et al., 2020; Barrett et al., 2017). Changes in the periodontal tissue of children should put

pediatric dentists on guard with the aim of timely diagnostics, prevention, and treatment of both diabetes mellitus and diseases of periodontal tissues (Carneiro et al., 2015; Vynohradova et al., 2015; Zelinska et al., 2020). Therefore, our goal was to study the condition of periodontal tissues in children with insulin-dependent diabetes mellitus (IDDM) and compare it with the parameters of somatically healthy individuals' children.

## 2. MATERIALS AND METHODS

In the period from September 2022 to March 2023, we investigated the state of periodontal tissues in 18 children who did not have general diseases and 109 children with diabetes who were examined and treated in the endocrinology department of the Regional Clinical Hospital (Chernivtsi, Ukraine) regarding insulin-dependent diabetes mellitus: 65 children were ill up to five years, 44 – more than five years. Taking into account the level of glycemic control, one child had optimal glycemic control (OGC), 66 children had suboptimal glycemic control (SOGC), and 42 children had high risk for life (HRFL) (Picture 1).



**Picture 1** Scheme of dental examination of children of observation groups

The condition of the periodontal tissues in children was assessed by the PMA gingival index and the communal periodontal index SRI. The papillary-marginal-cellular index (PMA) in the Parma modification makes it possible to determine the initial changes in periodontal tissues - the degree and prevalence of inflammation in the gums. Procedure: using a mirror and a probe, the presence of an inflammatory process near each tooth was visually assessed.

Evaluation criteria:

- 1 point – Inflammation of the papilla;
- 2 points – Inflammation of the gingival margin;
- 3 points – Inflammation of the attached part of the gums.

Formula for calculation:  $PMA = (\text{sum of points}) / (3 \times \text{number of teeth}) \times 100\%$ .

Interpretation of the index:

- up to 25% - A mild degree of gingivitis;
- 25 - 50% - Average degree of gingivitis;
- more than 50% - A severe degree of gingivitis.

Communal periodontal index SRI considers the state of the following indicators of periodontal status: bleeding gums, calculus, and periodontal pockets. A specially developed light CPI probe with a ball at the end, 0.5 mm in diameter, is used. It has a black mark between 3.5 and 5.5 mm and a black ring at 8.5 mm and 11.5 mm from the probe tip. The oral cavity was divided into six sections, which included the following groups of teeth: 18-14, 13-23, 24-28, 38-34, 33-43, 44-48. In patients younger than 20, only six index teeth were examined - 16, 11, 26, 36, 31, 46, and only bleeding gums and tartar were recorded. The results of the study were evaluated according to the following criteria:

- 0 - There are no signs of damage;
- 1- Bleeding gums;

2- Calculus (The black zone of the probe is above the level of the gums);

3- Periodontal pocket with a depth of 4-5 mm (The gingival margin is located at the level of the probe's black mark);

4- Periodontal pocket with a depth of 6 mm or more (The black zone is not visible on the search).

In accordance with WHO recommendations, the gradation shown in Table 1 was used to assess the prevalence and intensity of bleeding and the presence of tartar in adolescents.

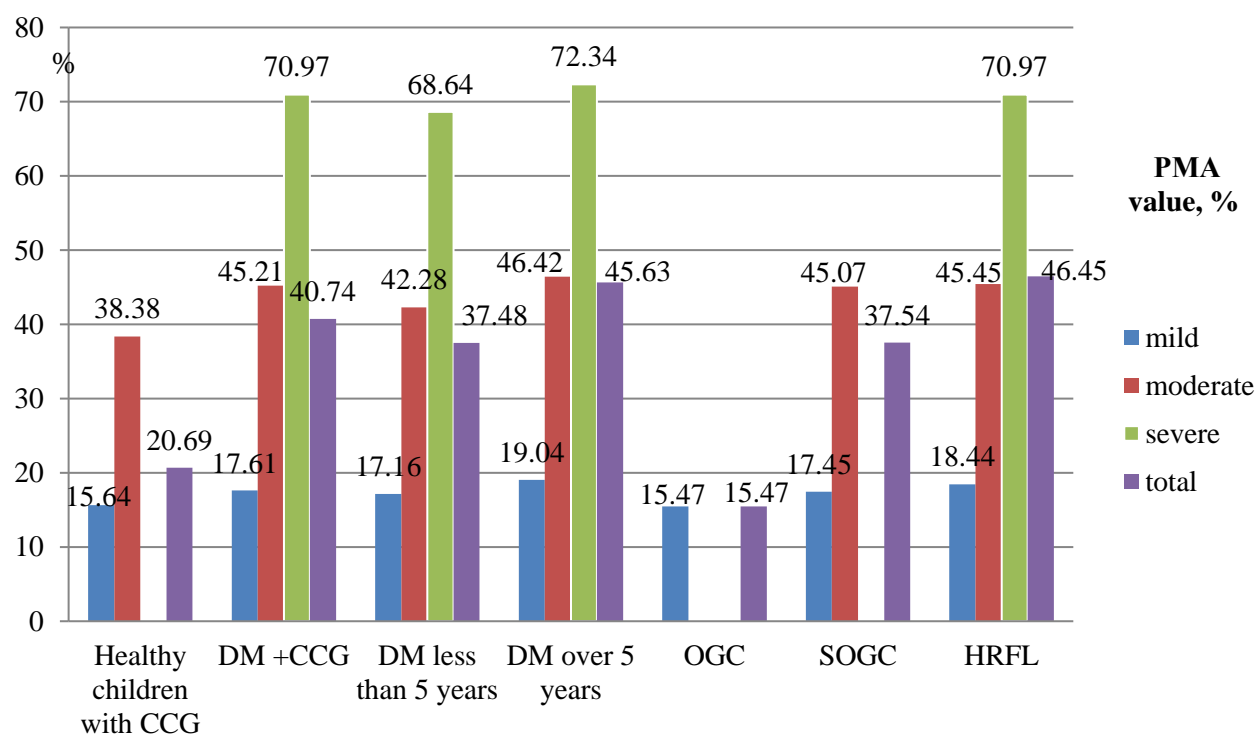
**Table 1** Prevalence and intensity of periodontal tissue diseases in adolescents according to WHO

Sign	Percentage of occurrences	The mean number of sextants
<i>Prevalence of bleeding</i>		
Low	up to 20%	up to 4, 0, 5
Average	21 - 50%	0, 6 - 1, 5
High	51 and above	1, 6 and above
<i>Prevalence of tartar</i>		
Low	up to 50%	up to 1, 5
Average	51 - 80%	1, 6 - 2, 5
High	81% and above	2, 6 and above

All research was conducted in compliance with the principles of bioethics. Examination of children was carried out taking into account the main provisions of the Helsinki Declaration on Biomedical Research. Statistical data processing was carried out by the method of variational statistics according to the student's criterion and using Statistica 7.0 software (StatSoft, Inc). The difference between the comparison groups was considered probable at  $p \leq 0.05$ .

### 3. RESULTS AND DISCUSSION

Determining the degree of severity of chronic catarrhal gingivitis indicates that children without somatic pathology did not have severe forms of its course (Picture 2). A mild degree prevailed among them (77.8%). In children with diabetes, the average degree of severity prevailed (76 patients out of 109, which is 69.72%), a severe course was found in 7.34% of children, and a mild one in 22.94% of cases.

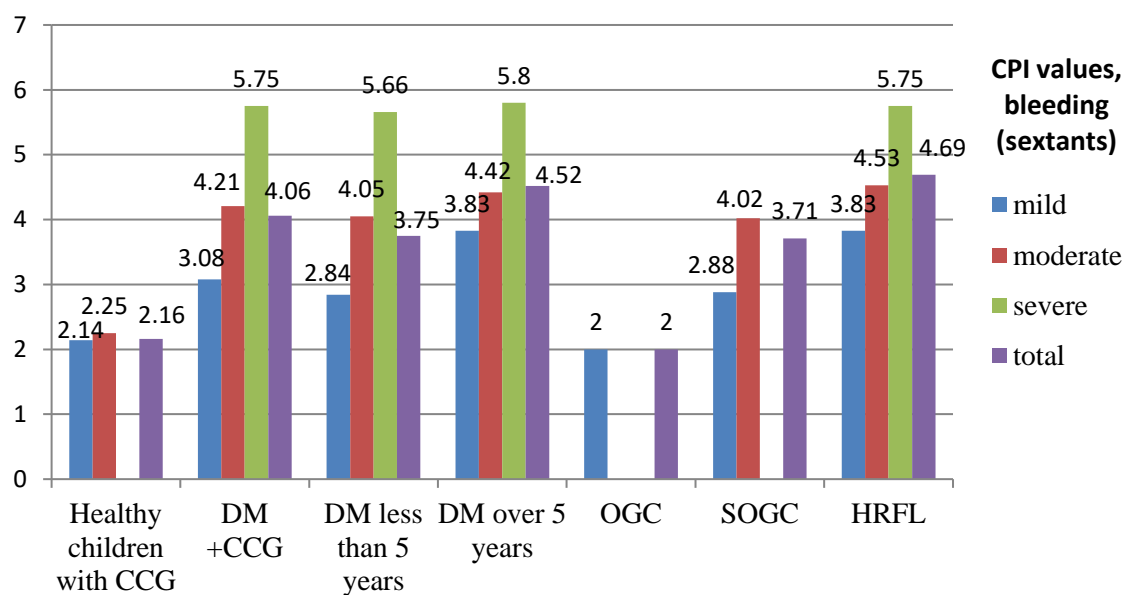


**Picture 2** PMA index of the children examined,  $M \pm m$

There was no significant difference in the RMA rate in somatically healthy children and children with diabetes with mild severity of gingivitis. Numerical values the papilla-marginal-alveolar index with a moderate intensity of the process in the periodontal tissue of children with IDDM differed reliably from those without the underlying disease ( $p<0.05$ ). A reliable difference in the parameter examined was found in the case of moderate and severe forms of chronic catarrhal gingivitis in children depending on the duration of diabetes mellitus. Children who suffer from DM for over five years present more considerable changes in the periodontal tissues. This is confirmed by the research of other authors (Casavalle et al., 2016; Godovanets et al., 2020; Vynohradova et al., 2015).

The state of the periodontal tissue in children with DM is associated with the level of their glycemic control. Patients with optimal levels of glycemic control presented a mild degree of chronic catarrhal gingivitis (CCG) only. Those with suboptimal levels – mild and moderate degrees, and children with the glycemic control level and a high risk for life – mild, moderate, and severe degrees. Thus, a severe degree was found in 8 children, estimated as 19.05%, and a mild degree – in 6 (14.29%). The presence of bleeding was studied taking into account the number of sextants in children of different groups and the degree of severity of inflammation of catarrhal gingivitis (Picture 3). Thus, in children suffering from IDDM, the number of sextants with bleeding appeared to be 1.88 times higher than that in children with chronic catarrhal gingivitis without underlying pathology. We observe an increase in the number of sextants with bleeding in children with diabetes compared to somatically healthy children.

The amount of sextants with bleeding depends on the severity and duration of the underlying disease. The indicator of probable difference was shown in children with optimal and suboptimal levels of glycemic control, regardless of the severity of gingivitis. That is, children with SOGC presented 1.85 times higher amounts of sextants with bleeding than children with OGC. We have a significant difference in the case of the optimal level of glycemic control and the level of glycemic control with a high risk for life ( $p<0.05$ ). This difference increases in patients with OGC and HRFL and reaches 2.35 times. A reliable difference in the parameter (sextants of bleeding) in children with SOGC and HRFL was not found ( $p>0.05$ ).



**Picture 3** CPI values of the children examined ( $M\pm m$ )

#### 4. CONCLUSIONS

The results of the examination indicate that in the presence of diabetes, periodontal tissue changes are more pronounced than in somatically healthy children. Thus, when diabetes mellitus lasts longer than five years with moderate and severe degrees of chronic catarrhal gingivitis, the papilla-marginal-alveolar index is reliably higher than that in children with a duration of the underlying diseases less than five years. The state of the periodontal tissue depends on the level of glycemic control. Patients with optimal levels of glycemic control presented a mild degree of chronic catarrhal gingivitis only, those with suboptimal levels – mild and moderate degrees, and children with the glycemic control level and a high risk for life – mild, moderate, and severe degrees. Thus, children with more severe manifestations of diabetes mellitus present more considerable pathological changes in the periodontal

tissue. The number of sextants with bleeding increased in children with IDDM compared to somatically healthy children. The amount of sextants with bleeding depends on the severity and duration of the underlying disease.

### Ethical approval

The research proposal was approved by the by the Medical Ethics Committee of Bukovynian State Medical University, Chernivtsy, Ukraine (registration number: 15.04.23/7).

### Authors' contribution

Research concept and design, literature review, examination of patients, elaboration and generalization of the results – Valentyna A Honcharenko; editing, preparation of materials for printing – Tetiana S Kitsak; provision of advisory assistance – Liudmyla F Kaskova.

### Informed consent

Not applicable.

### Funding

This study has not received any external funding.

### Conflict of interest

The authors declare that there is no conflict of interests.

### Data and materials availability

All data sets collected during this study are available upon reasonable request from the corresponding author.

## REFERENCES AND NOTES

- Barrett EJ, Liu Z, Khamaisi M, King GL, Klein R, Klein BEK, Hughes TM, Craft S, Freedman BI, Bowden DW, Vinik AI, Casellini CM. Diabetic Microvascular Disease: An Endocrine Society Scientific Statement. *J Clin Endocrinol Metab* 2017; 102(12):4343-4410. doi: 10.1210/jc.2017-01922
- Carneiro VL, Fraiz FC, Ferreira FM, Pintarelli TP, Oliveira AC, Boguszewski MC. The influence of glycemic control on the oral health of children and adolescents with diabetes mellitus type 1. *Arch Endocrinol Metab* 2015; 59(6):535-40. doi: 10.1590/2359-3997000000117
- Casavalle L, Fima L, Romano LS, Chaves MM, Bordonni N, Boyer PM, Rodriguez PN, Friedman SM. Gingivitis and insulin resistance in obese children. *Diabetes care* 2016; 39(12):e216-e217. doi: 10.2337/dc16-0708
- Godovanets OI, Kotelban AV, Moroz PV, Vitkovskyi OO, Kitsak TS, Navolskyi NM. Clinical and immunologic assessment of a complex of therapeutic-preventive measures concerning chronic catarrhal gingivitis in children with comorbid diabetes mellitus. *Wiad Lek* 2020; 73(2):298-301.
- Kaskova LF, Abramchuk II, Batih VM. Condition of periodontal tissues in adolescents studying in different educational institutions. *Suchasna stomatolohiia* 2020; 1:26-9. doi: 10.33295/1992-576X-2020-1-26
- Kaskova LF, Yanko NV, Vashchenko IYu. Gingival health in children in the different phases of acute lymphoblastic leukemia. *Curr Issues Pharm Med Sci* 2019; 32(3):134-137. doi: 10.2478/cipms-2019-0025
- Khomenko LO, Leus PA, Ostapko OI, Sorochenko GV. Determination of the significance of risk indicators at different levels of dental caries intensity in school-age children. *Visn social hygiene and health care organization of Ukraine* 2016; 2:39-45.
- Sorochenko HV, Skulska SV, Ishutko IF. European indicators of the dental health of school-age children of the Kyiv region. *Bulletin of social hygiene and health protection organization of Ukraine* 2016; 1:36.
- Vynohradova OM, Shkrebnik Rlu. Differentiation methods of treatment of periodontal tissue diseases with underlying diabetes mellitus. *Klinichna ta eksperimentalna patologiya* 2015; 1:205.
- Yanko NV, Artemyev AV, Kaskova LF. Frequent dental caries in children in the Early Iron Age and the Medieval populations from Ukraine. *Anthropol Rev* 2017; 80(4):415. doi: 10.1515/anre-2017-0030
- Zelinska NB, Hloba YeV, Rudenko NH, Rudenko OV, Steshenko Ie, Kavetska YuS. Pediatric endocrinology in Ukraine. Analysis of the indices of giving specialized medical aid to children in 2019. *Ukraine J Pediatr Endocrinol* 2020; 1:5. doi: 10.30978/UJPE2020-1-5.