

Mature teratoma of bilateral ovary: A case report

Naina Saluja^{1*}, Jayant S Makrande², Kishore Hiwale²,
Sunita Vagha³

To Cite:

Saluja N, Makrande JS, Hiwale K, Vagha S. Mature teratoma of bilateral ovary: A case report. *Medical Science*, 2022, 26, ms239e2266.
doi: <https://doi.org/10.54905/disssi/v26i124/ms239e2266>

Authors' Affiliation:

¹Junior Resident, Department of Pathology, Datta Meghe Institute of Medical Sciences, Sawangi (Meghe), Wardha, India
²Professor, Department of Pathology, Datta Meghe Institute of Medical Sciences, Sawangi (Meghe), Wardha, India
³Professor and Head, Department of Pathology, Datta Meghe Institute of Medical Sciences, Sawangi (Meghe), Wardha, India

*Corresponding Author

Junior Resident, Department of Pathology, Datta Meghe Institute of Medical Sciences, Sawangi (Meghe), Wardha, India
Email: nainasaluja16@gmail.com

Peer-Review History

Received: 26 April 2022
Reviewed & Revised: 27/April/2022 to 18/June/2022
Accepted: 19 June 2022
Published: 22 June 2022

Peer-review Method

External peer-review was done through double-blind method.

URL: <https://www.discoveryjournals.org/medicalscience>



This work is licensed under a Creative Commons Attribution 4.0 International License.

ABSTRACT

Women's ovarian tumors are a prevalent type of neoplasm. The most prevalent kind is mature cystic teratoma, which has an 8–15 % bilateral frequency. However, only a few cases of bilateral and multiple scleroses have been described. A 42-year-old female patient with stomach pain for one day arrived with an unusual case of bilateral multiple dermoid cysts. Her medical history had been relatively normal. The patient had clots passing in the menses. Multiple bilateral ovarian cystic tumors were discovered on ultrasonography. Laparotomy was performed on the patient. The lumps were removed while the remaining ovarian tissue was preserved. In histology, the myometrium is unremarkable. In histology, a cervix segment revealed chronic cervicitis with a Nabothian Cyst. A section of the right ovary revealed characteristics that pointed to a benign cystic teratoma of the right ovary (Dermoid cyst). Histopathology of the left fallopian tube revealed endometriosis. Histopathology confirmed multiple mature cystic teratomas with no signs of malignant cells.

Keywords: Dermoid cyst, Ovary, Teratoma

1. INTRODUCTION

In women, ovarian tumors are a prevalent neoplasm. The most common variety of teratoma, mature cystic teratoma, is producing 8–15 % bilaterally; hardly any examples of bilateral and numerous teratomas have been described (Young et al., 1994). Teratomas can be mature and immature, and they are often made up of numerous embryological layers. The mature form is harmless, while the immature version is also harmless but more aggressive (Alotaibi and Navarro, 2010). The most frequent ovarian tumor is mature one that accounts for 32% of all ovarian tumors (Russell and Painter, 1982). Mature cystic teratomas are found to be bilateral in approximately 15%. The occurrence in the same ovary of multiple ovarian teratomas is uncommon (Milingos et al., 2004; Shalev et al., 1998; Johnson and Jordan, 2001) and little examples of multiple and bilateral ovarian teratomas have been recorded.

MCT comprises demarcated tissues and three germ cell layers: ectoderm, mesoderm, and endoderm (Kim et al., 2011). These tumors account for 10–20 percent of all ovarian neoplasms, and they are most common in women aged twenty to forty (Kim et al., 2011; Harding et al., 1993). Mature cystic teratomas are normally benign, although they can turn cancerous in a small percentage

of instances (around 0.1–0.2%) (Kahraman et al., 2011). The majority of these tumors are slow-growing and unilateral (Kim et al., 2011), with only around 10% of instances being bilateral. In this paper we report a rare case of mature cystic teratoma that took an atypical path.

We are hereby reporting an uncommon site presentation of this tumor. This case is presented because of its strange and complicated presentation, which includes uncommon gross and microscopic features.

2. CASE PRESENTATION

A 42 year old female presented to pathology OPD, AVBRH Hospital Sawangi Meghe Wardha with complaints of menorrhagia for 6 months and pain in lower abdomen with backache. No relevant personal or family history exists. The patient had clots passing in the menses. The vital signs on the day of examination showed normal range i.e., blood pressure 136/93 mmHg, pulse rate is 84 beats/min. The blood group of the patient was A +ve, Hb was 9.9 gm%, TLC was 5.620 cubic millimeters.

Ultrasonography

USG Pelvis showed the size of uterus as 7.4 x 5.1 x 4.2 cm, normal contour, anteverted, with normal myometrial echotexture. There was evidence of heterogeneous echotexture cystic lesions of approximately size 8.5 x 7.4 x 6.7 cm with volume 224.2 ml seen in right adnexa and 8.1 x 6.3 x 5.5 cm, volume 150 ml, seen in left adnexa. Both the ovaries could not be separately differentiated from this lesion. The cystic lesions showed mixed hyperechoic and hypoechoic components with a superficial anechoic layer with suspended linear very thin fibrillar structures within. All these findings gave an impression of bilateral adnexal complex cystic lesion (bilateral dermoid cyst).

Gross features

Uterus measuring 8 x 5.5 x 4 cm, slit like cavity identified. Cervix measures 2.8 cm in length while the right ovary was measuring 7.5 x 7 x 4 cm. On the cut section of the right ovary, grey, pultaceous material oozed out and hair identified. Solid cystic areas identified. Right fallopian tube measured 4.5 cm in length and the left ovary was measuring 7 x 6 x 3 cm. On the cut section of the left ovary, greyish pultaceous material oozed out. Hair, solid-cystic and calcified areas identified. Left fallopian tube was measuring 4.5 cm in length (figure 1).

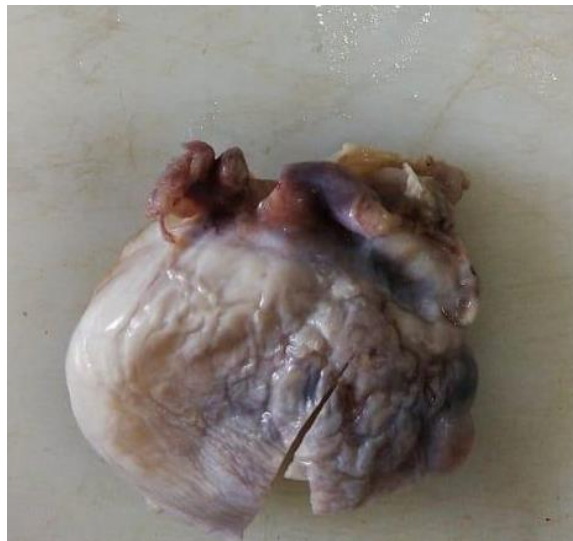

Figure 1 Dermoid Cyst

Microscopy

The histopathologic examination of the uterus with cervix showed features suggestive of simple glandular hyperplasia. The myometrium is unremarkable in histopathology. The section from cervix showed chronic cervicitis with Nabothian Cyst on histopathology. Section from the right ovary showed features suggestive of benign cystic teratoma of the right ovary (Dermoid cyst). Left fallopian tube confirmed endometriosis on histopathology (figure 2 and 3).

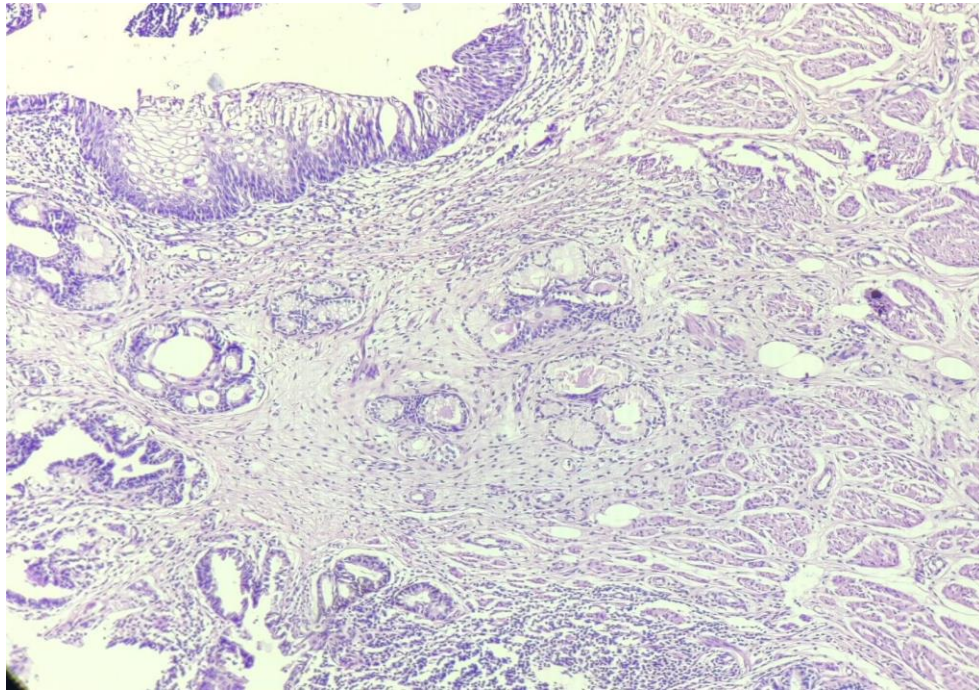


Figure 2 Left ovary: Presence of all three derivatives seen- Epithelium, glands and muscle.

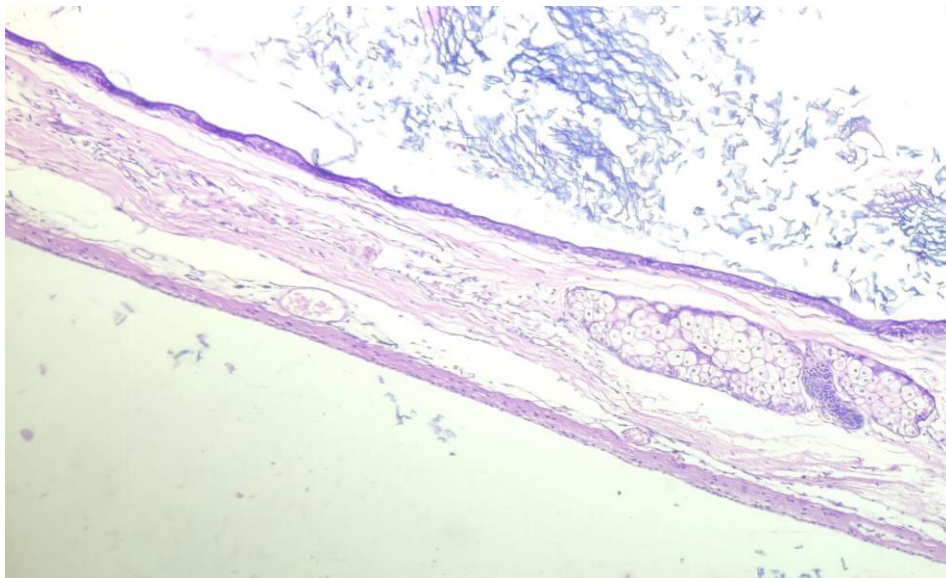


Figure 3 Right ovary: Cyst wall lined by Squamous epithelium with its adnexa.

3. DISCUSSION

Multicellular germ cell tumors that originate from one or more of the three germ layers are known as ovarian teratomas. A study of produced teratoma tissues revealed components of various tissue characteristics. Shi et al., (2016), found developed squamous epithelium with cornifying material and hairs on the surface of a cystic ovarian teratoma in a study. There were also sebaceous glands, sweat glands, hair follicles, and fat tissue. Teratoma is derived from the Greek term *teras*, which means monster, and was first used in 1863 by Virchow in his book on tumors (Pantoja et al., 1975). Mature, immature, and monodermal are the three classifications. The majorities have a 46XX karyotype and are likely to have developed from a single haploid germ cell during parthenogenesis (Vortmeyer et al., 1999). It affects persons of all ages; however it is more common in women in their reproductive years (20–40 years) (Ozgur et al., 2012).

Ovarian teratoma usually has a slow progression and causes abdominal pain as a result of problems such as torsion, bleeding, or infection. Approximately 44% of all ovarian tumors and 58 % of benign ovarian tumors are caused by mature cystic teratomas. They're generally unilateral, with 8–15 percent bilateral, and 9 percent of pathologic investigations revealed multiple ovarian

teratomas on the ipsilateral side (Fayez et al., 2018). On both sides of the ovary, multiple large synchronous ovarian mature cystic teratomas were identified in 2015. The patient was experiencing dull, agonizing stomach pain that was not caused by torsion. Torsion, on the other hand, was a serious complication in a few uncommon cases after autoamputation of the ovary and fallopian tube (Fayez et al., 2018).

Ultrasonography is a non-invasive and effective study that women of all ages can use. In addition, tumor markers like CA125, CA91-9, and alpha fetoprotein are used to detect and characterize ovarian tumors in their early stages (Fayez et al., 2018). These women are apprehensive about their ability to reproduce in the future. In our case, the patient's general condition warranted laparotomy (Fayez et al., 2018). When designing an operational strategy, the patient's symptoms and wishes must be taken into account, as well as the ultrasound characteristics of the ovarian lesion. An ultrasound diagnosis of a complicated solid and cystic ovarian mass could indicate an MCT, but it could also be an endometrioma or malignant tumor (Templeman et al., 2000). In the absence of symptoms, patients at risk must be evaluated further in order to save their ovarian tissues. We strongly encourage you to have regular follow-up appointments and ultrasounds.

4. CONCLUSION

In the presence of bilateral adult cystic teratomas, there are concerns about recurrence and accompanying problems. In the absence of symptoms, patients at risk must be evaluated further in order to save their ovarian tissues. We strongly encourage you to have regular follow-up appointments and ultrasounds.

Acknowledgement

We thank the participants who all contributed samples to the study.

Author Contributions

Naina Saluja designed the study, performed the experimental analyses, wrote, revised, and edited the manuscript. Jayant S Makrande, Kishore Hiwale, and Sunita Vagha participated in manuscript editing and manuscript reviewing.

Informed consent

Written & Oral informed consent was obtained from all individual participants included in the study. Additional informed consent was obtained from all individual participants for whom identifying information is included in this manuscript.

Funding

This study has not received any external funding.

Conflicts of interest

The authors declare that there are no conflicts of interests.

Data and materials availability

All data associated with this study are present in the paper.

REFERENCES AND NOTES

- Alotaibi MO, Navarro OM. Imaging of ovarian teratomas in children: a 9-year review. *Can Assoc Radiol J* 2010; 61(1):23-28.
- Fayez I, Khreisat B, Athamneh T, Omoosh R, Daibes MA. Multiple bilateral ovarian mature cystic teratomas with ovarian torsion: a case report. *Oman Med J* 2018; 33(2):163.
- Harding MJ, Paul J, Gillis CR, Kaye SB: Management of malignant teratoma: does referral to a specialist unit matter? *Lancet* 1993; 341:999-1002.
- Johnson SC, Jordan GL. Sonographic diagnosis of multiple unilateral ovarian teratomas. *J Ultrasound Med* 2001; 20(3):279-281.
- Kahraman K, Cetinkaya SE, Kankaya D, Dunder I, Soylemez F: Squamous cell carcinoma arising from mature cystic teratoma of the ovary with synchronous endometrial adenocarcinoma. *J Obstet Gynaecol Res* 2011; 37:146-150.
- Kim MJ, Kim NY, Lee DY, Yoon BK, Choi D: Clinical characteristics of ovarian teratoma: age-focused retrospective analysis of 580 cases. *Am J Obstet Gynecol* 2011; 205:e1-e32.

7. Milingos S, Protopapas A, Drakakis P, Liapi A, Loutradis D, Rodolakis A, Milingos D, Michalas S. Laparoscopic treatment of ovarian dermoid cysts: eleven years' experience. *J Am Assoc Gynecol Laparosc* 2004; 11(4):478-485.
8. Ozgur T, Atik E, Silfeler DB, Toprak S. Mature cystic teratomas in our series with review of the literature and retrospective analysis. *Arch Gynecol Obstet* 2012; 285(4):1099-1101.
9. Pantoja E, Noy MA, Axtmayer RW, Colon FE, Pelegrina I. Ovarian dermoids and their complications. Comprehensive historical review. *Obstet Gynecol Surv* 1975; 30(1):1-20.
10. Russell P, Painter DM. The pathological assessment of ovarian neoplasms V: The germ cell tumors. *Pathol* 1982; 14(1):47-72.
11. Shalev E, Bustan M, Romano S, Goldberg Y, Ben- Shlomo I. Laparoscopic resection of ovarian benign cystic teratomas: experience with 84 cases. *Hum Reprod* 1998; 13(7):1810-1812.
12. Shi XX, Shen H, Chen T, Pan ZY, Wu XF, Zou ZN, Zhang SS, Sun DJ, Zhang YZ. Mature Cystic Teratoma of the Ovary With Three Kinds of Entire Gastrointestinal Wall and Complete Bronchial Structure in a Pregnant Woman. *Int J Surg Pathol* 2016; 24(5):428-430.
13. Templeman CL, Fallat ME, Lam AM, Perlman SE, Hertweck SP, O'Connor DM. Managing mature cystic teratomas of the ovary. *Obstet Gynecol Surv* 2000; 55(12):738-45.
14. Vortmeyer AO, Devouassoux-Shisheboran M, Li G, Mohr V, Tavassoli F, Zhuang Z. Microdissection-based analysis of mature ovarian teratoma. *Am J Pathol* 1999; 154(4):987-991.
15. Young RH, Clement PB, Sully RE. The ovary, in *Diagnostic surgical pathology*, S.S. Sternberg, Editor. 1994, Ravan press: New York. p. 2195.