

To Cite:

Mundada P, Patil S, Kaple G, Kaple N. Impact of cervical mobilization, proprioceptive neuromuscular facilitation and active release technique on neck function, disability and quality of life in a hemithyroidectomy patient: A case report. *Medical Science*, 2022, 26, ms220e2264.

doi: <https://doi.org/10.54905/disssi/v26i124/ms220e2264>

Authors' Affiliation:

¹Intern, Ravi Nair Physiotherapy College, Datta Meghe Institute of Medical Sciences (DU), Sawangi Meghe, Wardha, Maharashtra, India; Email: urvamundada4444@gmail.com, Orcid: <https://orcid.org/0000-0002-3585-7480>

²Professor & HOD, Department of Community Physiotherapy, Ravi Nair Physiotherapy College, Datta Meghe Institute of Medical Sciences (DU), Sawangi Meghe, Wardha, Maharashtra, India; Email: shubhangipatil148@yahoo.in, Orcid: <https://orcid.org/0000-0003-3066-0176>

³Intern, Ravi Nair Physiotherapy College, Datta Meghe Institute of Medical Sciences (DU), Sawangi Meghe, Wardha, Maharashtra, India; Email: gkaple9@gmail.com, Orcid: <https://orcid.org/0000-0002-5074-277X>

⁴Intern, Ravi Nair Physiotherapy College, Datta Meghe Institute of Medical Sciences (DU), Sawangi Meghe, Wardha, Maharashtra, India; Email: nikitaakaple@gmail.com, Orcid: <https://orcid.org/0000-0002-1278-5242>

Corresponding Author

Intern, Ravi Nair Physiotherapy College, Datta Meghe Institute of Medical Sciences (DU), Sawangi Meghe, Wardha, Maharashtra, India; Email: urvamundada4444@gmail.com

Peer-Review History

Received: 25 April 2022

Reviewed & Revised: 27/April/2022 to 06/June/2022

Accepted: 07 June 2022

Published: 13 June 2022

Peer-review Method

External peer-review was done through double-blind method.

URL: <https://www.discoveryjournals.org/medicalscience>



This work is licensed under a Creative Commons Attribution 4.0 International License.

Impact of cervical mobilization, proprioceptive neuromuscular facilitation and active release technique on neck function, disability and quality of life in a hemithyroidectomy patient: A case report

Purva Mundada^{1*}, Shubhangi Patil², Gayatri Kaple³, Nikita Kaple⁴

ABSTRACT

Colloid Nodular Goitre is the most common form of goitre seen globally and it is also one of the most common endocrine problems, especially in nations where iodine shortage is widespread, like India. A 40-year-old female presented to ENT department of this hospital with large thyroid swelling on the left side and after investigations diagnosed with multinodular colloid goiter which was surgically treated by right hemithyroidectomy under general anesthesia. Post-surgery, neck pain, shoulder tightness, limitation of the cervical and shoulder movements and difficulty in ADLS were the main concerns of the patient. The patient was referred to the physiotherapy department with these problems. Physiotherapy rehabilitation resulted in reduction in neck discomfort, improvement in cervical and shoulder movements and muscle strength and overall quality of life as well as ease in performing ADLS. The current case demonstrated that physiotherapy rehabilitation post-surgery can improve patient outcomes and make him/ her independent in activities of daily living.

Keywords: Colloid Nodular Goitre, Right Hemithyroidectomy, Hypothyroidism, Osteoporosis.

1. INTRODUCTION

Goiter is a spontaneous swelling of the thyroid gland induced by compensatory hyperplasia and hypertrophy of the follicular epithelium. Before middle age, nodular goitre is uncommon, and a female preponderance is evident (Budhiraja et al., 2020). It's a clinical condition that involves the

growth, structural, or functional alteration of one or more sections of normal thyroid tissue (Sharma, 2011). In areas where iodine shortage is widespread, such as India, colloid nodular goitre is among the most common hormonal abnormalities (Budhiraja et al., 2020). Colloid goitres are benign thyroid lesion that manifests them as a diffuse or nodular pattern, characterised by thyroid enlargement without a change in thyroid function. Foods that impede hormonal synthesis, mutations in Thyroid Stimulating Hormone (TSH) receptors, globulin stimulation of thyroid development, growth hormone, insulin-like growth factor 1 (IGF-1), and hereditary factors are all probable causes of a colloidal goitre (Al-Hureibi et al., 2004; Bruka et al., 2014; Dauksiene et al., 2017; Hoang and Trinh, 2020).

The most essential component in the appearance of colloidal goitre is a long-term decline in TSH stimulation. Follicular cell hyperplasia occurs in cases of diffuse goitre. Some follicles become independent in prolonged TSH stimulation conditions and produce hormones that depress other regions, causing them to involute. This results in a multinodular goitre with localized hyperplasia, involution, and fibrosis (Verma et al., 2016). Majority of patients with colloid goitre have no symptoms. The patient or others may find the enlargement inadvertently (Hoang and Trinh, 2020). In long-term goitres, medical treatment has little or no effect. Surgical therapy provides the benefit of a low recurrence rate.

Thyroidectomy is the most common therapy for benign and malignant thyroid illnesses which include symptomatic large goitres, hyperthyroidism, thyroid nodules, and thyroid cancer (Chahardahasumi et al., 2019; Shehata et al., 2020). It is an operative procedure comprising of complete or partial removal of thyroid gland (Liu et al., 2015; Nagib et al., 2019). Hemithyroidectomy or thyroid lobectomy aims to remove a portion of the thyroid gland that harbors the nodule while sparing the contralateral lobe (Liu et al., 2015; Abdelmohsen and Ahmed, 2017).

Hypothyroidism, hypoparathyroidism, hypocalcemia, wound infection, hematoma, recurrent laryngeal nerve injury, and Horner's syndrome are the most common postoperative sequelae (Abdelmohsen and Ahmed, 2017; Chahardahasumi et al., 2019). The occurrences of possible complications inflicted by thyroidectomy have a detrimental effect on patient's quality of life.

2. CASE HISTORY

A 40 years old female presented to tertiary care rural hospital with the complaint of swelling on the left side of the neck which was 10cm by 5cm in size. Histopathology report was suggestive of a toxic nodular goiter. USG Guided FNAC showed isolated giant follicles in sheets of follicular cells with moderate anisonucleosis. It was suggestive of colloid nodular goitre with toxic changes and hemorrhagic cyst. CECT Neck was suggestive of large heterogenous lesion arising from both lobes and predominantly right lobe of thyroid extending from C3 to D3 with compression and displacement of the trachea. Thus, the diagnosis was confirmed to be multinodular colloid goiter. Under general anaesthesia, she underwent right hemithyroidectomy, wherein a horizontal incision was given running from the anterior border of the left sternocleidomastoid muscle up to the right sternocleidomastoid 2 fingers above the sternum. The patient was referred to the physiotherapy department after surgery. After taking the patient's consent, a physical examination was carried out. On local examination, restrictions were noted in cervical and shoulder range of motion along with neck pain. Pre-intervention cervical and shoulder Range of Motion (ROM) was noted and tabulated in table1. Neck pain as rated by patient on NPRS: 7/10 on activity and 5/10 at rest.

Table 1 Pre intervention cervical and shoulder ROM

Cervical	Range of Motion (Degree)	
Flexion	45	
Extension	50	
Side Flexion (Right)	35	
Side Flexion (Left)	40	
Right Rotation	45	
Left Rotation	50	
Shoulder	Left	Right
Flexion	170	140
Abduction	170	130

Resisted Isometric Contraction (RIC)

Strong and painful for cervical flexors, extensors, side flexors and rotators

Strong and painless for shoulder flexors and abductors, scapular elevators, protractors and retractors bilaterally

Manual muscle testing

Strength of cervical flexors and rotators was -3/5 and that of extensors and side flexors was +3/5. Strength of shoulder flexors and abductors; scapular elevators, protractors and retractors was -3/5 and 5/5 respectively on right and left sides.

Therapeutic Intervention

Pharmacological Management

The patient was currently on Ceftriaxone, Sulbactam, Pantoprazole, Dexa, Neomol, Zerodol, Chymoral Forte, Methyl Cobalamine, Rocatrol, Shelcal, Limcee, and Rapitus Plus.

Physiotherapy Intervention

Physiotherapy rehabilitation protocol with goals and day wise intervention is given in Table 2.

Table 2 Physiotherapy Rehabilitation Protocol

Sr. No	Goals	Physiotherapy Intervention	Physiotherapy Intervention Day Wise
	To prevent anxiety	Patient Education and Counselling The patient was educated about her current condition, the importance of following the prescribed exercise protocols, the importance of exercise adherence, and how to practice the given exercise protocol, as well as their repetitions, sets, and durations, with detailed description and illustrations.	Patient was educated and counselled from day 1 to day 30.
	To reduce neck pain	[Transcutaneous Electrical Nerve Stimulation (TENS)] 4 electrodes were used. 2 electrodes were placed on the back of the neck at the base of the hairline and the other 2 over the top of the shoulder (backside). Conventional mode of TENS was used with a frequency of 100 Hz, duration 10 minutes with intensity as tolerated by the patient.	For neck pain, TENS was given from day 2 to day 20.
	To reduce neck pain, stiffness and improve ROM	Cervical mobilization Upper cervical flexion mobilization in supine position (Calixtre et al., 2016). Central posterior-anterior mobilization in prone position (Calixtre et al., 2016). Cervical rotation mobilization in supine position (Nambi et al., 2013).	Initiated from 2 nd week. Started with Maitland’s grade 2 progressing to grade 4 and performed for duration of 10 minutes.
		[Active Release Technique (ART)] for upper trapezius, scalenes, splenius capitis, [sternocleidomastoid (SCM)] and pectorals (Jane Johnson, 2018).	Started from week 2. Given for 10 minutes.
	To improve ROM and strength of neck muscles	Neck [Proprioceptive Neuromuscular Facilitation (PNF)] in sitting position Flexion pattern: The therapist stepped behind the patient on the right side and positioned right finger beneath her chin and left hand diagonally on top of the patient’s head on the left side. The therapist gently lifted the chin, causing the neck to extend and the head to tilt and rotate to the right. Commands were issued such as	Neck PNF. It is given in figure 1 and figure 2. Day 1-7: 10 repetitions 1 set Day 8-21:10 repetitions 2 set Day 21-30: 10 repetitions 3 set

		<p>"draw your chin in" and "glance at your left hip." Resistance was applied to left rotation, flexion, and lateral flexion, along with chin traction (Hwangbo and Don Kim, 2016).</p> <p>Extension pattern: The therapist's position was the same. The therapist placed right thumb on the right side of the patient's chin and left hand diagonally on top of head on the right side. The therapist slightly pulled the chin so that the neck was flexed; head was rotated and tilted to the left. Commands were issued such as "raise your chin and then lift your head to look upwards." Resistance was applied to right rotation, extension and lateral flexion (Hwangbo and Don Kim, 2016).</p>	
	To increase shoulder joint ROM	<p>AROM exercises for shoulder</p> <p>Flexion and abduction- Finger ladder (Wall) exercises, shoulder wheel, shoulder pulley, wall washing exercises. [Upper Extremity (UE)] D1 and D2 flexion and extension pattern were also performed (using rhythmic initiation technique).</p>	<p>AROM exercises for shoulder</p> <p>Day 1-7: 10 repetitions 1 set</p> <p>Day 8-21:10 repetitions 2 set</p> <p>Day 21-30: 10 repetitions 3 set</p> <p>UE PNF</p> <p>Day 1-7: 10 repetitions 1 set</p> <p>Day 8-21:10 repetitions 2 set</p> <p>Day 21-30: 10 repetitions 3 set</p>
	To maintain the length of muscles of the cervical spine and shoulder.	<p>Stretching for trapezius, scalene, semispinalis muscle of head, splenius capitis, SCM, pectoral muscles (Calixtre et al., 2016) .</p>	<p>Day 1-7: 10 repetitions 10 second hold</p> <p>Day 8-14: 10 repetitions 20 second hold</p> <p>Day 15-30: 10 repetitions 30 second hold</p>
	To improve functional mobility	<p>Graded Exercise Program</p> <p>A monitored supervised graded exercise program was initiated. Monitored supervised ambulation along the hallway 2 rounds 3-4 times a day.</p> <p>Sit to stand was also practised starting from 5 repetitions then making increment of 5 repetitions every week.</p>	<p>AROM Exercises for lower limb, ankle toe movements, dynamic quads and straight leg raise were given for 10 repetitions 2 sets 3-4 times/day from day 1 to day 30.</p> <p>Ambulation (distance covered)</p> <p>Day 1-7: 10-20 metres</p> <p>Day 8-14: 20-30 metres</p> <p>Day 15-21: 30-40 metres</p> <p>Day 21-27: 40-50 metres</p> <p>Day 27-30: 50-60 metres</p>
	To preserve the gain in range and strength as well as to prevent	<p>Home Exercise Program</p> <p>On the day of discharge, patient was prescribed written home exercise program which included range of motion, stretching and strengthening exercises. Precise explanation was given on how to practice the given exercise protocol along with their repetitions, sets, and</p>	<p>Aerobic activities</p> <p>Frequency- 4 to 5 days per week, Intensity- moderate intensity (rating of 3 to 4 on Borg scale of 0 to 10). Patient was told to begin walking</p>

	osteoporosis	<p>durations, with detailed description and illustrations. In order to prevent osteoporosis, patient was prescribed walking and other forms of low impact aerobics activities such as cycling and yoga (Daly et al., 2019). Home exercise program was given as per ACSM guidelines with regards to FITT principle</p>	<p>with shorter duration of 15-20 minutes. Thereafter, add 5 minutes to each session thus increasing duration every 2-4 weeks. Eventually, progress to minimum 30 minutes a day (maximum 45 to 60 mins).</p> <p>Resistance training Frequency- 2-3 times per week, Intensity- Moderate intensity with 8 to 12 repetitions. Patient was told to start with 1 set of 8-12 repetitions; then increase to 2 sets after 2 weeks. Resistance training for upper and lower body was given using resistance band. Stretching Exercises – Frequency - 5-7 days per week. Intensity- patient was told to stretch to the point of maximum tightness. Duration- Holding static stretch for 10-30 second with 2-4 repetitions of each exercise. Static stretching of all the major joints was told to practice.</p>
--	--------------	---	--

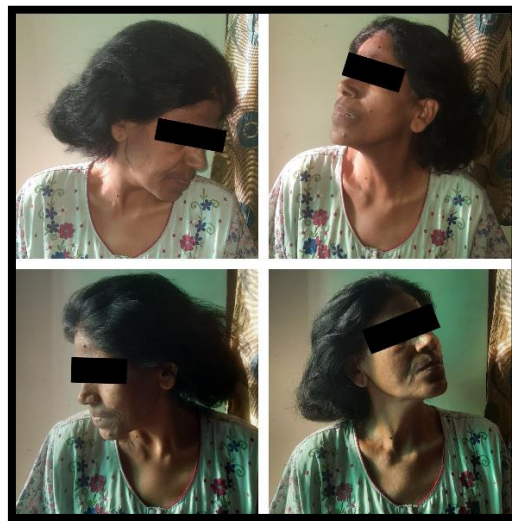

Figure 1 Patient performing diagonal neck PNF patterns actively.




Figure 2 Patient performing diagonal neck PNF patterns actively against resistance.

Outcome

Neck pain as rated by patient on NPRS: 3/10 on activity and 2/10 at rest. ROM: Post intervention ROM is given in table 3.

Table 3 Post intervention ROM

Cervical	Range of Motion (Degree)	
Flexion	58	
Extension	60	
Side Flexion (Right)	48	
Side Flexion (Left)	50	
Right Rotation	62	
Left Rotation	65	
Shoulder	Left	Right
Flexion	170	160
Abduction	170	155

MMT: Strength of cervical flexors and rotators was 4/5 and that of extensors and side flexors was +4/5. Strength of shoulder flexors and abductors; scapular elevators, protractors and retractors was +4/5 and 5/5 respectively on right and left sides.

HRQOL: Graphical representation of SF36 pre and post intervention is given in figure 3.

NDI: Graphical representation of NDI pre and post intervention is given in figure 4.

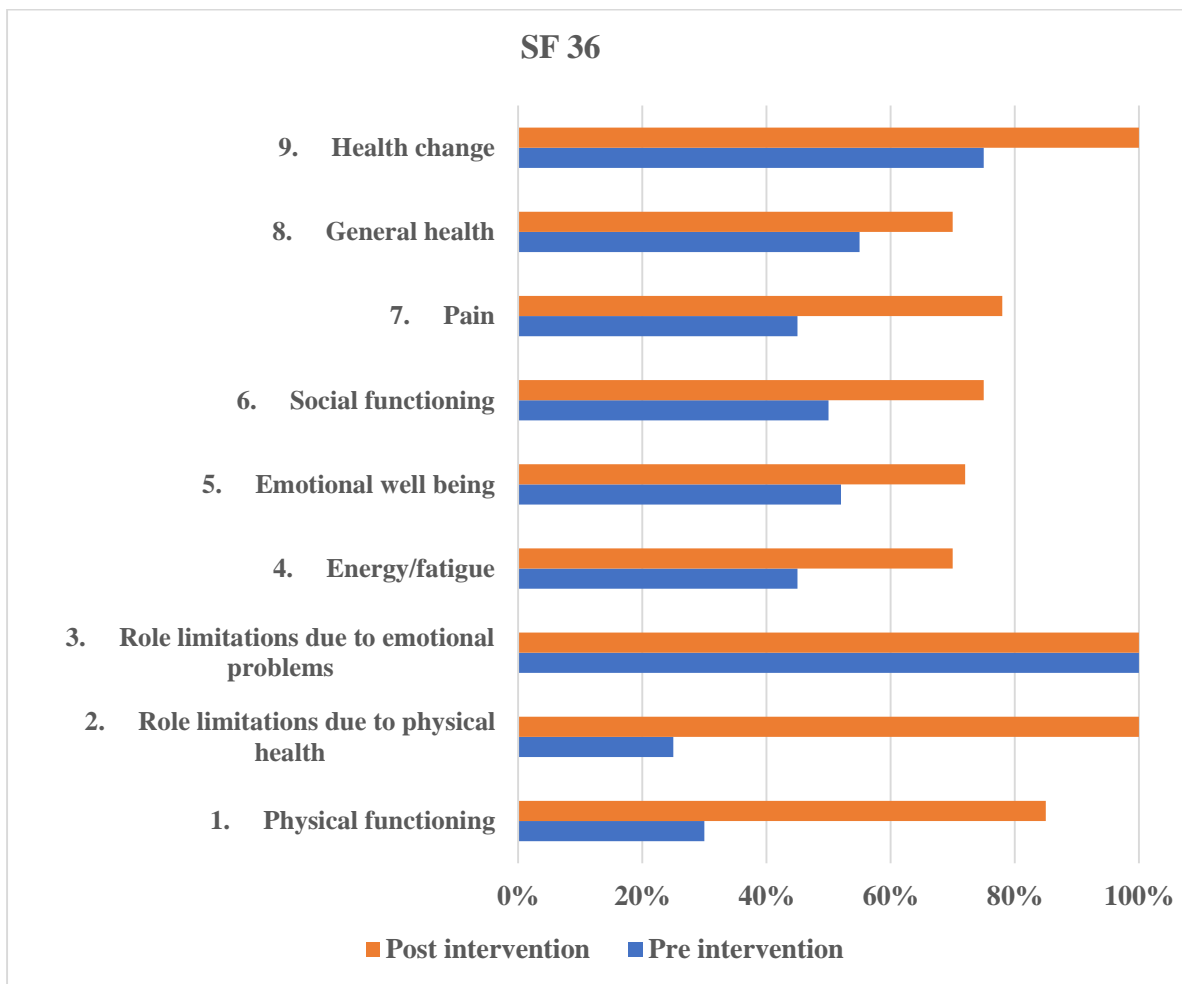


Figure 3 SF 36 which measures health related quality of life.

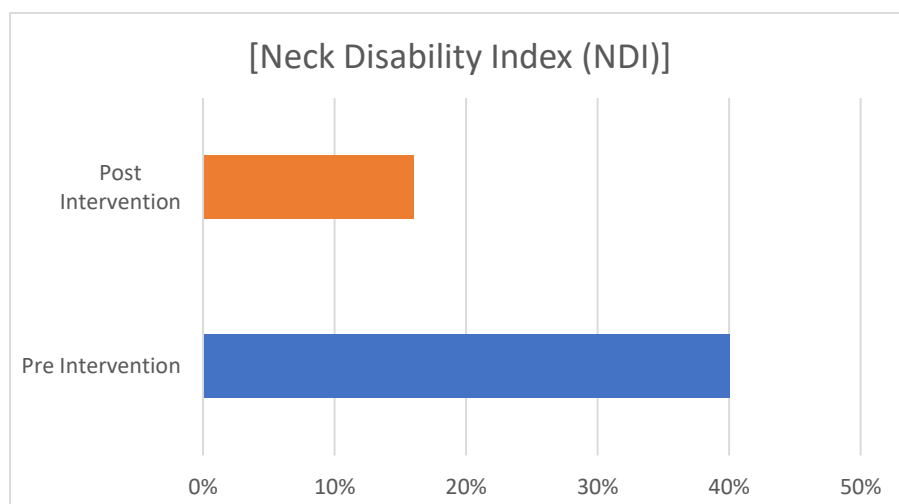


Figure 4 NDI which measures patient reported disability secondary to neck pain.

3. DISCUSSION

It is reported that 54 million people in India suffer from goitre, with an additional 167 million at risk (Reddy et al., 2019). It is three times more common in females than in males (Siddiqui et al., 2018), with a significant incidence among elderly women in their fifth and sixth decades. Thyroidectomy is amongst the most frequent surgical operations performed around the world, but it comes with a slew of risks (Shehata et al., 2020). Hemithyroidectomy is done for various issues, comprising benign and malignant thyroid

illness symptomatic unilateral goitre or toxic adenoma (Verloop et al., 2012) and pathologically questionable nodule (Cao et al., 2022).

Patients experience post-surgery occipital headache, posterior neck discomfort, shoulder tightness, and cervical and shoulder movement restrictions due to confined placement of the neck during and after operation (Takamura et al., 2005). Posterior neck discomfort occurs as a result of hyperextension of neck during operation (in order to provide good exposure to the operative area as well as to expedite the operative procedure) (Ayhan et al., 2016; Shehata et al., 2020). Reduced scar mobility following a neck operation might restrict ROM, particularly in the rotation and extension directions. The loss of motor innervations to the SCM and trapezius causes a reduction in shoulder mobility and strength, which leads to a reduction in cervical ROM.

Rehabilitation helps to restore physical, mental, and social function by preventing and treating issues that emerge as a result of surgical management. Neck PNF has been shown to increase functional performance while also strengthening and stretching the neck muscles. It's often utilized as a progressive resistance for functional training, improving restricted ranges, and strengthening muscles. It relieves discomfort and improves flexibility, resulting in an improvement in neck ROM and Quality of Life (QOL) (Pattanshetty and Mathias, 2018). Cervical mobilization has been shown to alleviate discomfort, increase neck ROM, and promote muscle balance between flexors and extensors, as well as right and left side flexors (Garg, 2021). There is no evidence regarding efficacy of cervical mobilization and ART in reducing neck disability in hemithyroidectomy patients. But, in our study, it has been observed that combination of cervical mobilization, neck PNF and ART is effective in reducing neck disability in such cases.

Hemithyroidectomy has several recognized side effects, including postoperative bleeding, laryngeal nerve damage, wound infection, hypothyroidism, hypoparathyroidism and concomitant hypocalcemia (Cao et al., 2022). Hypothyroidism affects 11 % to 45 % of patients (Cao et al., 2022). TH replacement is necessary, however, long-term thyroid hormone therapy has been linked to rapid bone mineral density loss (Verloop et al., 2012; Palop et al., 2021). Women with lowered TSH levels are three times more likely to develop osteoporosis than those whose levels are not lowered (Zakaria, 2018). After thyroid surgery, the risk of osteoporosis rises, especially if patients are given high doses of levothyroxine. Postoperative osteoporosis can be avoided by incorporating a physiotherapy rehabilitation program that includes weight-bearing exercises such as walking, flexibility and strengthening exercises, and postural exercises, etc.

4. CONCLUSION

This study concluded that combination of cervical mobilization, neck PNF and ART is very effective in reducing pain, improving ROM and strength of neck as well as QOL in patients who have undergone hemithyroidectomy.

Acknowledgement

I am thankful to all the contributors in this study as well as to the patient for being cooperative.

Author Contributions

All authors contributed equally to this work and they have read and agreed to the final manuscript.

Informed Consent

Written and oral consent was obtained from the patient involved in the study.

Funding

This study has not received any external funding.

Conflicts of interest

The authors declare that there are no conflicts of interests.

Data and materials availability

All data associated with this study are present in the paper.

REFERENCES AND NOTES

1. Abdelmohsen S, Ahmed N. Effect of teaching patients neck stretching exercises on neck pain and disability following thyroidectomy. *J Nurs Educ Pract* 2017; 8:107. doi: 10.5430/jnep.v8n1p107

2. Al-Hureibi KA, Abdulmughni YA, Al-Hureibi MA, Al-Hureibi YA, Ghafoor MA. The epidemiology, pathology, and management of goitre in Yemen. *Ann Saudi Med* 2004; 24:119–123. doi: 10.5144/0256-4947.2004.119
3. Budhiraja G, Dhingra HS, Guram D, Goyal S, Bharti P. An unusual presentation of large colloid goiter – A case report. *Adesh Univ J Med Sci Res* 2020; 2:64–66. doi: 10.25259/AUJMSR_14_2020
4. Calixtre LB, Grüniger BL da S, Haik MN, Albuquerque-Sendín F, Oliveira AB. Effects of cervical mobilization and exercise on pain, movement and function in subjects with temporomandibular disorders: a single group pre-post test. *J Appl Oral Sci Rev FOB* 2016; 24:188–197. doi: 10.1590/1678-775720150240
5. Cao Z, Liu R, Wu M, Xu X, Liu Z. Risk factors for thyroid hormone replacement therapy after hemithyroidectomy and development of a predictive nomogram. *Endocrine* 2022; 76:85–94. doi: 10.1007/s12020-021-02971-z
6. Chahardahasumi E, Salehidoost R, Amini M, Aminorroaya A, Rezvanian H, Kachooei A, Iraj B, Nazem M, Kolahdoozan M. Assessment of the Early and Late Complication after Thyroidectomy. *Adv Biomed Res* 2019; 8:14. doi: 10.4103/abr.abr_3_19
7. Daly RM, Dalla Via J, Duckham RL, Fraser SF, Helge EW. Exercise for the prevention of osteoporosis in postmenopausal women: an evidence-based guide to the optimal prescription. *Braz J Phys Ther* 2019; 23:170–180. doi: 10.1016/j.bjpt.2018.11.011
8. Garg K. Effect of Cervical Mobilization, Transcutaneous Electrical Stimulation and Suboccipital Release in Cervicogenic Headache: A Case Report. *Int J Heal Sci Res* 2021; 11:81. doi: 10.52403/ijhsr.20210812
9. Hoang VT, Trinh CT. A Review of the Pathology, Diagnosis and Management of Colloid Goitre. *Eur Endocrinol* 2020; 16:131–135. doi: 10.17925/EE.2020.16.2.131
10. Hwangbo PN, Don Kim K. Effects of proprioceptive neuromuscular facilitation neck pattern exercise on the ability to control the trunk and maintain balance in chronic stroke patients. *J Phys Ther Sci* 2016; 28:850–853. doi: 10.1589/jpts.28.850
11. Johnson Jane. Chapter 6- Soft tissue release for the trunk. In: Stone JJ, Zavala MJ, Mrozek AE, Portman JH, eds. *Soft Tissue and Trigger Point Release*. 2nd edition. United States of America, USA: Human Kinetics; 2018. pp 124-149.
12. Liu ZW, Masterson L, Fish B, Jani P, Chatterjee K. Thyroid surgery for Graves' disease and Graves' ophthalmopathy. *Cochrane Database Syst Rev* CD010576. 2015. doi: 10.1002/14651858.CD010576.pub2
13. Nagib S, Karkousha R, Nahas E. Effect of stretching exercises vs. Kinesio Taping on postoperative neck discomfort following total thyroidectomy in postmenopausal women. *Physiother Q* 2019; 27:21–25. doi: 10.5114/pq.2019.89463
14. Nambi G, Vora P, Jhang M. Cervical spine mobilization versus Thoracic spine manipulation in subjects with unilateral C6 and C7 Cervical Radiculopathy - Comparative study. *Int J Adv Sci Tech Res* 2013; 1:304–319.
15. Pattanshetty R, Mathias O. Effect of proprioceptive neuromuscular facilitation neck pattern exercise on cervical range of motion and quality of life in post-operative head and neck cancer patients: an interventional study. *Int J Physiother Res* 2018; 6: 2857–2863. doi: 10.16965/ijpr.2018.160
16. Reddy TSK, Kamath VG, Jacob GP, Kamath A, Rebeiro C. Prevalence of goiter and its association with iodine status among the women of reproductive age group in coastal villages of Udupi Taluk, Karnataka, India. *Indian J Public Health* 2019; 63:199. doi: 10.4103/ijph.IJPH_27_18
17. Sharma B. A case of colloidal nodular goiter. *Indian J Res Homoeopathy* 2011; 5:40-46.
18. Shehata OEKA, Shehata OSMH, Elalem S, Mohamed A. Effect of neck range of motion exercises on neck disability and pain among patients undergoing thyroidectomy. *Clin Nurs Stud* 2020; 8:1. doi: 10.5430/cns.v8n4p1
19. Siddiqui Y, Moupachi S, Baghel D. A clinical, biopathological study of multinodular goitre in Rewa region, Madhya Pradesh. *J Evol Med Dent Sci* 2018; 7:1318–1322. doi: 10.14260/jemds/2018/300
20. Takamura Y, Miyauchi A, Uruno T, Ito Y, Miya A, Kobayashi K, Matsuzuka F, Amino N, Kuma K. Stretching Exercises to Reduce Symptoms of Postoperative Neck Discomfort after Thyroid Surgery: Prospective Randomized Study. *World J Surg* 2005; 29:775–779. doi: 10.1007/s00268-005-7722-3
21. Verloop H, Louwerens M, Schoone JW, Kievit J, Smit JWA, Dekkers OM. Risk of Hypothyroidism following Hemithyroidectomy: Systematic Review and Meta-Analysis of Prognostic Studies. *J Clin Endocrinol Metab* 2012; 97: 2243–2255. doi: 10.1210/jc.2012-1063
22. Verma R, Gupta S, Kalra R, Sen R, Samal S, Sharma J, Malik S. Colloid goiter in ectopic thyroid tissue presenting as submandibular swelling with a coexisting functional orthotopic thyroid gland in a pregnant female. *J Cytol* 2016; 33: 239–240. doi: 10.4103/0970-9371.190452
23. Zakaria, Moafy, Ereny S Wahba, Amir A Aboutahoun. Efficacy of Whole Body Vibration on Post Thyroidectomy Osteoporosis. *Med J Cairo Univ* 2018; 86:561–565. doi: 10.21608/mjcu.2018.55207