

To Cite:

Kariya SK, Utamchandani SR, Pansopkar PA. Rehabilitation of a sub-trochanteric fracture of a 43-year-old male with a permanent disability of right lower limb: a case report. *Medical Science*, 2022, 26, ms184e2162. doi: <https://doi.org/10.54905/disssi/v26i123/ms184e2162>

Authors' Affiliation:

¹Ravi Nair Physiotherapy College, Datta Meghe Institute of Medical Sciences, Sawangi, Wardha, Maharashtra, India

²Department of Musculoskeletal Physiotherapy, Ravi Nair Physiotherapy College, Datta Meghe Institute of Medical Sciences, Sawangi (Meghe), Wardha, Maharashtra, India; Email: shivani.u@dmimsu.edu.in; ORCID: <https://orcid.org/0000-0002-7154-9928>

³Head of Department, Musculoskeletal Physiotherapy, Ravi Nair Physiotherapy College, Datta Meghe Institute of Medical Sciences, Sawangi Meghe, Wardha, India; Email: drpratik77@gmail.com; ORCID: <https://orcid.org/0000-0003-3635-8840>

***Corresponding author**

Department of Musculoskeletal Physiotherapy, Ravi Nair Physiotherapy College, Datta Meghe Institute of Medical Sciences, Sawangi (Meghe), Wardha, Maharashtra, India; Email: shivani.u@dmimsu.edu.in

Peer-Review History

Received: 11 March 2022

Reviewed & Revised: 12/March/2022 to 14/May/2022

Accepted: 15 May 2022

Published: 20 May 2022

Peer-review Method

External peer-review was done through double-blind method.

URL: <https://www.discoveryjournals.org/medicalscience>



This work is licensed under a Creative Commons Attribution 4.0 International License.

Rehabilitation of a sub-trochanteric fracture of a 43-year-old male with a permanent disability of right lower limb: a case report

Sakshi K Kariya¹, Shivani Rajesh Utamchandani^{2*}, Pratik Arun Pansopkar³

ABSTRACT

Sub-trochanteric fractures occur between the lesser trochanter and 5cm distally on the proximal femoral neck. These fractures contribute for around 7% to 34% of all femur fractures. Fractures in younger people are more frequent by high-energy trauma and have a significant comminution; however, fractures in the elderly are more likely to be caused by low-energy traumas. To achieve a return to adequate functional independence and mobility, sub-trochanteric fractures generally demand a multidisciplinary approach that includes sufficient surgical fixation, early mobilization, and physical rehabilitation. Many studies, on the other hand, have validated intensive physical therapy in the acute care phase, stating that it improves recovery as compared to delayed physical therapy. Furthermore, patients in the early phase of hospitalization who received a high-intensity physiotherapy session met functional discharge criteria one week quicker than in the normal physiotherapy community. This report describes the effects of early rehabilitation before surgery for Sub-trochanteric fracture. So the Main Goal is educating and recovery of patients and prevents secondary complications. Patient motivation and goal-oriented therapy were beneficial in regaining baseline functional mobility.

Keywords: Sub-trochanteric fractures, road traffic accident, case report, rehabilitation.

1. INTRODUCTION

Sub-trochanteric fractures are proximal femoral neck fractures that occur allaying the lesser trochanter and 5cm distally, this can happen in mechanisms with lower frequency (elderly) or high intensity (young individuals). The overall prevalence rate of neck of femoral fractures are predicted to be almost 230 per hundred thousand patients, with about 10% of these fractures occurring in the Sub-trochanteric region (Jackson et al., 2018). Sub-trochanteric

fractures contribute to around seven to thirty-four percent of all femoral fractures (Medda et al., 2022). Females are reported to be at a larger risk for sub-trochanteric fractures than males, with an incidence rate of up to 33 percent higher. The majority of these fractures affect the elderly, with 1-year death rates ranging from 14 to 36 percent. Younger individuals' fractures are more likely to be caused by high-energy trauma and have considerable comminution, whereas elderly patients' fractures are most likely to be triggered by low-energy traumas (Coon and Best, 2022). Because of the group of muscles surrounding it, the femur's subtrochanteric region is the most leg's stressful region. Whenever a fracture occurs in the sub-trochanteric section of the femur, it is common to see dislocation, particularly external rotation of the proximal region (Wang et al., 2016).

For different forms of proximal femoral fractures, alternative treatment approaches are required, depending on a range of factors such as the fracture's site, morphologic characteristics, injury cause, stability, and the patient's age and initial functional status. Sub-trochanteric fractures often necessitate a multidisciplinary approach that involves appropriate surgical fixing, early ambulation and rehabilitation to reclaim functional status (Sheehan et al., 2015). Biomechanical and anatomical factors that are specific to ST fracture complicate therapy. On the proximal femur large muscles enter and provide substantial deforming stresses around the fracture, making it difficult to repair the fracture. The gluteus minimus and medius are powerful hip abductors that attach to the greater trochanter. The piriformis, gemellus inferior, and gemellus superior are all external hip rotators that are also inserted in this location. The iliopsoas is a muscle that attaches on the trochanter (lesser) and allows the hip to do flexion and rotate externally. The deformities exhibited in these fractures are due to these muscles. The distal segment shortens and is adducted with the help of adductor muscles and hamstring while the proximal fragment gets flexed, externally rotated and abducted. Unlike many fractures, it can be minimized by aligning the distal segment with the immobile proximal fragment, these fractures require movement of both segments since the distal segment cannot be aligned with the proximal fragment sufficiently on its own. Regardless of the fixing approaches chosen, this understanding is essential for establishing satisfactory alignment (Shah and Bordoni, 2022).

In this area, the compressive force of the body's weight, and also additional forces created by muscles intruding against the fracture pieces, cause significant mechanical stresses. Various investigations have been done for these forces. The maximum compressive femur strains are found 1 to 3 inches beneath the trochanter (lesser) on the medial cortex, which can reach the density, which is 1,200 pounds each square inch, which is the most overstressed area in the body. At the lesser trochanter (lateral cortex), tensile stresses are reduced by about 25%. The cortical bone in the sub-trochanteric portion of the femur heals more slowly and is more likely to have communicated fracture hence, for this kind of fractures initially traction is applied and later a variety of internal fixing techniques, including plate-screw systems and intramedullary nails. However, the intramedullary nail is in demand. So the main goal is educating and recovery of patients and prevention of secondary complications.

2. PATIENT AND OBSERVATION

Patient Information

A 43-year-old male resident of Wardha district (Maharashtra) and is a farmer by occupation with the dominance of the right side. The patient met with an RTA on 1st Jan 2022 while traveling home which resulted in pain and swelling over the right thigh region. After that, the patient was taken to the private hospital by the people nearby and relatives and got admitted to Girard's private hospital for 2 days. After that, he visited Lodha hospital in hinganghat and was referred to AVBRH on 3 Jan 2022. In AVBRH he got admitted to the orthopedic department for 11 days. There was no history of head injury and vomiting at the site of the accident. The pain was gradual in onset and progressive in nature, on NPRS pain was 8, aggravating factors were sitting, standing, walking and other similar physical activities and pain was relieved at rest. Also patient has a disability certificate which he showed after assessment in which it was mentioned that he is a case of locomotor disability and a diagnosed case of mono paresis right lower limb with FFD. He has 43 per cent permanent disability in relation to his part of the body as per guidelines. The patient gives a history of bilateral hydrocele for which he was operated on 2 years back.

Patient has no suffering of hypertension, diabetes, asthma, or hypo/hyperthyroidism. After which on 16 Jan 2022 patient underwent lab investigations and it was seen that the value of Hb was 8.6 gm/dl which was not optimum for surgical management and after a few days he was managed with medications, again Hb values were taken on 24 Jan 2022 which was 12 gm/dl and hence operative procedure was planned on 29 Jan 2022 which was open reduction, as well as internal fixing with encirclage wire with the modular cemented femoral stem of size 250 mm, was inserted with bone cement-filled up to proximal fragment and acetabular cup of size 44mm was inserted for subtrochanteric femur fracture of the right side. On the same day, Skin Traction was applied with 2 kgs of weight which is shown in figure no 1. Following which physiotherapeutic rehabilitation started.

Medication history

Inj. Tramadol 50 mg in 100 ml NS IV twice daily, Inj. Ondensteron 4 mg IV, Inj. Pan 40 mg IV – once daily, Tab. vitamin C – 500 mg twice daily.

3. CLINICAL FINDINGS

A physical examination was performed after the patient's consent. The patient was awake, cooperative, and well-oriented in terms of time, location, and person during the general examination. Pre-operative on observation there was localized swelling, tenderness was grade 1, hip range of motion was measured which has been shown below in (Table 1), and manual muscle testing and limb length measurement were not assessable due to the presence of Thomas splint on the affected side which is showed in figure 2. But visible limb shortening was noticeable. Outcome measures were taken pre and post operatively which are noted below in (Table 2).

Table 1 Table showing a range of motion on day 1 of rehabilitation and day 15 rehabilitation pre-operative and post-operative

		Pre-Op Day 1				Pre-Op Day 15				Post-Op Day 15			
		Right		Left		Right		Left		Right		Left	
Joint		Act	Pass	Act	Pass	Act	Pass	Act	Pass	Act	Pass	Act	Pass
Hip	Flexion	NA	NA	110	120	NA	NA	120	120	90	110	120	120
	Abduction	NA	NA	45	45	NA	NA	45	45	35	40	45	45
	Adduction	NA	NA	25	30	NA	NA	30	45	25	25	30	30
	Extension	NA	NA	NA	NA	NA	NA	NA	NA	25	30	30	30
Knee	Flexion	NA	NA	120	120	NA	NA	NA	NA	110	120	120	120
	Extension	NA	NA	120	120	NA	NA	NA	NA	110	110	120	120
Ankle	Dorsiflexion	10	15	20	20	15	20	20	20	15	20	20	20
	Plantar flexion	35	40	50	50	40	40	50	50	45	50	50	50

Table 2 showing outcome measures pre and post operatively.

Outcome measure	Pre-operative	Post-operative
Harris hip score	21.2 – poor	75 – fair
LEFS(Lower extremity functional scale)	15	45
Berg balance scale	25	50

Timeline of Current Episode

3rd Jan 2022: Date of admission, Date of pre-op examination was 5th Jan 2022, X-ray of right leg was done on 3rd Jan 2022, Date of operation was 29th Jan 2022, and Post-operative physiotherapeutic intervention was started on POD-01 which is on 30th Jan 2022

Diagnostic assessment

X-Ray: The X-Ray showed the sub-trochanteric fracture with osteoarthritis of hip of right side. Fig 1 shows Pre-operative X-ray of right leg showing sub-trochanteric fracture with osteoarthritis of right hip (Figure 2). Where fig 3 showing Post-operative X-ray of right leg post-operative showing standard modular cemented Femoral Long Stem in which Acetabular Cup is used in Total hip replacement (Figure 4).

Doppler: Showed large intra-luminal thrombus. Subcutaneous edema is seen in the right leg multiple small right inguinal adenopathy with, DVT of right leg.

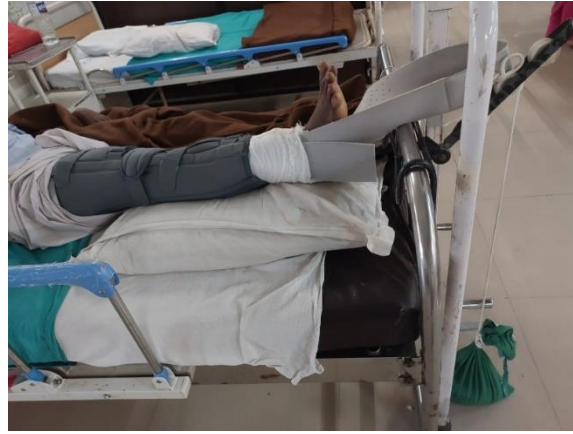

Figure 1 Post-operative picture showing presence of long knee brace with skin traction.

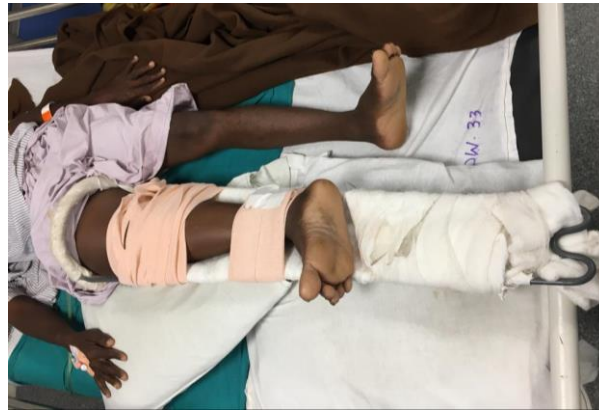

Figure 2 Pre-operative pic showing presence of Thomas splint on affected leg which is internally rotated.

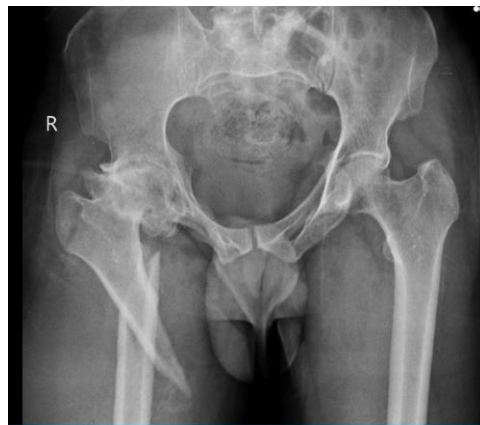

Figure 3 Pre-operative X-ray of both right leg showing sub-trochanteric fracture with osteoarthritis of right hip.

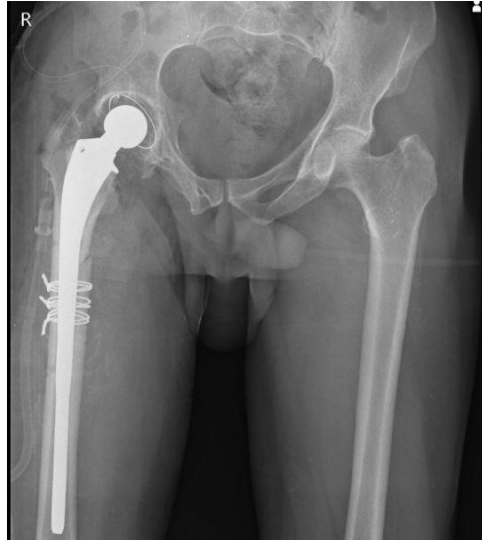

Figure 4 Post-operative X-ray of right leg post-operative showing standard modular cemented Femoral Long Stem in which Acetabular Cup is used in Total hip replacement.

Diagnosis

The findings are following sub-trochanteric fracture of right side with osteoarthritis of hip on the same side, planned for THR.

Therapeutic intervention

Goals

To restore full orthopedic functional range of motion in the hip joint

To restore adequate strength, power, and endurance to the muscle groups surrounding the hip and knee

Restore normal range of motion at knee and ankle joint if not normal, at least the functional ROM, up to 110° at hip and knee, dorsiflexion of the ankle up to 0-10°, and ankle plantar flexion up to 0-20°.

Improve power, strength, and endurance of the muscles around the foot, also inverters and dorsiflexors.

Phase one

The important goals are patient education and secondary complication prevention and are the first steps in the recovery process. The patient was given information on his condition, including dos and don'ts, as well as the need of physiotherapy. To decrease oedema, the patient was instructed to keep the limb elevated. Functional active exercises of the upper limb were taught. Static exercises for quadriceps, hamstrings, and glutes were explained to avoid disuse atrophy. Also, mobility exercises for the unaffected limb were taught. Adequate chest physiotherapy was given to avoid respiratory complications.

Phase two

The goal of the second phase of rehabilitation was to preserve the range of motion and strength gained in the first phase while still making improvements in the strength aspect. Initiate sitting on the bed at the earliest with a back support at the beginning. For the maintenance of good strength, the patient was asked to continue isometrics. Also, the patient was asked to do the heel slides, SLR, and repeat every 10 times at least 3 sets. For the Upper limb, resisted exercise was given so that upper extremity strength using Delorme's technique 10 RM was identified and was given as tolerated by the patient. It was given through a 1/2 litre water bottle.

Phase 3

For increasing the strength in the lower extremity on the good side, the patient was asked to perform the resisted exercise and it was given using a yellow Thera band for 10 repetitions with 5-10 sec holds as per tolerated. And as above static hams, quads and glutes were performed by increasing the holding time, also straight leg raise and upper limb resisted exercise were continued with a 1-litre water bottle.

Precautions

No adduction and abduction of the hip of the affected side. No isometrics exercise to quads and hamstrings of the affected side.

Be watchful for signs of thromboembolism, pulmonary embolism, or hypovolemia. Avoid torsional forces on fracture site.

Phase 4

Started with passive range of movements to the operated leg making it assistive, heel drag technique taught providing only the required passive assistance. CPM controlled passive motion apparatus was used in pain-free range– hip and knee relaxed passive flexion and extension. Hip flexion should be attaining to 90 degrees by self-assistive hip flexion in supine lying position or at bedside sitting. Sitting and transferring with legs hanging on the bed’s edge can be made self-assistive, in which the patient supports the operated leg with another leg. Assisted abduction can be initiated by sling suspension or by the self-assisted method. Self-assisted SLR should be started as early as possible. Knee swinging sitting at the edge of the bed can be made resistive either by a self-resistance technique using the normal leg or by graded resisted exercise using weight belts or DeLorme shoe. Basic pre-operative physical therapy rehabilitation protocol is mentioned in Table 3. Further progression is given in the flow chart below (fig 5) and the Post-op treatment is explained below in the (Table 4) with rationale of basic exercise which was taught to patient.

Table 3 Table showing pre-operative Physical Therapy Rehabilitation Protocol with its rationale

Sr.no	Goals	Intervention	Plan of care	Rationale
1	Patient education	1-Educate patient about his condition and teach possible precautions. 2-Educating the importance of physiotherapy.	Hand outs and verbal instructions.	It helps to improve treatment effectiveness and increases the patient’s dedication towards the treatment.
2	Reduce swelling in lower limb	Ankle toe movements Elevation of the limb. (Both Rt and Lt lower limb)	-15 reps × 3 set - every 2 hourly.	It increases lymphatic drainage.
3	Reduce pain	Hot fermentation	Before exercise.	It helps to improve blood supply and helps to restore movements
4	Prevention of secondary complications	Ankle toe movements To prevent DVT(deep vein thrombosis)	-15 rep × 3 sets – every 2 hourly	It significantly increases calf pump function as it reduce venous stasis and risk of thromboembolism
5	To prevent disuse atrophy in lower limb muscles	1-Static to hamstrings, 2- Static to quadriceps 3- Static to glutes. 4- Heel slides 5- SLR (to Lt leg)	-10 rep × 3 set -10 rep × 3 set -10 rep × 3 set -10 rep × 3 set	Isometric contraction helps in inhibition pain and stimulates healing process.
6	To maintain ROM of upper limb joints.	1-Shoulder–flexion, extension, abduction and adduction 2-Elbow–flexion, extension 3-Wrist - flexion, extension	-10 rep × 3 set -10 rep × 3 set -10 rep × 3 set	

6	To increase muscle strength of upper and lower limb.	<p>1- For upper limb – initially ½ litter water bottle and then progressed to 1 litter (set according to DeLorme’s technique by setting 10 RM according to patients capacity)</p> <p>2- For lower limb – using yellow theraband initially (to affected leg)</p> <p>3 -Isometrics to hamstrings Isometrics to quadriceps</p> <p>Isometrics to glutes (to unaffected leg)</p>	<p>-10 rep × 3 set with 10 sec hold</p> <p>-10 rep × 3 set with 10 sec hold.</p> <p>-10 rep × 3 set with 10 sec hold</p> <p>-10 rep × 3 set with 10 sec hold</p> <p>-10 rep × 3 set with 10 sec hold</p>	Facilitate muscle firing to begin to re-establish neuromuscular control but protect healing tissues.
---	--	---	--	--

Table 4 Table showing post-operative Physical Therapy Rehabilitation Protocol with its rationale

Sr no	Goals	Intervention	Plan of care	Rationale
1	Patient education	<p>1-Educate patient about his present condition post operatively and teach possible precautions.</p> <p>2-Educating importance of physiotherapy post operatively.</p>	Handouts and verbal instructions.	To increase patient’s knowledge about their condition so they can take proper precautions and self-care so that it increases treatment effectiveness and increases the patient’s dedications towards the treatment.
2	Reduce swelling in lower limb	<p>Ankle toe movements</p> <p>Finger toe movements</p> <p>Elevation of the limb. (both Rt and Lt limb)</p>	<p>-10 rep × 3 set –every2 hourly.</p> <p>- 10 rep × 3 set – every 2 hourly</p> <p>- 10 rep × 3 set – every 2 hourly</p>	It increases lymphatic drainage
3	Reduce pain	Hot fermentation	Before exercise.	It helps to improve blood supply and helps to restore movements
4	Prevention of secondary complications	<p>Ankle toe movements</p> <p>To prevent DVT(deep vein thrombosis) (both Rt and Lt limb)</p>	-10 rep × 3 sets – every 2 hourly	It significantly increases calf pump function as it reduce venous stasis and risk of thromboembolism
5	To prevent disuse atrophy in lower limb muscles	<p>1-Static to hamstrings,</p> <p>2- Static to quadriceps</p> <p>3- Static to gluteus.</p> <p>4- Heel slides</p> <p>5- SLR – self assisted (to both Rt and Lt limb)</p>	<p>-10 rep × 3 set</p> <p>-10 rep × 3 set</p> <p>-10 rep × 3 set</p> <p>-10 rep × 3 set</p> <p>-10 rep × 3 set</p>	Isometric contraction helps in inhibition pain and stimulates healing process.
6	To maintain ROM of upper limb and lower limb joints.	<p>1-Shoulder–flexion, extension, abduction and adduction</p> <p>2-Elbow–flexion, extension</p> <p>3-Wrist - flexion, extension</p>	<p>-10 rep × 3 set</p> <p>-10 rep × 3 set</p>	It maintains the muscle length.

		4 – Hip – flexion , abduction	-10 rep × 3 set	
7	To increase muscle strength of upper and lower limb.	1- For upper limb – initially 1 litter water bottle and then progressed to yellow and then to blue theraband 2- For lower limb – using blue theraband initially (to affected leg) or knee swinging at edge of bed by giving self-resistance by sound leg . 3 -Isometrics to hamstrings Isometrics to quadriceps Isometrics to gluteus (to both the leg) 4 – stretching for tendoachilis and hamstring 4 – self assistive heel drag technique is taught with passive assistance 5 – continuous passive motion (CPM) apparatus	-10 rep × 3 set with 10 sec hold -10 rep × 3 set with 10 sec hold. -10 rep × 3 set with 10 sec hold -10 rep × 3 set with 10 sec hold -10 rep × 3 set with 10-sec hold -5 rep with 15-sec hold	Facilitate muscle firing to begin to re-establish neuromuscular control but protect healing tissues.

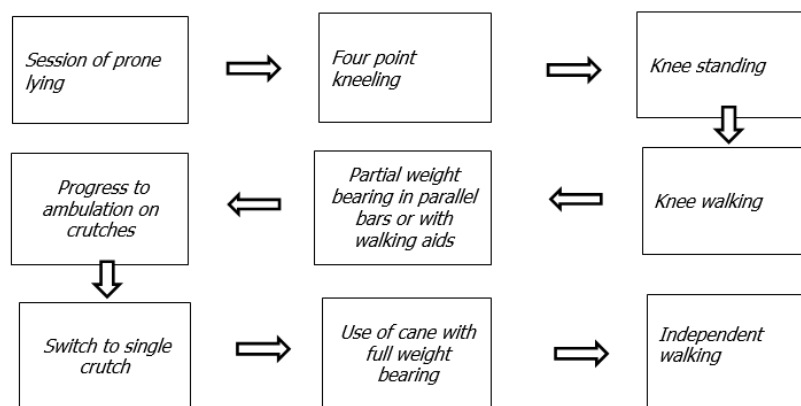


Figure 5 progression to phase 4

Post-operative precautions

As limb shortening was noticed while examination, it wasn't achievable in surgery to correct it so special footwear were advised to patient for limb length correction so patient does not have difficulty in walking and hence reduced risk of fall .As patient had 3 cm of shortening so he was advised to wear 4cm wedge footwear to correct and match the height to opposite limb.

Patient has natural tendency to keep legs adducted so to prevent it patient is asked to keep pillow between two legs i.e. hip abducted so fracture can be easily fixed.

Limp in gait should not be allowed to get organize. Repetitive sessions of self-resisted exercise, gait training with correct comfortable footwear and home practice in front of postural mirror is ideal .

Prevent fracture susceptible tendencies such as excessive tendency to bring affected limb into adduction and internal rotation

while walking.

4. DISCUSSION

Jackson et al., (2018) conducted research in which they delineated that approximately Individuals over the age of 50 account for 2/3 of all Sub-trochanteric fractures, with the remaining 25 percent occurring in patients with age 17 to 50. Craig et al., (2005) conducted a study which delineated that females are prone at higher risk of sub-trochanteric femur fractures than males, with an incidence rate up to 33% higher where Medda et al., (2022) reveals that ST fracture are sustained equally between males and females. Elderly patients with sub-trochanteric femur fractures have a one-year death rate of 25%.

Craig et al., (2005) in a study found that in 56 percent of patients, conservative therapy yields satisfactory results, compared to 70–80 percent for operational techniques. Conservative management is secure, with a less grade of non-unionization. It is especially useful in areas with little resources, in individuals which are unable to undergo surgery, and in children. Wang et al., (2016) while in a study found that because of the group of surrounding muscles, the sub-trochanteric portion of the femur is the lower limbs most stressful region. When a fracture occurs in the sub-trochanteric part of the femur, it is common to find displacement; in external rotation of the proximal segment. Most surgeons recommend using internal fixation methods, such as plate-screw systems and intramedullary nails, for this kind of fractures.

Lee et al., (2020) when compared to their non-fractured limb, patients lose more than half of their fractured limb muscular strength in the first few weeks after surgery; those with trochanteric fractures lose the most relative strength. However, several studies have backed intense physical treatment in initial phase, claiming that it enhances recovery when compared to delayed physical therapy.

5. CONCLUSION

The importance of pre rehabilitation before surgery of Sub-trochanteric fracture with patient motivation and goal-oriented therapy was beneficial in regaining baseline functional mobility which was helpful to strengthen and recover to previous functional flexibility, in our case study, it is seen that early rehabilitation and in-bed exercises has helped patient to maintain good strength of the unaffected limb which will help him for early mobility and get back to the normal routine activities as physiotherapy conservative treatment was used, including stretching exercises, breathing exercises, bed mobility exercises and strengthening exercises. Furthermore, patients in the acute phase of hospitalization who received a high-intensity physiotherapy program (3 sessions every day) met discharge criteria ten days sooner than the normal physiotherapy group (1 session every day) and which were found to be effective which helped patient in post-operative phase of rehabilitation to gain early mobility.

Patient Perspective

I had the physiotherapy rehabilitation, which helped me to improve my confidence towards my daily activities before surgery, which will help me to regain my strength after surgery.

Informed consent

Written and oral informed consent was obtained from all individual participants included in the study. Additional informed consent was obtained from all individual participants for whom identifying information is included in this manuscript.

Acknowledgment

We thank our patient and their caregivers for their support during treatment sessions.

Author's contributions

Our every author contributed equally in this case report.

Abbreviations

NA – not assessable

Rep – repetitions

Rt – right

Lt – left

RTA – road traffic accident

DVT- deep vein thrombosis

SLR- straight leg raise

Funding

This study has not received any external funding.

Conflicts of interest

The authors declare that there are no conflicts of interests.

Data and materials availability

All data associated with this study are present in the paper.

REFERENCES AND NOTES

1. Coon MS, Best BJ. Distal Femur Fractures, in: StatPearls. StatPearls Publishing, Treasure Island (FL). 2022.
2. Craig NJ, Craig N. Subtrochanteric fractures: current management options. *Disabil Rehabil* 2005; 27(18-19):1181-90. doi: 10.1080/09638280500055545. PMID: 16278187
3. Jackson C, Tanios M, Ebraheim N. Management of Subtrochanteric Proximal Femur Fractures: A Review of Recent Literature. *Adv Orthop* 2018; e1326701. doi.org/10.1155/2018/1326701
4. Lee KJ, Um SH, Kim YH. Postoperative Rehabilitation after Hip Fracture: A Literature Review. *Hip Pelvis* 2020; 32, 125–131. doi.org/10.5371/hp.2020.32.3.125
5. Medda S, Reeves RA, Pilson H. Subtrochanteric Femur Fractures, in: StatPearls. StatPearls Publishing, Treasure Island (FL) 2022.
6. Shah A, Bordoni B. Anatomy, Bony Pelvis and Lower Limb, Gluteus Medius Muscle, in: StatPearls. StatPearls Publishing, Treasure Island (FL) 2022.
7. Sheehan SE, Shyu JY, Weaver MJ, Sodickson AD, Khurana B. Proximal Femoral Fractures: What the Orthopedic Surgeon Wants to Know. *Radio Graphics* 2015; 35, 1563–1584. doi.org/10.1148/rg.2015140301
8. Wang P, Ren D, Song C, Zhou B. Surgical Technique for Subtrochanteric Fracture of Femur. *Orthop Surg* 2016; 8, 516–518. doi.org/10.1111/os.12291