

Impact of multidisciplinary approach in managing pott spine - A case report

Madhu Lakhwani^{1*}, Anushka Raipure², Nikita Seth³, Pratik Phansopkar⁴

To Cite:

Lakhwani M, Raipure A, Seth N, Phansopkar P. Impact of multidisciplinary approach in managing pott spine - A case report. *Medical Science*, 2022, 26, ms180e2192. doi: <https://doi.org/10.54905/disssi/v26i123/ms180e2192>

Authors' Affiliation:

¹Resident, Department of Musculoskeletal Physiotherapy, Ravi Nair Physiotherapy College, Datta Meghe Institute of Medical Sciences, Wardha, Maharashtra, India.

Email: madhu.lakhwani@dmimsu.edu.in

Orcid id: <https://orcid.org/0000-0003-3039-4736>

²Ravi Nair Physiotherapy College, Datta Meghe Institute of Medical Sciences, Wardha, Maharashtra, India.

Email: asraipure9@gmail.com

Orcid id: <https://orcid.org/0000-0002-4759-1579>

³Intern, Ravi Nair Physiotherapy College, Datta Meghe Institute of Medical Sciences, Wardha, Maharashtra, India.

Email - nikitasheth1999@gmail.com

⁴Associate Professor & HOD, Department of Musculoskeletal Physiotherapy Department, Ravi Nair Physiotherapy College, Sawangi (Meghe), Wardha-442004, India.

Email: drpratik77@gmail.com

Orcid id: <https://orcid.org/0000-0003-3635-8840>

*Corresponding Author

Resident, Department of Musculoskeletal Physiotherapy, Ravi Nair Physiotherapy College, Datta Meghe Institute of Medical Sciences, Wardha, Maharashtra, India.

Email: madhu.lakhwani@dmimsu.edu.in

Orcid id: <https://orcid.org/0000-0003-3039-4736>

Peer-Review History

Received: 26 March 2022

Reviewed & Revised: 28/March/2022 to 14/May/2022

Accepted: 15 May 2022

Published: 18 May 2022

Peer-review Method

External peer-review was done through double-blind method.

URL: <https://www.discoveryjournals.org/medicalscience>



This work is licensed under a Creative Commons Attribution 4.0 International License.



Copyright © 2022 Discovery Scientific Society.

ABSTRACT

In approximately 40 to 50 % of tuberculosis cases, Pott's spine is the commonest musculoskeletal manifestation. Impoverished nutrition, addiction, the introduction of drug-resistant tuberculosis strains, ineffective tuberculosis control efforts, overcrowding, and increased migration appear to be contributing factors to the global increase in TB incidence. In humans, the earliest recorded infectious disease is spinal tuberculosis that has the potential for significant morbidity. Severe deformities along with neurologic impairments are frequently found in spinal tuberculosis. It usually results in angular kyphotic deformity and anterior wedging by damaging the disc space between two vertebrae and also damaging the bodies of the neighboring vertebrae. In this paper, we describe a case of a 36-year-old male who had low back pain and loss of sensation, and bilateral weakness in the lower extremities. On further investigations, the patient was diagnosed with Tuberculosis infecting the spine and was on anti-tubercular medications. Due to increased severity of symptoms patient was planned for D9 Costo transversotomy with D9 corpectomy with pedicle screw and rod fusion at D8-D10 and decompression surgery for the lumbar spine. So along with it, the patient was given planned goal-oriented physiotherapy pre and post-operatively which was found to be highly beneficial for the patient and improved functional independence and quality of life. The outcome measure used was the lower limb functional Scale.

Keywords: Pott's spine, Physical Rehabilitation, TB spine, Low Back Pain.

1. INTRODUCTION

Tuberculosis has been one of the earliest documented infectious diseases in humans. Tuberculosis is still the most prevalent infectious illness worldwide and the most common structure to be involved in extrapulmonary TB is the spine. Although the exact frequency of spinal tuberculosis is unknown, extrapulmonary tuberculosis is identified in 20% of infected people. Skeletal TB is seen in approximately 10% of individuals with the active pulmonary illness. In 10-50% of cases, a neurological impairment develops (Garg and Somvanshi, 2011). The first to describe spinal tuberculosis disease was Percival Pott hence, this disease is also known as Potts disease. Spinal tuberculosis has the potential for significant morbidities, such as persistent

neurologic impairments and severe deformities. The 1st symptom to occur may be the lung or GI pathology which is the commonest cause of Spinal Tb. Typically, there is the involvement of two contiguous vertebrae; however multiple can be impacted, as well as skip lesions and solitary involvement is seen. In 4-10% of instances, a second visible lesion that is not contiguous with the first visible lesion is called a skip lesion (Viswanathan and Subramanian, 2021).

The lumbar region including the lower thoracic vertebrae is usually affected with mild involvement of the mid thorax and cervical area. Normal (paradiscal) vertebral involvement might include the centrum or posterior components while preserving the intervertebral discs (Gala and Aswani, 2016). The most prevalent changes are the wedging of vertebrae anteriorly and resulting in a kyphotic deformity be it knuckle or a Gibbus which is typically due to reduction in the joint space of intervertebral disc and damaged vertebral bodies by spinal TB. The global increase in TB incidence appears to be caused by the HIV epidemic, poor nutrition, drug addiction, alcoholism, the emergence of drug-resistant tuberculosis strains, inefficient tuberculosis control efforts, overcrowding, and increasing migration (Agrawal et al., 2010). Globally, 10.7 million individuals are afflicted with HIV and tuberculosis (TB). The most common clinical indications of spinal TB are bony involvement (vertebral) disease or combined osseous and nonosseous involvement of the spine and hence the name Pott’s Spine (Danaviah et al., 2013).

2. PATIENT INFORMATION

A 35 yr old male, resident of Amravati, and farmer by occupation visited AVBRH with the prime complaints of low back pain along with numbness in both lower limbs. According to the patient, he was seemingly alright about 6 months back when he first started experiencing ache on the right side of the mid-portion of the back. The pain was insidious in onset and progressive in nature. He gives a history of bilateral weakness and loss of sensation in the legs for 3 months. He also gives a history of fever evening rise, one episode per day for 2.5 months. He is bedridden for 2-2.5 months. He gives a history of loss of strength in his muscles for 2 months. The patient also had a history of reduced overall appetite and weight loss for 15 days. He was an already diagnosed case of spinal tuberculosis for 2 months and is on anti-tubercular drug therapy (Rifampicin-Isoniazid-Pyrazinamide-Ethambutol). He gives no history of cough, breathlessness, or chest pain. He neither gives a history of bowel or bladder complaints nor any history of associated illness of diabetes mellitus, hypertension, and bronchial asthma. He also gave a history of frequent smoking, tobacco, and consumption of alcohol.

3. CLINICAL FINDINGS

On examination, the patient was supine lying, with the moderate general condition and afebrile with blood pressure 110/70 mmHg and a heart rate of 84 beats per minute. The Gibbus was seen in the midline of the dorsolumbar region where tenderness was also present. The patient was conscious, attentive, and well oriented. Heart and lung sounds were normal. There was tenderness over the midline at the dorsolumbar region where a Gibbus was also noted. On manual muscle testing, the power was 0/5 in hip flexors, knee extensors, plantar flexors, and long toe flexors. Table 4 shows findings of manual muscle testing (MMT) pre and post-rehabilitation. Lumbar and sacral nerve roots were tested and the findings are depicted in table 1.

Table 1 Nerve root testing of lumbar and sacral nerves

Nerve Root	Positive Findings	Present or Absent
L1 Nerve	There is pain and sensory loss in the inguinal area. Weakness in the Hips may be present	Present
L2-L3-L4 Nerve	Back pain radiates to the anterior view of the thigh and the medial region of the lower leg. Hip adduction and hip flexion weakness and decreased patellar reflex	Present

L5 Nerve	Back pain along with pain which radiated to the buttocks, lateral aspect of the thigh, and calf along with the dorsum foot, great toe. There is loss of sensations on the lateral aspect of the calf, and dorsum of the foot. Weakness is also seen in performing abduction of the hip, flexing the knee, dorsiflexion of the foot, the extension of the toe, foot inversion, and eversion is decreased.	Present
S1 Nerve	Back pain radiating to the buttocks, plantar, or laterally to the foot. Sensory loss on the posterior calf, There is marked weakness in extending the hip, flexing the knee, and also foot plantarflexion.	Present but without Bladder involvement
S2 –S4 Nerves	Sacral and Buttock pain that radiates towards the posterior view of the leg, the sensory deficit on medial buttocks, absent Bulbocavernous Reflex	Absent

Diagnostic Assessment

MRI of the lumbar spine reveals that the height and signal intensity of the vertebral bodies and intervertebral discs are normal. Diffuse disc bulges at L3 to L5 level, moderately compromising bilateral neural canals, traversing 3rd and 4th Lumbar nerve roots. On the level of the Fifth lumbar and 1st sacral region, the disc bulges diffusely moderately comprising the right, mildly compromising the left neural canal. An X-ray was also performed which revealed no air entry into the left lung. Dorsal spinal MRI shows T1 hypotense and T2 isotense signal changes in D8, D9, and D10 vertebral bodies with pre-paravertebral abscess. The Intervertebral disc between D8/9 is lost. Epidural abscess indents the spinal cord. Features suggest symptoms of Pott’s spine. Mild degenerative alterations were observed in the lumbar spine. HRCT THORAX revealed evidence of lytic destruction noted in the body of T8, T9 vertebrae with surrounding bilateral paravertebral soft tissue density collection extending from T7 to T11 vertebrae. The left lower lobe had an area of patchy consolidation in the posterodorsal segment.

Timeline

The patient was admitted to the male ortho ward on 16th June 2021 and after necessary investigation and laboratory findings the patient was planned for the surgery, so on 21st June patient underwent for D9 Costo transversectomy with D9 corpectomy with pedicle screw and rod fusion at D8-D10 and decompression surgery for the lumbar spine. On a post-operative day-3, the patient was referred for physiotherapy. Table 2 depicts the timeline from the date of admission to the date of discharge.

Table 2 Timeline of the patient

Date of admission	16/06/2021
Date of assessment	17/06/2021
Date of surgery	21/06/2021
Date of commencement physiotherapy rehabilitation	25/06/2021
Date of discharge	25/06/2021

Therapeutic Intervention

The physiotherapy intervention for the patient was carried out in phases namely Acute, Subacute, and Chronic phase. Detailed phase-wise intervention is depicted in table 3.

Table 3 Physiotherapy interventions

Physiotherapy Rehabilitation Protocol		
Phase of Rehabilitation	Goals	Intervention and Dosage
Phase 1 Acute phase	Patient Education	Educating the patient about the condition and the importance of physiotherapy to increase the patient's adherence to the exercises.
	To maintain the Muscle strength	Isometric contractions of cervical, thoracic, lumbar, and all lower extremity joints, with specific emphasis on hip flexors, knee extensors, plantar flexors, and long toe flexors with 10-sec hold for 5 repetitions. Figure 1 shows strengthening exercises for the upper limb.
	Maintain good ventilation	Deep breathing exercises, Pursed lip breathing 10 repetitions (2 sets) Figure no. 2 shows the patient performing breathing exercises. Hourly cycles of active breathing techniques (ACBT) (2 hourly)
	Proper patient positioning to avoid further complications	The foot was kept in a neutral position, and the torso and extremities were properly aligned. Every two-hourly positioning was done to prevent pressure ulcers and was periodically inspected for erythema development.
	To prevent secondary complications	30–100 feet of wheelchair propulsion utilizing both upper and lower limbs, weight shifting in a standing frame, and With AFOs on, she was moved 4-6 footsteps forward and backward on the parallel bars.
Phase 2 (Sub-acute Phase)	Pre Ambulatory Training	Standing knee bends lateral weight shifts- one set of ten repetitions. Ambulation in parallel bars with bilateral AFOs and PT support as needed to block knees.
	To maintain range of motion	Active assisted exercises including Straight leg raise, (Figure 3 shows the patient performing active-assisted SLR) tightening the hip flexors and lumbar extensors, and raising both quadriceps 20 cm off the ground were all suggested, as well as sitting at the margin of the bed (supported or unsupported)
	Ambulatory training	The patient was advised to walk under supervision using a walker with adequate rest periods for a minimum of 3 times a day. Progression was done with 200 feet with the help of wearing AFOs.
Phase3 (Chronic Phase)	To improve the strength of core muscles	McKenzie and Cat–Camel posture exercises were administered.
	Ameoliorating the patient's Quality of Life (QOL)	Improving the functional independence of the patient.

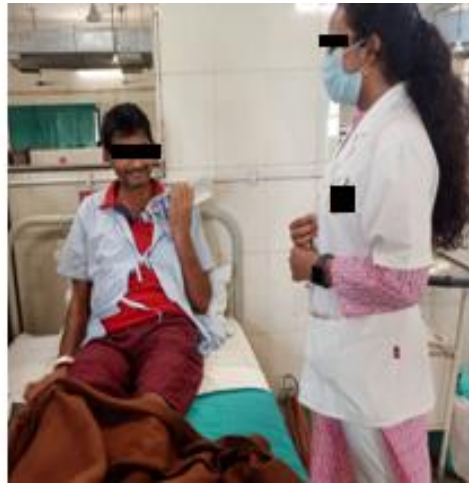

Figure 1 The patient is performing upper limb strengthening exercises.

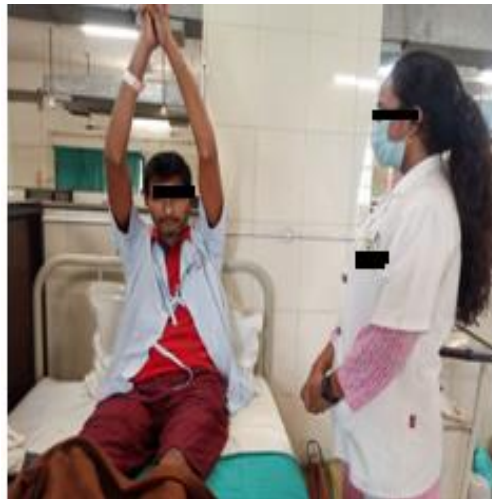

Figure 2 Breathing exercises are performed by the patient for maintaining good ventilation.

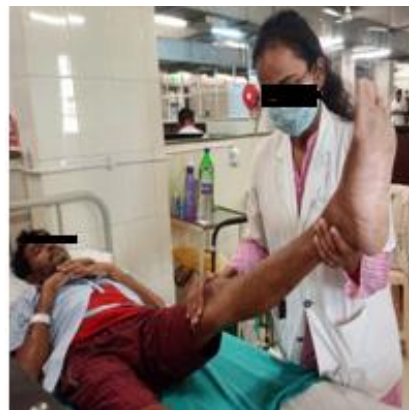

Figure 3 Active-assisted SLR is being performed on the patient.

Follow-up and outcome measures

After completion of the rehabilitation protocol, the patient was asked for a follow-up. Physical examination was performed again and no complaints were reported by the patient. By the end of 3 months, the patient reported a full and relatively less painful range of motion. The strength was assessed using Medical Research Council Grading System. Table 4 shows the findings of manual muscle testing pre and post-rehabilitation.

Table 4 Findings of Manual Muscle Testing (MMT) pre and post-rehabilitation

MMT	Pre Rehabilitation	Post Rehabilitation
Hip flexors	0/5	4/5
Knee extensors	0/5	4/5
Plantar flexors	0/5	4/5
Long toe flexors	0/5	4/5

A Lower Extremity functional Scale consisting of 20 domains with a maximum possible score of 4 and a minimum score of 0 in each domain was used to assess the pre and post-operative outcome of physiotherapy. Chart 1 shows the findings of the Lower Extremity Functional Scale pre and post-rehabilitation.

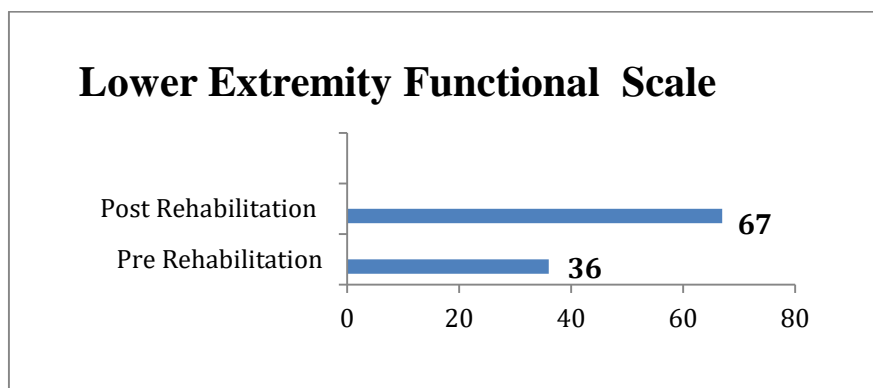


Chart 1 shows findings of the Lower Extremity Functional Scale pre and post-rehabilitation.

4. DISCUSSION

Tuberculous spondylodiscitis, often known as Pott's disease, is an infection of the intervertebral discs of the neighboring vertebrae. TB begins in the lung but can spread to any organ or tissue in the body. The most commonly afflicted extra-pulmonary location is the spinal column. While tuberculosis is an ancient illness, it continues to have a global effect, with 9 million new cases reported each year and 2 million fatalities reported each year. Intervertebral disc sparing is the characteristic sign which distinguishes spinal TB from pyogenic osteomyelitis. Because mycobacteria lack the proteolytic enzymes seen in bacteria that cause pyogenic osteomyelitis, the disc may be relatively safe (Pigrau-Serrallach and Rodríguez-Pardo, 2013).

The hampered blood supply to the discs may prevent them from functioning as an initial source of infection, and it's been suggested that disc death happens only when the two nearby vertebral bodies have been sufficiently compromised that perhaps the disc loses its adequate nutrition. The occurrence of paravertebral abscesses is another sign of Pott's sickness (Urban and Roberts, 2003). Because of the fast growth of drug resistance to first-line therapy, conservative treatment alternatives such as anti-TB medicines have poor effectiveness in some individuals. Furthermore, the length of anti-TB chemotherapy continues to be a source of worry for both patients and clinicians, with some treatment regimens lasting up to 18 months. Modern surgical care for spinal tuberculosis includes debridement of affected vertebrae, repair of abnormalities, spine stability, and further spinal cord protection. An anterior technique is most commonly used to treat spinal tuberculosis in the cervical spine (Seung et al., 2015).

The treatment is multidisciplinary. Specific drugs, in all circumstances, necessitate rigorous bed rest or relative immobilization with a brace or collar, as well as a specialized rehabilitation regimen. The patient's age, infection site, illness stage, and physical and psychological health must all be considered throughout rehabilitation. Each stage of the illness process must be addressed by the program. The goal of the acute phase is to avoid neurological or decubitus problems. To restart an adaptive activity level as the illness progresses, increasing verticalization and independent rehabilitation are required (Rajkumar, 2020).

Physiotherapy aims to prevent decubitus issues, maintain articular, muscular, and respiratory functions, and improve transfers. The muscular strengthening of the extremity and the spine especially the cervical spine is connected to axial counter-resistance self-extension. The earliest possible diagnosis appears to be critical for reducing complications, reducing the need for surgical therapy, and hastening the recovery of excellent autonomy. Standard radiographs may be normal at this period. By detecting the site of the infection, whether single or many, MRI allows for early identification (Bukata et al., 2011).

Immobilizing the injured spinal section with a brace, cervical collar, or even absolute bed rest is indicated first. Surgery is only recommended for neurological or spinal postural concerns. It comprised laminectomy and posterior arthrodesis to fix the

anomalies, notably the local kyphosis. In light of enormous pottic abscesses and fistulated abscesses, several authors resorted to surgery. The dorsal and lumbar forms show the first immobilization in the bed. The formation of decubitus disorders, which might impair the prognosis, should be kept under close observation during the early stages. If there are severe neurological consequences, the specialized rehabilitation program is that of a patient with medullary damage, intending to achieve maximal autonomy based on residual functional capacities and the extent of the medullar lesion, as well as the full, incomplete, spastic, or flabby paraplegia (Tator, 1990).

5. CONCLUSION

A long history of proliferating back pain, constitutional symptoms, or pulmonary nodules on a chest radiograph, particularly in the upper lobes, may assist lead to a conclusive diagnosis. Early treatment of spinal tuberculosis can prevent lengthy examinations, therapeutic delays, and negative long-term results such as compression fractures with neurological impairments. TB spine is a condition that may need surgery to avoid or treat consequences. Rehabilitation is vital in the medical-surgical care of Pott's disease because it allows you to restrict or compensate for the limitations and handicaps associated with this condition. In developing countries, vertebral tuberculosis is still a common disease. Due to its tendency to cause bone degradation, spine deformity, and paraplegia or tetraplegia, the illness's consequences can be severe. As a result, for a favorable outcome, an early diagnosis and treatment plan are essential.

Acknowledgment

We thank the participant who contributed a sample to the study.

Author Contributions

M.L., A.R., N.S., and P.P. contributed to the implementation of the research, the analysis of the results, and the writing of the case report.

Informed consent

All individuals who took part in the study gave their written and oral informed consent.

Funding

This study has not received any external funding.

Conflicts of interest

The authors declare that there are no conflicts of interests.

Data and materials availability

All data associated with this study are present in the paper.

REFERENCES AND NOTES

1. Agrawal V, Patgaonkar PR, Nagariya SP. Tuberculosis of spine. *J Craniovertebr Junction Spine* 2010;74–85 doi: 10.4103/0974-8237.77671
2. Bukata SV, Digiovanni BF, Friedman SM, Hoyen H, Kates A, Kates SL, Mears SC, Mendelson DA, Serna FH, Jr Sieber FE, Tyler WK. A guide to improving the care of patients with fragility fractures. *Geriatr Orthop Surg Rehabil* 2011;5–37 doi: 10.1177/2151458510397504
3. Danaviah S, Sacks JA, Kumar KPS, Taylor LM, Fallows DA, Naicker T, Ndung'u T, Govender S, Kaplan G. Immunohistological characterization of spinal TB granulomas from HIV-negative and -positive patients. *Tuberc Edinb Scotl* 2013; 93:432–441 doi: 10.1016/j.tube.2013.02.009
4. Gala FB, Aswani Y. Imaging in spinal posterior epidural space lesions: A pictorial essay. *Indian J Radiol Imaging* 2016; 26:299–315 doi: 10.4103/0971-3026.190406
5. Garg RK, Somvanshi DS. Spinal tuberculosis: a review. *J Spinal Cord Med* 2011; 34: 440–454 doi: 10.1179/2045772311Y.0000000023
6. Pigrau-Serrallach C, Rodríguez-Pardo D. Bone and joint tuberculosis. *Eur Spine J Off Publ Eur Spine Soc Eur Spinal Deform Soc Eur Sect Cerv Spine Res Soc* 2013; 556–566 doi: 10.1007/s00586-012-2331-y

7. Rajkumar RP. COVID-19 and mental health: A review of the existing literature. *Asian J Psychiatr* 2020; 52:102066–102066 doi: 10.1016/j.ajp.2020.102066
8. Seung KJ, Keshavjee S, Rich ML. Multidrug-Resistant Tuberculosis and Extensively Drug-Resistant Tuberculosis. *Cold Spring Harb Perspect Med* 2015; a017863–a017863 doi: 10.1101/cshperspect.a017863
9. Tator CH. Acute management of spinal cord injury. *Br J Surg* 1990; 485–486 doi: 10.1002/bjs.1800770504
10. Urban JPG, Roberts S. Degeneration of the intervertebral disc. *Arthritis Res Ther* 2003; 120–130 doi: 10.1186/ar629
11. Viswanathan VK, Subramanian S. Pott Disease. StatPearls Publishing 2021