

Unusual Snake bite complications in a 70 year-old woman: A case Report

Fahad Khalid ALQuwaiay¹, Hessa Abdullah Alshammari¹, Abdulhafeez Osman Eltoum¹, Hani Abdulrahman Almutairi¹, Jaser Sultan Alshamari², Hussain Gadelkarim Ahmed^{3*}

To Cite:

ALQuwaiay FK, Alshammari HA, Eltoum AO, Almutairi HA, Alshamari JS, Ahmed HG. Unusual Snake bite complications in a 70 year-old woman: A case Report. Medical Science, 2022, 26, ms164e2263. doi: <https://doi.org/10.54905/disssi/v26i123/ms164e2263>

Authors' Affiliation:

¹Department of Medicine, King Khalid Hospital, Hail, Saudi Arabia

²College of Medicine, University of Ha'il, Ha'il, Saudi Arabia

³Department of Histopathology and Cytology, University of Khartoum, Khartoum, Sudan

*Corresponding Author

Department of Histopathology and Cytology, University of Khartoum, Khartoum, Sudan

Email: Hussaingad5@gmail.com

Peer-Review History

Received: 09 April 2022

Reviewed & Revised: 11/April/2022 to 28/April/2022

Accepted: 29 April 2022

Published: 07 May 2022

Peer-review Method

External peer-review was done through double-blind method.

URL: <https://www.discoveryjournals.org/medicallscience>



This work is licensed under a Creative Commons Attribution 4.0 International License.

ABSTRACT

Introduction: Snake venoms trigger a range of potentially fatal clinical toxicity syndromes. These include coagulopathy and associated hemorrhage, thrombotic microangiopathy, microangiopathic hemolytic anemia, thrombocytopenia, acute kidney injury, and neurotoxicity. **Case:** The present case experienced unusual complications with an old female presented with a snake (*Vipera berus*) bite. A 70-year-old diabetic female presented to our emergency department (ER) at 11:00am complaining of a snake bite. **Conclusion:** Snakebite (*Vipera berus*) can cause brain ischemic changes/infarction in large hypodense involving the left occipital-temporal region with attenuation of the temporal horn of the left lateral ventricle. Besides coagulation impairment, a snake bite can result in diverse, progressive complications, such as unconsciousness, and prolonged impairment in coagulation parameters, especially among elderly individuals with comorbidities.

Keywords: snakebite, venom, *Vipera berus*, brain

1. INTRODUCTION

Snakebite is an ordinary life-threatening medical condition that makes many people visit the emergency department, particularly in tropical areas (Rathod et al., 2022). Snakebite represents the most dangerous envenomation type. Incidence of snake bites surpasses six million with high mortality rates. Coagulopathy which results in bleeding disorders is usually associated with Viper bites (Assamadi et al., 2022). Snake venoms trigger a range of potentially fatal clinical toxicity syndromes. These comprise coagulopathy and its associated hemorrhage, thrombotic microangiopathy, microangiopathic hemolytic anemia, thrombocytopenia, acute kidney injury, neurotoxicity, etc. (Noutsos et al., 2022; Wium, 2021; Khan et al., 2020).

A snake bite usually causes local and systemic difficulties, mainly in the absence of anti-venom. Guidelines in this context reveal that the best management to be timely transported to nearest medical facility to hastily

given anti-venom. The venom causes cytotoxic, hemotoxic, and neurotoxic consequences, which require different interventions. Managing acute and chronic complications can enhance the outcomes of patients exposed to snakebite (Russell et al., 2021). However, the present case experienced unusual complications with an old female presented with a snake (Vipera berus) (figure 1) bite.

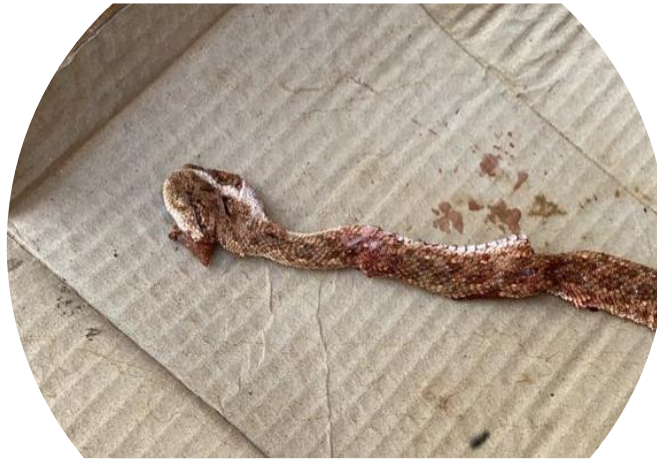

Figure 1 Vipera berus snake

2. CASE PRESENTATION

A 70-year old diabetic female presented to our emergency department (ER) at 11:00 am Wednesday complaining of a snake bite. The patient started to feel burning, severe pain in her left foot that extended to the leg. No change in mental status, no visual change, no difficulty in swallowing, no bleeding from any other site, no difficulty in breathing, no chest pain, no decreased urine output, no limb weakness, and numbness.

The systemic review was unremarkable. The patient was conscious & oriented Glasgow Coma Scale (GCS) 15/15. Vitals stable except for tachycardia 104bpm. Left leg swelling extended from the foot up to mid-leg, with tenderness to touch, with fang mark on the foot, peripheral pulse present with good volume, no ecchymosis, no necrotic tissues, no blistering, no lymph node swelling, no lower limb weakness or numbness, no ptosis, no drooling, no bleeding from other site or abnormal bleeding, no delay in capillary refill, no change in urine color. Other systemic examinations were unremarkable.

Laboratory investigations

Complete blood count (CBC) was average except for white blood cells (WBC) of 11.82. Chemistry was normal except for Fasting Blood Sugar (FBS) of 16.26. Creatine kinase myocardial band (CKMB) was elevated (36.1). The international normalized ratio (INR) was 1.13. Prothrombin time 15.4s. Partial thromboplastin time (PTT) 30.7. Platelet (Plt.) Count 214.

Course in admission

The patient was given two doses of anti-venom in ER and admitted for observation. On the next day, the patient had left leg swelling and discoloration in the morning, and at noon patient had sudden vomiting and followed by a Level of consciousness (LOC); on examination had small reactive pupil and right-side hemiplegia, GCS was 9/15 and patient shifted to Intensive Care Unit (ICU), and Computed tomography (CT) brain was ordered. CT result was normal brain parenchymal density, no definite focal lesion no sign of bleeding.

Coagulation profile

The ordered coagulation profile showed: INR 1.64. prothrombin time (PT) 21.9s. PTT 39.6s. Fibrinogen 55. Plt. Count 156.

At 7:00pm in ICU, the patient was in metoclopramide. The patient had an attack of hyperglycemia with vomiting and +1 ketonuria ABG Ph 7.34, pCO₂ 34.7, HCO₃ 19.6.

CT

Repeated CT showed Evidence of recent ischemic changes/infarction. Large hypodense recent ischemic areas were seen involving the left occipital-temporal region with attenuation of the temporal horn of the left lateral ventricle. The large hypodense recent ischemic area was seen at the left cerebellar hemisphere associated with slight attenuation of the 4th ventricle. A small hypodense ischemic patch was seen in the right occipital region (Figure 2).

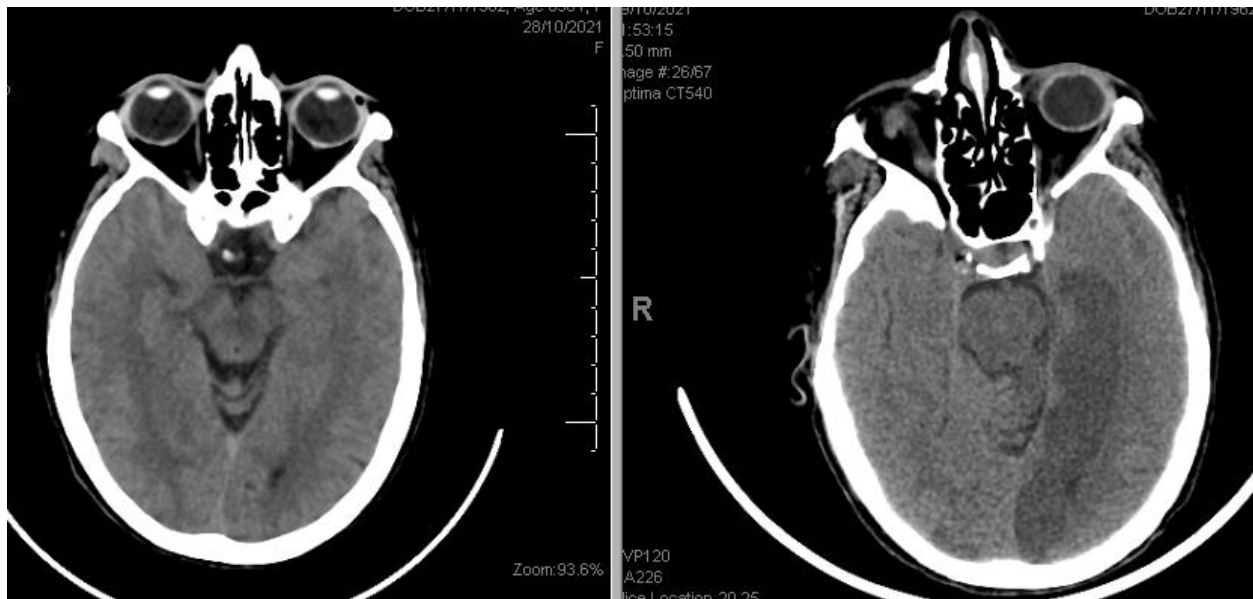


Figure 2 Comparing CTs

Coagulation profile was; INR 0.94, PT 43.9s, PTT pending, Plt. Count 128, FDP >20 g/l +ve. Doppler US was done and showed no DVT. The patient was given a third dose of anti-venom after contacting the toxicology center in the Ministry of Health and cryoprecipitate. On the 3rd day in the ICU, the patient recovered while still on a nasal cannula. The patient tolerated oral feeding.

Coagulation profile was INR .95, PT 13s, PTT 29.6s, Plt. Count 125. On the 5th day, the patient was vitally stable, and GCS was 13/15. Then she was shifted back to FMW. She did Abdominal US there and showed no peritoneal collection with multiple stones in the gallbladder. The patient was conscious & oriented, GCS 15/15. She can move all her limbs except her right hand was graded as 1/5. No lower limb swelling. Her last coagulation profile was INR 0.9, PT 10.9s, PTT 22s, and Plt. Count 118.

3. DISCUSSION

Snake venom can induce activation of the clotting pathway through procoagulant toxins, resulting in severe clotting factors consumption. The type of procoagulant toxins, which differs according to the type of snake, can activate prothrombin, factor X, and factor V or consume fibrinogen (Berling et al., 2015). These explain the changes in the laboratory measurement of coagulation and bleeding parameters. What is different in the case is that repeated CT showed Evidence of recent ischemic changes/infarction. Large hypodense recent ischemic areas were seen involving the left occipital-temporal region with attenuation of the temporal horn of the left lateral ventricle. The large hypodense recent ischemic area was seen at the left cerebellar hemisphere associated with slight attenuation of the 4th ventricle. A small hypodense ischemic patch was seen in the right occipital region. A recent study has reported brain CT scan objectified right temporoparietal ischemia associated with snakebite (Assamadi et al., 2022).

The type of snake, in this case, is *Vipera berus*. The toxic enzymatic activities of its venom include Phosphatase A2 (25%), serine proteinases (16%), metalloproteinases (17%), bradykinin-potentiating peptides (9.5%), C-type natriuretic peptides (7.8%), serine-rich secretory protein (8%), and L-amino acid oxidase (7%) (Al-Shekhadat et al., 2019). We think that the complications experienced in this patient resulted from potent venom toxicity on the one hand and the factors associated with the patient on the other hand. The patient was old enough to tolerate such venom. Previous studies have supported that snake bite is more dangerous in older people than in younger individuals (Feitosa et al., 2015).

Moreover, this patient was diabetic. There is a lack of literature concerning the complications of snake venom on diabetic patients. A study in this context has reported a non-diabetic patient with cellulitis following a snake bite. The patient experienced tigecycline-generated severe hypoglycemic episodes. These episodes continued for an extended duration. Such a case of severe and

persistent hypoglycemia due to tigecycline in a person without diabetes and not on any hypoglycemic agent may predict the interference of venom with blood glucose and lipid (Ray et al., 2020).

4. CONCLUSION

Snakebite (*Vipera berus*) can cause brain ischemic changes/infarction in large hypodense involving the left occipital-temporal region with attenuation of the temporal horn of the left lateral ventricle. Besides coagulation impairment, a snake bite can result in diverse, progressive complications, such as unconsciousness, and prolonged impairment in coagulation parameters, especially among elderly individuals with comorbidities.

Acknowledgement

We thank the emergency department staff at King Khalid Hospital who were all contributed the case investigation.

Author Contributions

Fahad Khalid ALQuwaiay: Conception, case analysis, manuscript drafting, approval of the final version.

Hessa abdullah alshammari: Case analysis, manuscript drafting, approval of the final version.

Abdulhafeez Osman Eltoum: Case analysis, manuscript drafting, approval of the final version.

Hani Abdulrahman Almutairi: Case analysis, manuscript drafting, approval of the final version.

Jaser Sultan Alshamari: Case analysis, manuscript drafting, approval of the final version.

Hussain Gadelkarim Ahmed: Supervision, critical revision of manuscript, approval of the final version.

Funding

This study has not received any external funding.

Conflicts of interest

The authors declare that there are no conflicts of interests.

Data and materials availability

All data associated with this study are present in the paper.

REFERENCES AND NOTES

- Al-Shekhadat RI, Lopushanskaya KS, Segura Á, Gutiérrez JM, Calvete JJ, Pla D. *Vipera berus berus* Venom from Russia: Venomics, Bioactivities and Preclinical Assessment of Microgen Antivenom. *Toxins (Basel)* 2019; 11(2):90. doi:10.3390/toxins11020090.
- Assamadi M, M Berek YA, Elallouchi Y, Benantar L, Aniba K. Accident vasculaire cérébral ischémique, complication inhabituelle d'une morsure de vipère: à propos d'un cas [Ischemic stroke, an unusual complication of snake bite: case report]. *Pan Afr Med J* 2022; 41:50. French. doi: 10.11604/pamj.2022.41.50.22225.
- Assamadi M, M Berek YA, Elallouchi Y, Benantar L, Aniba K. Accident vasculaire cérébral ischémique, complication inhabituelle d'une morsure de vipère: à propos d'un cas [Ischemic stroke, an unusual complication of snake bite: case report]. *Pan Afr Med J* 2022; 41:50. French. doi: 10.11604/pamj.2022.41.50.22225.
- Berling I, Isbister GK. Hematologic effects and complications of snake envenoming. *Transfus Med Rev* 2015; 29(2):82-9. doi: 10.1016/j.tmr.2014.09.005.
- Feitosa EL, Sampaio VS, Salinas JL, Queiroz AM, da Silva IM, Gomes AA, et al. Older Age and Time to Medical Assistance Are Associated with Severity and Mortality of Snakebites in the Brazilian Amazon: A Case-Control Study. *Plos One* 2015; 10(7): e0132237. <https://doi.org/10.1371/journal.pone.0132237>.
- Khan KI, Ghule A, Kumar S. Dry Bite by Common krait: A rare phenomenon & its management; rationale use of antivenom. *Medical Science* 2020; 24(104):2418-2423
- Noutsos T, Currie BJ, Wijewickrama ES, Isbister GK. Snakebite Associated Thrombotic Microangiopathy and Recommendations for Clinical Practice. *Toxins (Basel)* 2022; 14(1):57. doi: 10.3390/toxins14010057.
- Rathod SG, Khan AA, Geelani SA, Roshan R, Bhat JR. Rare snake bite- A case report. *Trop Doct* 2022; 494755211066680. doi: 10.1177/00494755211066680.
- Ray A, Sharma S, Atal S, Sadasivam B, Jhaj R. Tigecycline-Induced Severe Hypoglycemia in a Non-Diabetic Individual: A Case Report and Brief Review of Tigecycline-Induced Severe Hypoglycemia. *Am J Case Rep* 2020; 21:e924556. doi: 10.12659/AJCR.924556.

10. Russell JJ, Schoenbrunner A, Janis JE. Snake Bite Management: A Scoping Review of the Literature. *Plast Reconstr Surg Glob Open* 2021; 9(4):e3506. doi: 10.1097/GOX.0000000000003506.
11. Wium L. Neurotoxic snake bite in pregnancy. *Obstet Med* 2021; 14(3):187-189. doi: 10.1177/1753495X211019236.