

A case report of transilluminant swelling in the neck a rare presentation in adult

Raghupathy Thirunavikkarasu¹, Magesh², Abhirama R^{3*}

ABSTRACT

Cavernous lymphangioma is a lymphatic vessel proliferative disorder resulting from abnormal lymphatic system development. As a congenital lesion, cystic hygroma is rather prevalent in children than in older age group. In the literature, barely a few occurrences of Cystic hygroma in adults have been described. Cystic hygroma is more prevalent in the cranio-cervical region, but it can occur however appear anywhere along the lymphatic channel's path. This case report is an example of an unusual presentation of Cystic hygroma, which manifested as a right-sided cystic neck swelling in an adult female. Clinical assessment, pathological identification, surgical management, and post-operative follow-up are all covered in due course.

Keywords: Cystic hygroma, cervical mass, Lymphangioma

To Cite:

Thirunavikkarasu R, Magesh, Abhirama R. A case report of transilluminant swelling in the neck a rare presentation in adult. *Medical Science*, 2022, 26, ms158e1992.

doi: <https://doi.org/10.54905/disssi/v26i123/ms158e1992>

Authors' Affiliation:

¹Professor, Department of General surgery, Sree Balaji Medical College and Hospital, Chromepet, Chennai 600044, India

²Assistant Professor, Department of General surgery, Sree Balaji Medical College and Hospital, Chromepet, Chennai 600044, India

³PG, Department of General surgery, Sree Balaji Medical College and Hospital, Chromepet, Chennai 600044, India

*Corresponding Author

PG, Department of General surgery, Sree Balaji Medical College and Hospital,

Chromepet Chennai 600044, India

Email: abhiramark@gmail.com

Peer-Review History

Received: 05 January 2022

Reviewed & Revised: 09/January/2022 to 24/April/2022

Accepted: 28 April 2022

Published: 02 May 2022

Peer-review Method

External peer-review was done through double-blind method.

URL: <https://www.discoveryjournals.org/medicallscience>



This work is licensed under a Creative Commons Attribution 4.0 International License.

1. INTRODUCTION

Cystic hygroma is a lymphatic vessel proliferative disorder resulting from abnormal lymphatic system development. The terms lymphangioma and lymphatic malformation are used interchangeably in the literature to describe cystic hygroma. Cystic hygroma develops due to sequestration or obstruction during the development phase of lymphatic vessels and thus a benign congenital lymphatic malformation (Bloom et al., 2009; Fliegelman et al., 2000; Naidu & McCalla, 2004). Lymphangioma is a condition that occurs in children when the lymphatic system is active. Cystic hygromas usually appear as a single or several cysts in the neck area. Cystic hygroma can occur as a congenital condition or develop at any point in a person's life (Fidan & Sutbeyaz, 2008). It predominantly affects children under two years of age; however the manifestation in adults is rare. Rarely presents during adulthood, cause is idiopathic, however did invasion of microorganism in upper respiratory tract and history of trauma consider as plausible cause for onset (Gow et al., 2011). The clinical manifestation Cystic hygroma varies depending on its rate of growth malformation, size and location (Kasapoglu & Yildirim, 2008; Sherman & Kendall, 2011; Dokania et al., 2017). Diagnosis in children is relatively easier in comparison to adults and final diagnosis depends on postoperative histology. There was no apparent aetiology in this case, and the start was gradual. We want to draw more attention to the rarity of cavernous

lymphangioma in adults and its importance in the different causes of cervical masses in adults.

2. CASE PRESENTATION

A 57-year-old woman presented with painless right-side neck swelling for the past three months in our instance. Swelling's onset was insidious and grew slowly in size until it reached its current size. She didn't have any signs of a compression of neck, such as trouble swallowing or breathing. There had been no previous neck trauma or infection of the upper respiratory system or fever or tooth infection or pus discharge or any difficulty in opening the mouth or dysphagia or dyspnea any history of significant loss of weight. Physical examination revealed a single swelling on the right anterior and posterior aspect of neck measuring about 8 x 6 cm. Margins were well-defined. Medially till the midline of neck, laterally up to lateral border of sternocleidomastoid, superiorly up to 3 cm below base of mandible and inferiorly 2cm above the clavicle. The swelling on palpation, the surface was lobular, consistency was soft, and the mobility was restricted. With deglutition, the swelling was immovable also no warmth, erythema, tenderness or cervical lymphadenopathy (figure 1).

Tran's illumination test is positive. Ultrasound scanning demonstrated a massive elliptical cystic lesion extending from the right sternocleidomastoid muscle anteromedially to the right submandibular gland medially; measuring 8x5x3 cm. Cyst disclosed slender septae and loculations on the periphery. Avascularity was found in the cyst wall and inter-locular septae. A diagnosis favoring lymph cyst of lateral side neck was reported by the radiologist. Surgery was done under general anesthesia. Low transverse [supraclavicular] neck incision about 4cm was put for better cosmesis. The skin along with platysma were raised as a flap and dissected and the cystic mass, which measured around 5 cm in diameter at its widest point (figure 2). Cyst was shown to be laying over internal jugular vein, carotid artery, and spinal accessory nerve after being separated in planes. The cyst was pushing the sternocleidomastoid muscle laterally and superiorly extending up to the mandible. The cyst was completely removed. A sterile dressing was applied after the sutures were inserted in two layers. Dressing was removed on post op day 2, wound was found to be healthy with sutures intact with no feature surgical site infection. The diagnosis of cystic lymphangioma was confirmed from the histopathological report (figure 3). Regular daily dressing was done, sutures removal done on 10th postoperative day, displaying a healthy wound. Patient has been followed up for a year and there were no signs of recurrence.

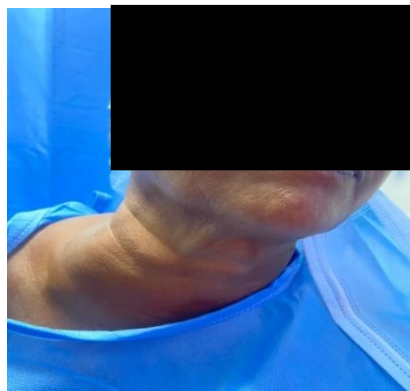

Figure 1 Swelling on the right anterior and posterior aspects of the neck in this pre-operative photograph.

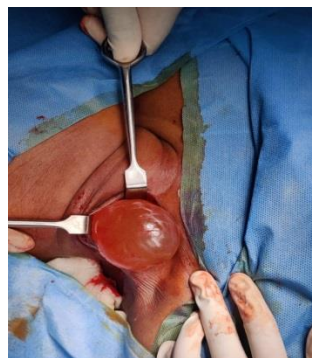

Figure 2 Meticulous dissection of cystic hygroma along with its excision in toto.

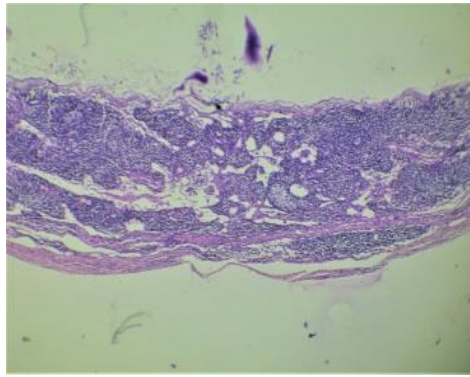


Figure 3 Shows Cyst lined by flattened epithelium with the wall containing dilated spaces in fibro collagenous stroma infiltrated by lymphocytes. An adjacent focus shows lymphoid aggregates.

3. DISCUSSION

Lymphangioma, or cystic hygroma, is a congenital disorder that affects the lymphatic system. In 1828 Redenbacher reported it at first and in 1834 Wernher first used the name cystic hygroma (Sherman & Kendall, 2001). Lymph buildup is caused by a breakdown in embryological development between the lymphatic and venous systems (Mallick et al., 2014). However, the aetiology of cystic hygroma in adults is debatable, and acquired processes such as, trauma [including surgery], infection or lymphatic blockage have been suggested (Kennedy, 1989; Nosan et al., 1995; Gleason et al., 1993). They are classified into macrocystic (more than 2 cm) and microcystic (less than 2 cm) based on the size of the cysts of variable sizes are referred as mixed lymphangioma. Six lymphatic sacs develop during the 8th week of embryogenesis. These lymph sacs interact with the lymphatic network as the lymphatico-venous system develops. In 9th week of gestation, the connective tissues invade these sacs to form lymph nodes and due to failure in communication of sequestered lymphatic sacs with lymphatic or venous system Cystic hygroma develops.

The Cystic hygroma's cystic morphology containing serous, serosanguinous or straw-colored fluid is because of these sequestered lymphatic tissues dilatation (Fonkalsrud, 2006). Cystic hygroma commonly presents in cervicofacial region (75-80%), axilla, mediastinum and groin. However, they can manifest in any region of the body. Omentum, oral cavity and mesentery include the other regions. Chest wall, supra-sternal area, deltoid, lumbar region, limbs and cheek include the rarer regions. Owing to the fact of Cystic hygroma's infiltrative nature, they cause neural encroachment resulting from extension initially to soft tissue of neck then cross midline to reach the axilla and mediastinum. The majority appear before 24 months [60 %] or at delivery [90 %], hence pediatric age group are considered by most of the literature regarding management of cystic hygroma's (Kaur et al., 2007). Site and relationship to neighboring structures determine the symptoms of cystic hygroma. Painless asymptomatic lump in adults is frequently reported presentation. Frequently reported have been cases with rapid enlargement over a short duration of time (Kraus et al., 2008; De Casso Moxo et al., 2001; Vaid et al., 2010), resulting from incorporation and compression of the larynx, trachea, oesophagus, brachial plexus and great vessels (Cheng & Wells, 2004). Manifesting with pain, hoarseness, dysphagia, dyspnea (Kraus et al., 2008; Cheng & Wells, 2004; Vaid et al., 2010), and resulting in neck movement restriction (Gow et al., 2011). Microbial contamination, abscessus, hemorrhage and cyst-rupture include the other complications. As proposed by de Serres Cystic hygromas can be staged (De CassoMoxo et al., 2001). Computed tomography, MRI and ultrasound scan are diagnostic modalities that can be used to support the diagnosis.

Our patient's diagnosis, on the other hand, was made clinically and confirmed by an ultrasound scan. The alternatives for treatment include surgical excision, simple drainage, irradiation, laser excision, cauterization, radio-frequency ablation and sclerotherapy (Sheila et al., 2010). Medical management with intralesional sclerosants has been attempted in the treatment of cystic hygroma, but with limited success in their application, owing to a dramatic upsurge in recurrence rates, rapid growth in size of lesion, inflammation, and variation in normal tissue plane and a dearth of tissue biopsy specimen for conclusive histological diagnosis (Zhong et al., 1998). In postsurgical recurrence, intravenous administration of chemotherapeutic drugs cytophosphane found effective (Turner & Gross, 1994). In adult-onset cystic hygromas, to prevent recurrence surgical excision by thorough and complete dissecting of the swelling from neighboring structures remains the basis of treatment (Naidu & McCalla, 2004). The placement of skin incision necessitates following along langer's lines as anywhere else in body surface. In view of superior cosmesis we preferred a supraclavicular incision, despite the cyst's dome being in the middle of the neck. Without unnecessary tension,

retraction, or compromising of the flaps, enough exposure to the top and lower parts of the cyst is the advantages of considering a mid-cervical incision.

However, to the patient cosmetically it would be unsatisfactory. Considering cosmetic acceptability and to hide the surgical scar beneath the clothing, a low transverse supraclavicular incision was preferred over a highly placed incision. Without jeopardizing blood supply flap by excessive traction, to reach the uppermost part of the cyst was the predominant challenge. Normal neurovascular structures in the neck must be preserved at all costs. Complete surgical excision is more feasible in lesions of adult type of cystic hygroma, since they are well defined, in contrast to the congenital variety (Naidu & McCalla, 2004).

Infection of wound, bleeding, hypertrophied scar and lymphorrhea all common postoperative sequelae after cystic hygroma excision. Recurrence of complex cystic hygromas is estimated to occur in roughly 10–27% of instances despite complete apparent excision, and 50–100% in cases of partial excision (Dillon, 1997). Recurrence is caused by incomplete excision, which is more common in the microcystic and mixed types due to their proclivity to interdigitate into tissue planes, engulfing neural and circulatory structures, making total excision arduous and perilous. Despite these risks, excision of the cavernous lymphangioma is the preferred method (Seashore et al., 1985).

Since it is the first operative intervention and the best treatment modality that provides best chance for complete excision, option of surgery was preferred in our patient. Surgery was forthright, we preserved all vital structures of neck, with no untoward complication encountered in postoperative period and until date no there is no report of any recurrence.

4. CONCLUSION

Though Cystic hygroma is a known entity in pediatric population, it can affect anyone at any age. However, manifestation in adults is rare. It's crucial to find out cause of cervical masses in adults because of its diverse presentation. Frequent documentation of cavernous lymphangioma in adults will help to clarify diverse presentations, diagnostic problems, therapeutic options, and consequences. Surgery is the first operative intervention and best treatment modality that provides the best chance for complete excision. This case adds to the corpus of knowledge in identification of neck masses in adults.

Informed consent

Written & Oral informed consent was obtained from all individual participants included in the study.

Funding

This study has not received any external funding.

Conflicts of interest

The authors declare that there are no conflicts of interests.

Data and materials availability

All data associated with this study are present in the paper.

REFERENCES AND NOTES

1. Bloom DC, Perkins JA, Manning SC. Management of lymphatic malformations and macroglossia: results of a national treatment survey. *Int J Pediatr Otorhinolaryngol* 2009; 73(8):1114-8.
2. Cheng LHH, Wells FC. A multidisciplinary approach to recurrent cervicothoracic cystic hygroma in an adult. *Br J Oral Maxillofac Surg* 2004; 42:66-8.
3. De CassoMoxo C, Lewis NJ, Rapado F. Lymphangioma presenting as a neck mass in the adult. *Int J Clin Pract* 2001; 55:337-8.
4. Dillon P. Lymphatic and venous disorders. In: Oldham KT, Colombani PM, Foglia RP, editors. *Surgery of Infants and Children: Scientific Principles and Practice*. Philadelphia: Lippincott Raven; 1997; 1727-43.
5. Dokania V, Rajguru A, Kaur H, Agarwal K, Kanetkar S, Thakur P, Patel F, Shukla D. Sudden onset, rapidly expansile, cervical cystic hygroma in an adult: a rare case with unusual presentation and extensive review of the literature. *Otolaryngol Case Rep* 2017; 2017:1061958.
6. Fidan V, Sutbeyaz Y. Lingual cystic lymphangioma in an elderly patient. *Kulak Burun Bogaz Ihtis Derg* 2008; 18(4):260-2.
7. Fliegelman LJ, Friedland D, Brandwein M, Rothschild M. Lymphatic malformation: predictive factors for recurrence. *Otolaryngol Head Neck Surg*. 2000; 123(6):706-10.

8. Fonkalsrud EW. Lymphatic disorders. In: Grosfeld JL, O'Neill JA Jr, Coran JA, Fonkalsrud EW, Caldamone AA, editors. Pediatric surgery. 6th ed. Chicago: Mosby Elsevier; 2006. pp. 2137–45.
9. Gleason TJ, Yuh WTC, Harris KG. Traumatic cervical cystic lymphangioma in an adult. *Ann Otol Rhinol Laryngol* 1993; 102(7): 564–566.
10. Gow L, Gulati R, Khan A, Mihaimeed F. Adult-onset cystic hygroma: a case report and review of management. *Grand rounds* 2011; 11(1):5-11.
11. Kasapoglu F, Yildirim N. Cystic hygromacolli in adults: a report of two cases, one with atypical location. *Kulak Burun Bogaz Ihtis Derg* 2008; 18(5):326-9.
12. Kaur N, Gupta A, Amratash, Singh N. Giant cystic hygroma of the neck with spontaneous rupture. *J Indian Assoc Pediatr Surg* 2007; 12:154–5.
13. Kennedy TL. Cystic hygroma: lymphangioma: a rare and still unclear entity. *Laryngoscope* 1989; 99 (10 part 2 Suppl 49): 1–10.
14. Kraus J, Plzak J, Bruschini R. Cystic lymphangioma of the neck in adults: a report of three cases. *Wiener Klin Wochenschr* 2008; 120:242–5. doi:10.1007/s00508-008-0950-4.
15. Mallick KC, Khatua RK, Routray S, Lenka A. Cystic hygroma in adults: a rare case report. *J Evol Med Dent Sci* 2014; 3(10): 2561–2564.
16. Naidu SI, Mc Calla MR. Lymphatic malformations of the head and neck in adults: a case report and review of the literature. *Ann Otol Rhinol Laryngol* 2004; 113: 218–222.
17. Nosan DK, Martin DS, Stith JA. Lymphangioma presenting as a delayed posttraumatic expanding neck mass. *Am J Otolaryngol* 1995; 16(3): 186–189.
18. Seashore JH, Gardiner LJ, Ariyan S. Management of giant cystic hygromas in infants. *Am J Surg* 1985; 149:459–65.
19. Sheila S, Nazarian-Mobin, Simms K, Urata MM, Tarczy-Hornoch K, Jeffrey A. Misleading presentation of an orbital lymphangioma. *Oral Surg Oral Med Oral Pathol Oral Radiol Endod* 2010; 109:82–5.
20. Sherman BE, Kendall K. A unique case of the rapid onset of a large cystic hygroma in the adult. *Am J Otolaryngol* 2001; 22(3): 206–210.
21. Turner C, Gross S. Treatment of recurrent suprahyoid cervico-facial lymphangioma with intravenous cyclophosphamide. *Am J Pediatr Hematol Oncol* 1994; 16(4):325–328.
22. Vaid L, Gupta M, Gupta N, Singh P. Bleomycin sclerotherapy in a rare case of adult-onset cervical lymphangioma. *Ear Nose Throat J* 2010; 89:E23–6.
23. Zhong PQ, Xhi FX, Li R. Long-term results of intratumorous bleomycin-A5 injection for head and neck lymphangioma. *Oral Surg Oral Med Oral Pathol Oral Radiol Endod* 1998; 86:139–144.