

## Avulsion of triceps tendon - a rare entity

Ankit Mittal<sup>1</sup>, Siddharth Jain<sup>2\*</sup>, Ankit Jaiswal<sup>3</sup>, Sandeep Shrivastava<sup>4</sup>

### To Cite:

Mittal A, Jain S, Jaiswal A, Shrivastava S. Avulsion of triceps tendon - a rare entity. *Medical Science*, 2022, 26, ms107e2164.  
doi: <https://doi.org/10.54905/disssi/v26i121/ms107e2164>

### Authors' Affiliation:

<sup>1</sup>Post Graduate Resident, Department of Orthopaedics, Jawaharlal Nehru Medical College, Datta Meghe University, Sawangi (Wardha), Maharashtra, India; Email: [drmittalankit1314@gmail.com](mailto:drmittalankit1314@gmail.com)

<sup>2</sup>Assistant Professor, Department of Orthopaedic, Jawaharlal Nehru Medical College, Datta Meghe University, Sawangi (Wardha), Maharashtra, India; Email: [dr.sidrajain@gmail.com](mailto:dr.sidrajain@gmail.com)

<sup>3</sup>Post Graduate Resident, Department of Orthopaedic, Jawaharlal Nehru Medical College, Datta Meghe University, Sawangi (Wardha), Maharashtra, India

<sup>4</sup>Professor, Department of Orthopaedic, Jawaharlal Nehru Medical College, Datta Meghe University, Sawangi (Wardha), Maharashtra, India

### \*Corresponding author

Assistant Professor, Department of Orthopaedics, Jawaharlal Nehru Medical College, Datta Meghe Institute of Medical Sciences, Wardha, Maharashtra, India  
Email: [dr.sidrajain@gmail.com](mailto:dr.sidrajain@gmail.com)

### Peer-Review History

Received: 04 March 2022

Reviewed & Revised: 06/March/2022 to 19/March/2022

Accepted: 20 March 2022

Published: 25 March 2022

### Peer-review Method

External peer-review was done through double-blind method.

URL: <https://www.discoveryjournals.org/medicalscience>



This work is licensed under a Creative Commons Attribution 4.0 International License.

### ABSTRACT

**Background:** The Avulsion of triceps muscle tendon is a very uncommon tendinous damage. Avulsions could be partial and/or entire, and they can be fractured or not. The most obvious source of injury is a fall onto an extended hand; however injuries can also occur following direct contact. Diagnosis will be aided by a great degree of suspicion, physical assessment for a palpable gap, and lateral radiographs exhibiting a "flake fracture". Early detection and surgically repairing a full rupture typically leads in favorable outcomes. **Case presentation:** We show a case presentation of avulsion of triceps tendon coupled with olecranon chip fracture that was reduced and stabilized with two k-wires and later reinforced with tension band wiring. As a consequence, the patient had a strong complete motion of joint and power equivalent to the contralateral area. A great degree of suspicion, physical assessment for a palpable gap, and lateral radiography for a "flake fracture" will all assist to confirm triceps avulsion.

**Keywords:** Triceps avulsion, K wire, tension band wiring

## 1. INTRODUCTION

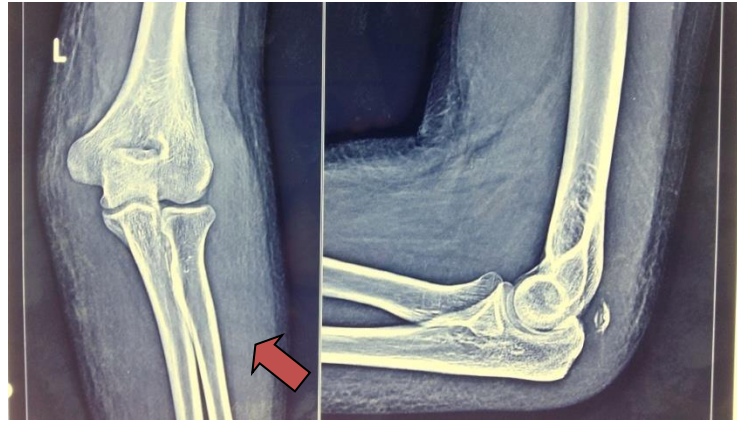
Avulsion of tendinous insertion of triceps muscle is a rare type of injury (McMaster, 1933). This injury comprises fewer than one percent of whole tendon damages of upper limbs (Anzel et al., 1959). Osseous tendon insertion at the olecranon is the commonest location for such injuries, which rarely exists at the muscle or myotendinous junction (Aso & Torisu, 1964; Bach et al., 1987). Avulsions can be total or partial, without or with fractures. A fall onto an extended hand is the most prevalent form of injury; however injuries can also happen after direct contact. Due to lack of proper reporting and scarcity of literature; no well-justified, universally accepted treatment protocol has been established yet (Vidal et al., 2004). We show a case presentation of avulsion of triceps tendon coupled with olecranon chip fracture because of fall on to outstretched hand treated surgically by k wire fixation and reinforced with tension band wiring method with a decent functional outcomes.

## 2. CASE PRESENTATION

In August 2020, a 24-year-old student presented to AVBRH Sawangi with complaints of discomfort and edema around the left elbow following a road traffic collision. The patient went to the hospital shortly after the injury. A first

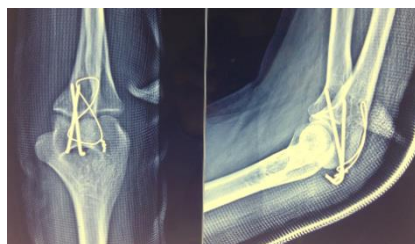physical examination indicated considerable soreness and edema on the posterior region of his left elbow, and the patient had difficulty in actively extending his elbow following the injury. A reexamination revealed a palpable depression slight proximally to olecranon, thus the patient was hospitalized for workup. In a lateral radiograph of the afflicted elbow (Fig 1), a tiny avulsed osseous fragment of olecranon (the 'flake' sign) was discovered.

Diagnosis of complete triceps tendon avulsion was made in presence of signs like palpable depression proximally to the olecranon, active elbow extension loss and clinical correlation with radiograph. Surgical reconstruction was performed after conformation of the diagnosis.

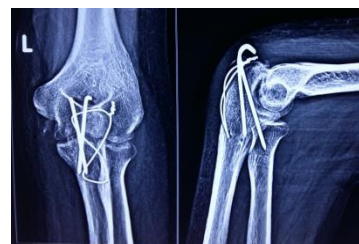

**Figure 1** Avulsed olecranon osseous fragment (the 'flake' sign)

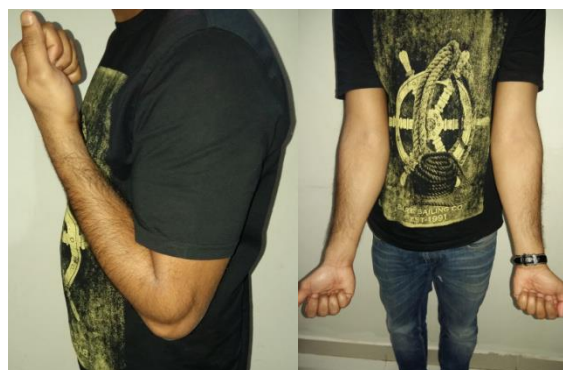The procedure was performed while wearing a tourniquet. The affected elbow was exposed by a curvilinear incision on the back, the damage site was identified, and the hematoma was evacuated. The Triceps tendon along with flack of bone was found retracted approximately two cm proximally from the tip of olecranon. The bony flake attached with triceps tendon, was reduced and stabilized using two k-wires later for reinforcement tension band wiring done (Fig-2A). After surgery, the arm remained immobilized in a posterior above elbow slab at eighty degree of flexion for three weeks before beginning active flexion. After six weeks, active extension was initiated (Fig-2B). Three months following the procedure, the k-wires were removed. After six months, the patient's left elbow had regained its entire range of active movement and muscular strength. Complete recovery and full muscle bulk observed after 1 year (Fig-3).



**Figure 2 (A)** Immediate post-op X- ray



**(B)** Follow-up X-ray at 6 weeks



**Figure 3** follow-up clinical photographs at 12 month

### 3. DISCUSSION

Triceps avulsion is comparatively a rare injury, least frequently seen among injuries of all tendons in body (Waugh et al., 1949). Triceps avulsions are often missed in emergency setting. Because probing of the gap proximally from the olecranon tip, examination of ROM, and triceps muscular strength may be problematic to perform regarding of discomfort, edema, and muscle spasm, a high degree of suspicion is needed to identify this injury in a patient following trauma. The most frequent differential diagnosis for elbow injuries comprises radial head fracture, sprain, olecranon bursitis, and fractures surrounding to elbow joint (Van Reit et al., 2003). After finishing initial care, wait for swelling to subside before doing a second examination in suspected instances. A Roentgen graphic examination frequently displays a "flake fracture", which is an olecranon avulsion fracture (fig 1). To rule out additional fractures, the x-rays shall be examined carefully. In such circumstances, an MRI or ultrasound might be utilized to confirm the diagnosis.

Triceps avulsion is typically because of indirect trauma like falling with limb extended on an outstretched hand (Bennett, 1962). Rarely this injury can be seen after a direct impact. It can also be seen in sport persons and active adult, commonly involved in heavy physical activities like body building and wrestling (Rajasekhar et al., 2002). It has also been described as a minor trauma in presence of some local or systemic comorbidity, which affect the integrity and the strength of triceps tendon. Systemic disease comprises of chronic renal failure, diabetes mellitus, rheumatoid arthritis, hyperparathyroidism, osteogenesis-imperfecta and commonest local cause of including locally steroid infiltrations, Degenerative arthritis causes olecranon bursitis and attritional alterations (Mair et al., 2004; Harris et al., 2004).

The quantity of rupture of tendon and the loss of triceps power are the most crucial variables in determining the therapy approach. If patient is capable of active elbow extension against gravity (triceps power  $>3/5$ ), the damage is only partial and could be managed non-surgically for four weeks in an above elbow cast in 30 degree flexion (Farrar & Lippert, 1981). Even with a 95% rupture, lateral triceps expansion to the forearm fascia maintains active elbow extension. MRI is the most convenient for detecting the tears percentage and is thus essential in preoperative treatment. If an MRI indicates a substantial tear of greater than 50% and considerable loss of triceps power (triceps power  $3/5$ ), repairing of torn tendon is surgically advised (Strauch, 1999).

Trans osseous sutures via horizontal bone tunneling technique in the olecranon utilizing non-absorbable suture (Levy, 1987), "K-wire fixation strengthened by bone anchor and encirclage wire" are some previously published surgical procedures for repairing acute and full rupture with satisfactory functional success (Tsourvaka et al., 2004). More sophisticated operations, such as V-Y advancement and tendon grafting, will be required in some circumstances, such as ruptures near the musculotendinous junction or ignored ruptures.

### 4. CONCLUSION

To sum up the tendon avulsion of triceps muscle is infrequent tendon damage. It can arise as a consequence of indirect or direct trauma and is most commonly found around the olecranon at the Osseo-tendinous junction. A great level of suspicion, physical assessment for a palpable gap, and lateral radiographs with a "flake fracture" will assist in diagnosis and management. Early detection and surgical repair of a full rupture typically yields excellent outcomes.

#### **Author's Contribution**

All authors contributed equally to the manuscript.

#### **Acknowledgement**

We thank the patient who participated and contributed sample to the study.

#### **Informed Consent**

Written & Oral informed consent was obtained from all individual participants included in the study. Additional informed consent was obtained from all individual participants for whom identifying information is included in this manuscript.

#### **Funding**

This study has not received any external funding.

#### **Conflicts of interest**

The authors declare that there are no conflicts of interests.

**Data and materials availability**

All data associated with this study are present in the paper.

**REFERENCES AND NOTES**

1. Anzel SH, Covey KW, Weiner Ad, Lipscomb PR. Disruption of muscle and tendons. An analysis of 1014 cases. *Surgery* 1959; 45(3):406–414.
2. Aso K, Torisu T. Muscle belly tear of triceps. *AM J Sports Med* 1964; 12(6):485–487.
3. Bach BR, Jr, Warren RF, Wickiewicz TL. Triceps rupture. A case report and literature review. *Am J Sports Med* 1987; 15(3):285–289.
4. Bennett BS. Triceps tendon rupture. Case report and a method of repair. *J Bone Joint Surg Am* 1962; 44(4):741–744.
5. Farrar EL, Lippert FG. 3rd Avulsion of the triceps tendon. *Clin Orthop Relat Res* 1981; 161:242–246.
6. Harris PC, Atkinson D, Moorehead JD. Bilateral Partial rupture of triceps tendon: case report and quantitative assessment of recovery. *Am J Sports Med* 2004; 32:787–792.
7. Levy M. Repair of triceps tendon avulsions or ruptures. *J Bone Joint Surg Br* 1987; 69:115.
8. Mair SD, Isbell WM, Gill TJ, Schlegel TF, Hawkins RJ. Triceps tendon ruptures in professional football players. *Am J Sports Med* 2004; 32:431–434.
9. McMaster PE. Tendon and muscle rupture. Clinical and experimental studies on the causes and location of subcutaneous rupture. *J Bone Joint Surg Am* 1933; 15(3):705–722.
10. Rajasekhar C, Kakarlapudi TK, Bhamra MS. Avulsion of the triceps tendon. *Emerg Med J* 2002; 19:271–272.
11. Strauch RJ. Biceps and triceps injuries of the elbow. *Orthop Clin North Am* 1999; 30:95.
12. Tsourvaka S, Gouvalas K, Gimtsas C, Tsianas N, Founta P, Ameridis N. Bilateral and simultaneous rupture of the triceps tendons in chronic renal failure and secondary hyperparathyroidism. *Arch Orthop Trauma Surg* 2004; 124:278–280.
13. Van Reit RP, Morrey BF, Ho E, O'Driscoll SW. Surgical treatment of distal triceps ruptures. *J Bone Joint Surg Am* 2003; 85-A:1961–1967.
14. Vidal AF, Drakos MC, Allen AA. Biceps tendon and triceps tendon injuries. *Clin Sports Med* 2004; 23:707–722.
15. Waugh RL, Hathcock TA, Elliott JL. Ruptures of muscles and tendons: with particular reference to rupture or elongation of long tendon of biceps brachii with report of fifty cases. *Surgery* 1949; 25(3):370–392.