

## Facial colliculus syndrome with inflammatory cranial neuritis in a patient with covid 19 with mucormycosis superinfection

**To Cite:**

Khanna S, Talwar D, Kumar S, Acharya S, Hulkoti V, Madan S. Facial colliculus syndrome with inflammatory cranial neuritis in a patient with covid 19 with mucormycosis superinfection. *Medical Science*, 2021, 25(113), 1517-1521

**Author Affiliation:**

<sup>1</sup>Post Graduate Resident, Department of Medicine, Jawaharlal Nehru Medical College, Datta Meghe Institute of Medical Sciences (Deemed to be University), Wardha, Maharashtra, India

<sup>2</sup>Professor, Department of Medicine, Jawaharlal Nehru Medical College, Datta Meghe Institute of Medical Sciences (Deemed to be University), Wardha, Maharashtra, India

<sup>3</sup>Professor and Head of Department, Department of Medicine, Jawaharlal Nehru Medical College, Datta Meghe Institute of Medical Sciences (Deemed to be University), Wardha, Maharashtra, India

<sup>4</sup>Post Graduate Resident, Department of Obstetrics and Gynaecology, Jawaharlal Nehru Medical College, Datta Meghe Institute of Medical Sciences (Deemed to be University), Wardha, Maharashtra, India

**Corresponding author**

Professor and Head of Department, Department of Medicine, Jawaharlal Nehru Medical College, Datta Meghe Institute of Medical Sciences (Deemed to be University), Wardha, Maharashtra, India  
Email: souaryaacharya74@gmail.com

**Peer-Review History**

Received: 18 May 2021

Reviewed & Revised: 19/May/2021 to 16/June/2021

Accepted: 17 June 2021

Published: July 2021

**Peer-review Method**

External peer-review was done through double-blind method.

Shivam Khanna<sup>1</sup>, Dhruv Talwar<sup>1</sup>, Sunil Kumar<sup>2</sup>, Sourya Acharya<sup>3✉</sup>, Vidya Hulkoti<sup>1</sup>, Sparsh Madan<sup>4</sup>

### ABSTRACT

Features of unilateral cranial nerve 7<sup>th</sup> lower motor neuron palsy and same sided 6<sup>th</sup> nerve involvement without hemiplegia or hemiparesis is a rare clinical entity in itself, which is referred to as Facial Colliculus Syndrome. This presentation was noticed in a patient of Covid 19 positive status and mucormycosis not on prolonged steroid treatment. This is a case report of an 80-year old female patient who was admitted to the medical ward of our hospital with presenting complaints of breathlessness and fever of 5 days duration. Later during course of the disease on followup in hospital she developed left sided 6<sup>th</sup> and 7<sup>th</sup> cranial nerve involvement. This case report highlights the case of an elderly female patient presenting with cranial nerve involvement with mucormycosis with covid 19 superinfection on follow-up after home quarantine.

**Keywords:** Facial Colliculus Syndrome, Cranial Neuritis, Mucormycosis, Covid-19

### 1. INTRODUCTION

Though occurrence of neurological manifestation of Covid 19 presenting as anosmia, headache, even seizures, stroke and Gulliane Barre Syndrome, have been reported recently, but isolated and multiple cranial neuropathy has become a new rare finding in Covid 19 positive patients. Mucormycosis is a well known entity in diabetes and immunocompromised states (Jain et al., 2011). The ability of these species to be angioinvasive may result in direct infiltration into the blood vessels and thrombosis or emboli presenting as an acute ischaemic stroke (Dronamraju et al., 2021). But its presentation as cranial neuritis is not a common occurrence. The absence of gross intracranial involvement of any sinuses makes this case even more unique. As cranial neuropathy here, can not be directly linked to mucormycosis alone and more probably linked to SARS-CoV2 infection. There has been an increased interest in the neurological manifestations of Covid 19 and this case reports highlights another unique neurological finding of Facial Colliculus Syndrome on presentation in a Covid 19 patient.



© 2021 Discovery Scientific Society. This work is licensed under a Creative Commons Attribution 4.0 International License.

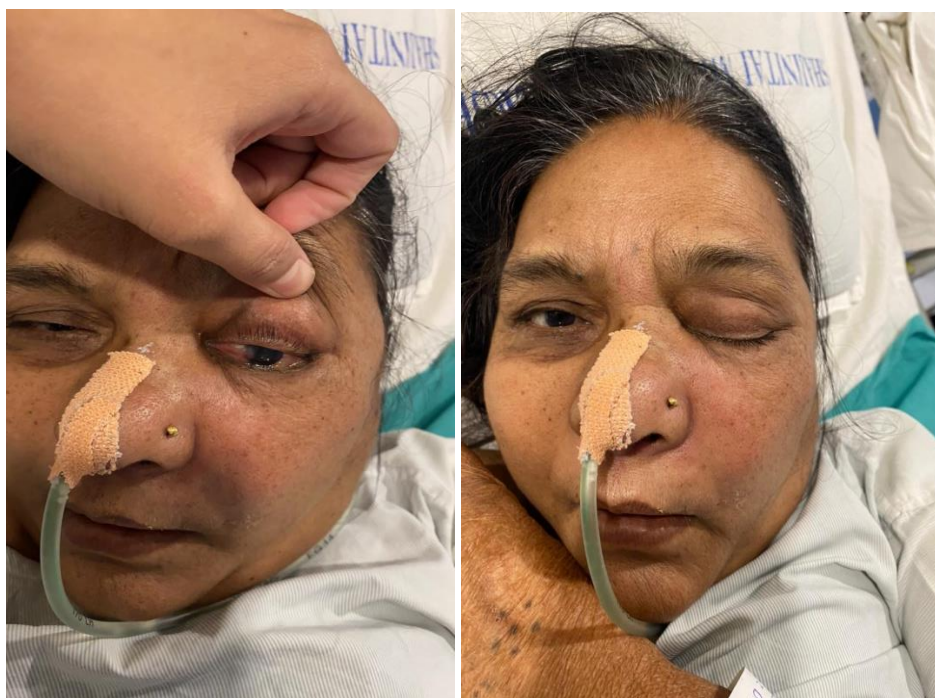## 2. CASE REPORT

An 80-year old female patient who was admitted to the medical ward of our hospital with presenting complaints of breathlessness and fever of 5 days duration on initial. As the patient was maintaining saturation on room air and clinically better she was discharged on oral medication after 5 days. After 3 days of discharge the patient presented again in the emergency department with complaints of drooping of left angle of mouth, difficulty in articulation of words and doubling of vision and complaints of vomiting and headache since 1 day. The patient was a known case of systemic hypertension on medication for 3 years and known case of Diabetes Mellitus since 6 months on treatment.

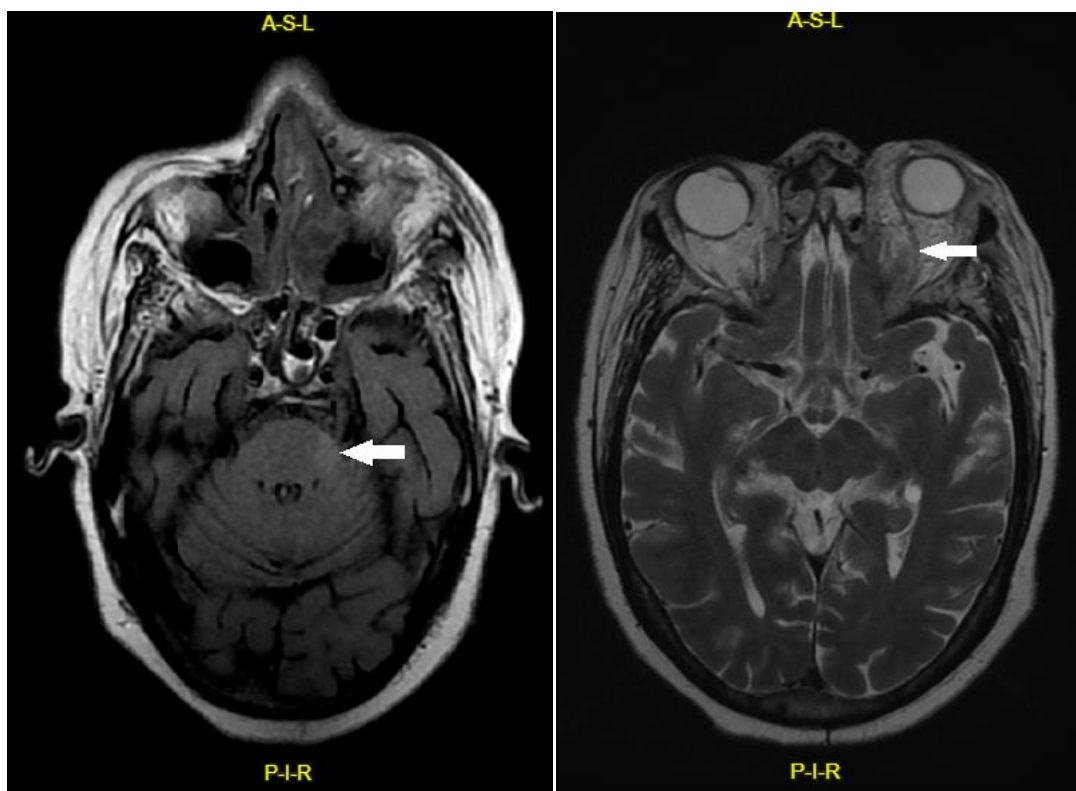
On examination, the patient was conscious and oriented. Her BP was 140/80 mmHg, the pulse of 110 beats per minute, pallor was absent, no pedal edema, no icterus, and respiratory rate of 18 per minute. Central nervous system examination revealed no abnormalities. Though on peripheral nervous system examination there was loss of movement of left eye laterally and loss of efferent part of corneal reflex with deviation of tongue to the right on protrusion and rightward deviation of mouth and loss of frowning on the left side of forehead. All these findings were consistent with lower motor neuron palsy of 7<sup>th</sup> nerve and complete palsy of 6<sup>th</sup> nerve of left side (Figure 1a). After 2 days of hospital admission the patient developed complete 3<sup>rd</sup> nerve ophthalmoplegia (Figure 1b). The rest of the systemic examination was normal.

On routine investigations, his Complete blood count showed hemoglobin as 11.1 gm/dl, mcv was 84.5 total white blood cells 28,000 per mm<sup>3</sup> and a normal platelet count. Blood urea level of 194 mg/dl, serum creatinine 4.5 mg/dl, serum Na<sup>+</sup> levels of 137 mmol/L, serum K<sup>+</sup> of 4.4 mmol/L. Her hepatic profile was within normal limits. Her thyroid hormone levels were within normal range. There was no evidence of serum Vitamin B 12 deficiency.

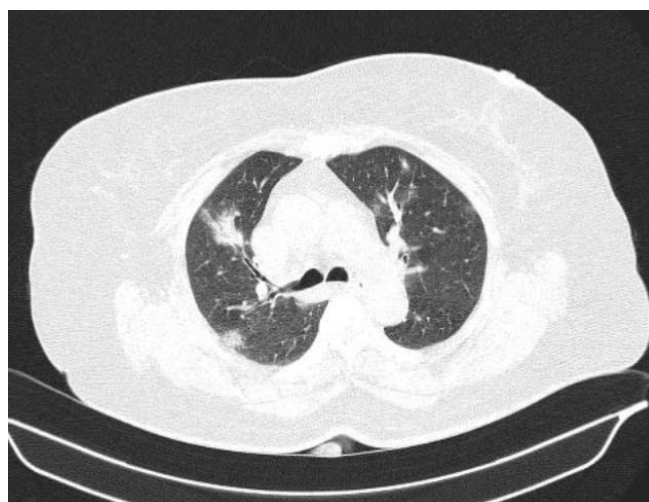
Ophthalmologist review was done to rule out papilloedema. Her examination by an otolaryngologist revealed black coloured mass in occupying most of her left paranasal sinus. As her CT brain was normal and MRI Brain with orbit was done which revealed -abnormal signal intensity in the postero-lateral aspect of Pons near the origin of 6<sup>th</sup> cranial nerve. 6<sup>th</sup> cranial nerve is irregular and thickened (Figure 2a). There is thickened lateral rectus muscle involving bulk and tendon of muscle with associated surrounding fat stranding with thickening of lacrimal gland on left side (Figure 2 b). Features suggest it is of orbital pseudo tumour. Thickening seen in both maxillary sinuses s/o mucormycosis. HRCT Chest was done which showed bilateral ground glass opacity (figure 3). The patient was started on antifungal liposomal Amphotericin B and higher antibiotics but unfortunately succumbed to respiratory complications of Covid 19.



**Figure 1** (a) Lower motor neuron palsy of 7<sup>th</sup> nerve and complete palsy of 6<sup>th</sup> nerve of left side on asking patient to look left. (b) After 2 days of hospital admission the patient developed complete 3<sup>rd</sup> nerve ophthalmoplegia.



**Figure 2 (a)** Altered signal intensity in the postero-lateral aspect of Pons near the origin of 6<sup>th</sup> cranial nerve marked by a white arrow. 6<sup>th</sup>cranial nerve is irregular and thickened. **(b)** Thickened lateral rectus muscle marked by a white arrow involving bulk and tendon of muscle with associated surrounding fat stranding with thickening of lacrimal gland on left side.



**Figure 3** Ground glass opacities visible on HRCT Thorax of the patient in bilateral lung fields

### 3. DISCUSSION

The presence of neurologic damage in Covid 19 is of recent interest and only a few cases have been reported so far. The presence of mucormycosis further complicates the situation and predisposes a patient to cranial neuropathy or not in Covid 19 will be based on studies and case reports like this and will help us understand the neural complexities of Covid complicated with a coincident infection much further. Most affected patients in mucormycosis are immunocompromised patients. It is mainly seen in diabetes mellitus which is uncontrolled, those on glucocorticoids and hemodialysis patients (Spellberg et al., 2012). Tissue necrosis from angioinvasion followed by thrombosis is attributed as the main finding in rhinocerebral mucormycosis. Black, necrotic eschars are noted in these cases.

Paranasal sinuses infection by the fungus leads to infection of the palate, cavernous sinus and sphenoid sinus. Patients may complain of blurry vision, headache, proptosis, and ophthalmoplegia inflammation around the orbit often with periorbital cellulitis, sinusitis, facial pain or numbness (Cornely et al., 2019). There has been only a few reports with isolated sixth nerve palsy associated with mucormycosis it may mainly involve the posterior sinuses with orbital apex and intracranial extension with limited involvement of anterior sinuses and nasal cavity (Jain et al., 2011). But the uniqueness here is the absence of any gross intracranial involvement like of the cavernous sinus to prove that mucormycosis alone is related to the cranial neuropathy in this patient.

Neurologic damage has been seen in Covid 19 patients probably due to retrograde neuronal spread and some reports ascribing the cause to hematogenous spread (Baig et al., 2020). Cross-reactivity between gangliosides with spikes within the COVID-19 spike-bearing and signature sugar residues of surface peripheral nerve glycolipids is a possibility. Anti-ganglioside antibodies have been investigated for and found showcasing significant values most probably in response to gangliosides within ocular motor nerves seen in post covid 19 positive cases, it may be an etiology of cranial neuropathies in COVID-19 patients. There have been other significant reports where the involvement of the hiccup centre resides in the cervical spine and brain stem which receive afferent fibers from Vagus and Phrenic nerve irritated by the bilateral lower lung infiltration due to COVID-19 has been recently reported and point towards other mechanisms by way of which Covid 19 may affect the nervous system (Talwar et al., 2021).

Viral proteins have been identified in the cranial nerves in the ninth and tenth cranial nerve in the medulla oblongata on immunohistological investigations (Matschke et al., 2020). Also histological examination of brainstem and cerebellum showcasing T lymphocyte confinement, with little involvement of the frontal lobe, in line with clinical findings pointing to an involvement of the brainstem (Mao et al., 2020). The above mechanisms seem to be the only explanation at present and open a new horizon for research and patient evaluation in Covid 19.

#### 4. CONCLUSION

Determining the prevalence of cranial neuropathies in Covid 19 is still under research and immediate identification subtle signs of cranial nerve involvement and treatment are of utmost importance in such cases as; patients of Covid 19 are already at high risk of mortality. Looking for MRI changes in brainstem serves as a warning sign and needs immediate attention.

#### Acknowledgement

We thank all the participants who have contributed in this Study.

#### Conflict of interest

The Authors have no conflicts of interest that are directly relevant to the content of this clinic-pathological case

#### Financial Resources

There are no financial resources to fund this study

#### Informed Consent

Informed Consent was obtained from the patient.

#### Author's Contribution

All the authors contributed equally to the case report.

#### Data and materials availability

All data associated with this study are present in the paper.

#### REFERENCES AND NOTES

1. Baig AM, Khaleeq A, Ali U, Syeda H. Evidence of the COVID-19 Virus Targeting the CNS: Tissue Distribution, Host-Virus Interaction, and Proposed Neurotropic Mechanisms. *ACS Chem Neurosci* 2020; 11: 995–998
2. Cornely OA, Alastruey-Izquierdo A, Arenz D, Chen SCA, Dannaoui E, Hochhegger B, Hoenigl M. Global guideline for the diagnosis and management of mucormycosis: an initiative of the European Confederation of Medical Mycology in cooperation with the Mycoses Study Group

- Education and Research Consortium. *Lancet Infect Dis* 2019; 19(12):e405–e421.
3. Desforges M, Le Coupanec A, Stodola JK, Meessen-Pinard M, Talbot PJ. Human coronaviruses: viral and cellular factors involved in neuroinvasiveness and neuropathogenesis. *Virus Res* 2014;194:145-58
  4. Dronamraju S, Nimkar S, Damke S, Agrawal S, Kumar S. Angioinvasion of anterior cerebral artery by rhinocerebralmucormycosis leading to intraparenchymal hemorrhage: A rare case report. *Medical Science* 2021; 25(111), 1088-1091.
  5. Jain S, Kumar S, Kaushal A. Rhinocerebralmucormycosis with isolated sixth nerve palsy in an immunocompetent patient. *Med J Malaysia* 2011; 66(4):376-8.
  6. Mao L, Jin H, Wang M. Neurologic manifestations of hospitalized patients with coronavirus disease 2019 in Wuhan, China. *JAMA Neurol* 2020; 77: 683–90.
  7. Matschke J, Lütgehetmann M, Hagel C, Sperhake JP, Schröder AS, Edler C . Neuropathology of patients with COVID-19 in Germany. A post-mortem case series. *Lancet Neurol* 2020; 19:919–29
  8. Riley TT, Muzny CA, Swiatlo E, Legendre DP. Breaking the mold: a review of mucormycosis and current pharmacological treatment options. *Ann Pharmacother* 2016; 50(9):747–757.
  9. Spellberg B, Ibrahim AS, Chin-Hong PV, Kontoyiannis DP, Morris MI, Perfect JR, Fredricks D. The Deferasirox-AmBisome Therapy for Mucormycosis (DEFEAT Mucor) study: a randomized, double-blinded, placebo-controlled trial. *J Antimicrob Chemother* 2012; 67(3):715–722.
  10. Talwar D, Kumar S, Madaan S, Khanna S, Annadatha A. Intractable Singultus: Atypical presentation of COVID 19. *Med Sci* 2021; 25(111), 1183-1187