

Management of deciduous molar with missing permanent successor – A case report

Niharika Gahlod^{1✉}, Arun Sajjanar², Milind Wasnik³, Sneha Khekade⁴, Nilesh Rojekar⁵, Harshita Shukla⁶

To Cite:

Gahlod N, Sajjanar A, Wasnik M, Khekade S, Rojekar N, Shukla H. Management of deciduous molar with missing permanent successor – A case report. *Medical Science*, 2021, 25(111), 1080-1083

Author Affiliation:

¹Senior Lecturer, Department of Pedodontics and Preventive Dentistry, Swargiya Dadasaheb Kalmegh Smruti Dental College and Hospital, Wanadongri, Nagpur, Maharashtra, India; Email: niharika.gahlod@gmail.com

²Professor and Head of the Department, Department of Pedodontics and Preventive Dentistry, Swargiya Dadasaheb Kalmegh Smruti Dental College and Hospital, Wanadongri, Nagpur, Maharashtra, India; Email: arunsajju@gmail.com

³Senior Lecturer, Department of Pedodontics and Preventive Dentistry, Swargiya Dadasaheb Kalmegh Smruti Dental College and Hospital, Wanadongri, Nagpur, Maharashtra, India; Email: milind.wasnik@sdkdentalcollege.edu.in

⁴Senior Lecturer, Department of Pedodontics and Preventive Dentistry, Swargiya Dadasaheb Kalmegh Smruti Dental College and Hospital, Wanadongri, Nagpur, Maharashtra, India; Email: snehakhekade@2290@gmail.com

⁵Post graduate Student, Department of Pedodontics and Preventive Dentistry, Swargiya Dadasaheb Kalmegh Smruti Dental College and Hospital, Wanadongri, Nagpur, Maharashtra, India; Email: rojekarnilesh010@gmail.com

⁶Post graduate Student, Department of Pedodontics and Preventive Dentistry, Swargiya Dadasaheb Kalmegh Smruti Dental College and Hospital, Wanadongri, Nagpur, Maharashtra, India; Email: harshitashukla10@gmail.com

✉Corresponding author

Senior Lecturer, Department of Pedodontics and Preventive Dentistry, Swargiya Dadasaheb Kalmegh Smruti Dental College and Hospital, Wanadongri, Nagpur, Maharashtra, India; Email: niharika.gahlod@gmail.com

Peer-Review History

Received: 31 March 2021

Reviewed & Revised: 02/April/2021 to 28/April/2021

Accepted: 29 April 2021

Published: May 2021

Peer-review Method

External peer-review was done through double-blind method.

ABSTRACT

Deciduous teeth are present in the oral cavity for limited period of time, normally they exfoliate and the successor teeth attain their respective position in the oral cavity. Two-third of root is resorbed physiologically and then it exfoliates. But in the tooth without permanent successor this process is bit slower as compared to the teeth with permanent successor. Therefore, execution of treatment planning differs in both the cases. This case report explains one of the treatment plan related to the management of missing permanent successor.

Keywords: missing permanent successor, over-retained teeth, physiological resorption, gutta percha obturation

1. INTRODUCTION

The period of deciduous dentition is from 6 months to 6 years. A deciduous dentition shed spontaneously when approximately three-fourths of the root of the replacing premolar has formed (Gron, 1962; Suri et al., 2004; Jain et al. 2020). When a deciduous molar persists beyond this point, it is considered over-retained. There are lot of reasons for over-retained teeth which include abnormal position of developing tooth germ, delayed root resorption, presence of supernumerary teeth, tooth ankylosis or any obstruction in the path of eruption of permanent teeth (Roy Sabri, 2008). Bigger staff & Thompson (1992) stated that the second premolar has the highest incidence of congenital absence followed by the third molar (22%) Therefore, it is advisable to maintain the second primary molar in case of a missing permanent successor. Several studies suggest that infected second primary molars with missing permanent successor could be well treated endodontically with the help of Gutta Percha obturation so as to maintain the deciduous teeth for longer period of time (Ansari and Mirkarimi, 2008).

2. CASE REPORT

A 6 years old boy visited to the department with chief complaint of pain in lower left region of jaw since 7 days. Pain was intermittent in nature which aggravates at night and on mastication and relieved on taking medication. There was no relevant history of any major illness, allergies, hospitalization



© 2021 Discovery Scientific Society. This work is licensed under a Creative Commons Attribution 4.0 International License.

and blood transfusion reported by parents. It was the first visit of the child to the dental office. The oral hygiene maintenance was done by the child under the supervision of the mother. On examination it was found that the child is in mixed dentition phase. The intra-oral findings in the child included mesial caries with deciduous central incisors (Figure 1) and pulp exposure with lower left second molar, Distal caries with lower left first molar (Figure 2) which were associated with history of night pain and as the child visited after one month the symptoms were progressed. Intensity of pain and tenderness was observed increased. Now the pain and tenderness were also observed with lower right first and second molar which was asymptomatic before one month. Also there was sinus formation was seen with lower right first molar. Patient was unable to chew food from both right and left region of the jaw.

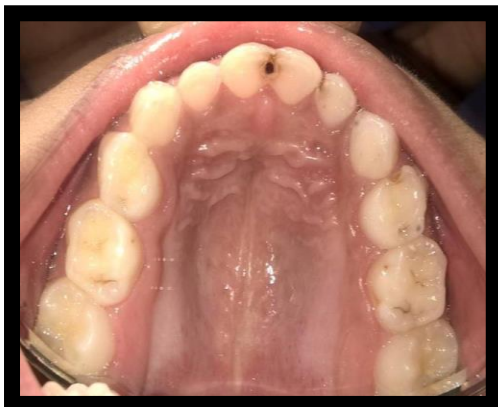

Figure 1 Maxillary arch

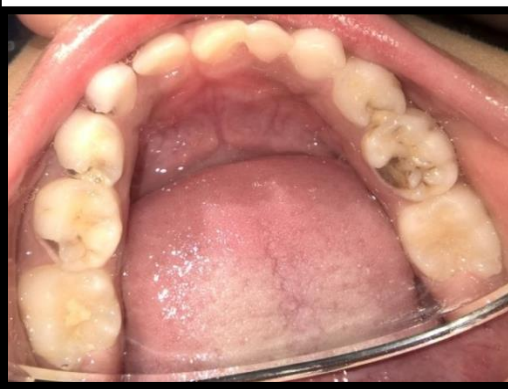

Figure 2 Mandibular arch

Radiographic examination of lower right and left posterior region comprising of deciduous first and second molars showing the proximity of the cavities to the pulp, indicating some degree of pulpal involvement (Figure 4 and Figure 5) and also revealed the absence of permanent tooth bud (Figure 6) in the region of second premolar. Intra-oral periapical radiograph of upper front region reveals the presence of caries in the proximal area involving enamel and dentine (Figure 3).

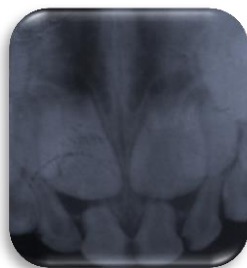

Figure 3 IOPA with 51,52,61,62




Figure 4 IOPA with 74, 75

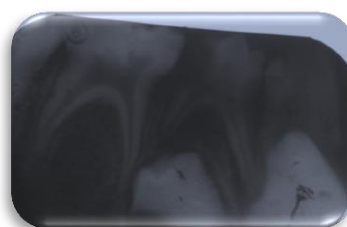


Figure 5 IOPA with 84

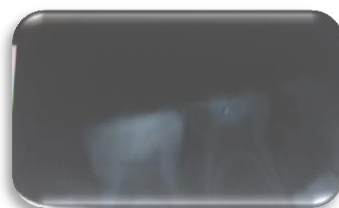

Figure 6 IOPA with 85

Dental treatment was initiated with complete oral prophylaxis and composite restoration was done with deciduous central incisors and lateral incisors in maxillary arch (Figure 7) and mandibular canine on right side. Glass ionomer restoration was done with maxillary left first and second molar and right second molar and lower right canine.

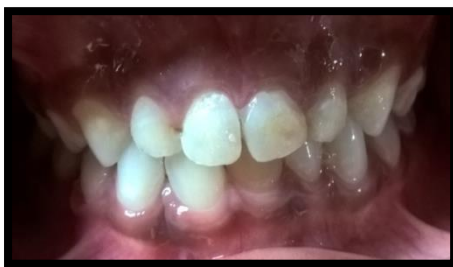

Figure 7 Composite Restoration with 51, 61

Pulpectomy was performed with 74, 75 followed by stainless steel crown (Figure 8). Root canal treatment was performed with gutta percha obturation in lower right second molar (Figure 9). Extraction was done with lower right first molar followed by Crown and loop space maintainer with lower right second molar (Figure 10). Patient was advised to avoid eating stained food stuff & stained drinks and maintains proper oral hygiene. Patient was advised to be on follow up after every 3 months.

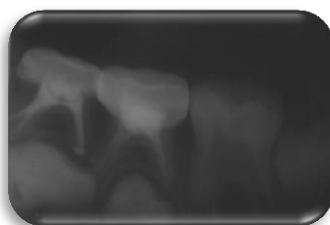


Figure 8 IOPA showing pulpectomy and stainless steel crown with 74, 75




Figure 9 IOPA showing gutta percha obturation with 85 followed by Crown and loop space maintainer

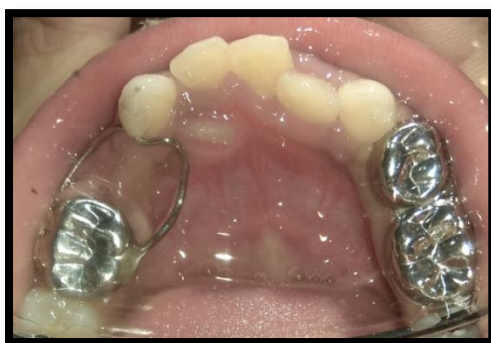

Figure 10 Post operative image of mandibular arch

3. DISCUSSION

The deciduous molar teeth are shed when approximately three-fourths of the root length of the replacing permanent premolar is formed within the alveolar bone. Deciduous molar persists or remains in its place beyond this point- over retained teeth. According to Kjaer et al., (1994) the agenesis of the permanent tooth could be caused by factors that are related either to the mucosal ectoderm, ectomesenchyme, or innervation. Vastardis (2000) stated that the genetics plays an indisputable role in the occurrence of agenesis and other anomalies in an individual. Becktor (2002), has suggested that the occurrence of agenesis was less likely caused by a general ectodermal factor.

Consequences of Retention of Primary Second Molars

It usually leads to Infra-Occlusion or Root Resorption. Some of the studies have also discussed the subject retention and ankylosis of primary teeth.

Managing Retained Primary Second Molar without a Permanent Successor

Lygidakis et al., (2009) and Parisay and Iman (2013) had proposed surgical luxation as an treatment option which is aiming to break the root ankylosis sites there by allowing the tooth to continuously erupt at its position. This will lead to the retention of teeth for longer period of time in the dental arch. Lygidakis et al., (2015) has proposed a more conservative approach by means of building of primary molars without a permanent successor in order to increase the overall tooth height and also to re-establish the normal occlusion by using PMC (performed metal crown). There are other treatment options also available that include extracting primary second molar and allowing the permanent first molar to drift mesially with the final orthodontic correction and maintaining the deciduous tooth until the patient has attained the age for the implant or any prosthetic solution.

4. CONCLUSION

Over-retained mandibular deciduous second molars are commonly encountered in clinical practice. The etiology of overretention is multifactorial, and the presence or absence of the permanent successor is an important factor in the treatment decision. It has been observed that the use of Gutta Percha point along with the ZOE mixture would enhance the roots of primary molars with missing successors to remain healthy and intact. Further long term and comparative studies are suggested to clarify more treatment options for retention of deciduous teeth with missing permanent successor.

Conflict of Interest

The authors declare no conflict of interest.

Funding

This paper received no external funding.

Informed consent

Written & Oral informed consent was obtained from the parents of the patient included in the study.

Data and materials availability

All data associated with this study are present in the paper.

REFERENCES AND NOTES

1. Ansari G, Mirkarimi. Gutta Percha Root Filling in 2nd Primary Molar Teeth with Missing Successor: A Challenging Approach; Res J Med Sci 2008; 2 (5): 251-254
2. Gron AM. Prediction of tooth emergence. J Dent Res 1962; 41:573-585.
3. Jain S, Rathi N, Thosar N, Baliga S, Bhansali P, Rathi K, Sharma N. Full mouth rehabilitation of a pediatric patient under general anesthesia-A case report. Med Sci 2020;24(101):22-25
4. Robinson S, Chan Y. New teeth from old: treatment options for retained primary teeth. Bri Dent J 2009; 207: 315-320
5. Roy Sabri. Management of over-retained mandibular deciduous second molars with and without permanent successors. World J Orthod 2008; 9:209-220.
6. Suri L, Gagari E, Vastardis H. Delayed tooth eruption: Pathogenesis, diagnosis, and treatment. A literature review. Am J Orthod Dentofacial Orthop 2004; 126:432-445
7. Tebbeb N, Zouiten S, Chafra H, Boughzala A. Pulpectomy using mineral trioxide aggregate of a nonvital primary molar with no permanent premolar successor. Endodont 2017; 29:164-8.