

## Chorangiosis of placenta: A rare case report with unusual presentation and outcome

Khalid Akkour✉

### To Cite:

Khalid Akkour. Chorangiogenesis of placenta: A rare case report with unusual presentation and outcome. *Medical Science*, 2021, 25(108), 391-394

### Author Affiliation:

Department of Obstetrics and Gynecology, College of medicine, King Saud University, Riyadh city, Saudi Arabia

### ✉Corresponding author

Consultant and Assistant professor, Department of Obstetrics and Gynecology, College of medicine, King Saud University, Riyadh city, Saudi Arabia;  
Email: kakkour@ksu.edu.sa

### Peer-Review History

Received: 03 January 2021  
Reviewed & Revised: 03/January/2021 to 09/February/2021  
Accepted: 10 February 2021  
Published: February 2021

### Peer-review Method

External peer-review was done through double-blind method.

### ABSTRACT

*Introduction:* chorangiogenesis of placenta is a rare vascular lesion that leading to abnormal CTG due to fetal hypoxia. *Case report:* We report a 33-year-old patient at 40 weeks and 6 days of gestational age presented with spontaneous rupture of membrane (SROM) with re-assuring CTG. Upon delivery, unresponsiveness boy who was later announce dead due to placental chorangiogenesis. *Conclusion:* Placental chorangiogenesis could be presented with normal CTG and lead to drastic events, which ends up by neonatal death.

**Keywords:** chorangiogenesis, placenta, hypoxia

### 1. INTRODUCTION

Placental chorangiogenesis is a rare and uncommon vascular lesion in which there is an increase number in vascular channels of the placenta. Chorangiogenesis of placental defined as presence of more than 10 capillaries in more than 10 villi in the placenta (Altshuler, 1984). Placental chorangiogenesis has been associated with maternal smoking, multiple pregnancies, and maternal diabetes (Suzuki et al., 2009). Placental chorangiogenesis has been associated with still birth and congenital anomalies (Altshuler, 1984). Placental chorangiogenesis occurred due to chronic hypoxia as a result of low oxygen transferred from maternal to fetal circulation and due to chronic hypoxia in which leading to vascular changes as a response (Suzuki et al., 2009). We report one case of placental chorangiogenesis associated which was associated with normal CTG ends up by neonatal death.

### 2. CASE REPORT

A 33 year old, gravida 5 para 3+1 patient, at 40 weeks and 6 days of gestation came to hospital. She is not known to have a medical issue with previous history of unexplained first trimester abortion treated by dilation and curettage and followed by 3 full-term spontaneous vaginal deliveries with no complications and last delivery was two years ago. Our patient presented to labor triage in our institution due to spontaneous rupture of membrane (SROM) which was clear liquor for 3 hours.

Antenatal course of current pregnancy revealed that the patient presented to our obstetric clinic late at 39 weeks of gestation and routine investigations such as complete blood count (CBC) urine analysis (UA), Renal function test,



Urine culture and virology tests all were normal, the patient's blood glucose level was 5.4 with and her hemoglobin A1c was 5.6% at 39 weeks. First Fetal scan was done late which showed no obvious anomaly and growth was 61 percentile with an estimated fetal weight of 3317gms + - 484 grams and an amniotic fluid index of 9.87 cm at 39 weeks.

At Labor triage: Patient presented clear per-vaginal leaking for 3 hours with no labor pain; she had a good fetal movement with no per-vaginal bleeding or discharge, so the patient was admitted to labor room as a case of SROM.

On examination at labor triage upon admission: Temperature: 37°C, Heart rate: 92 beats/minute, Respiratory rate: 20 breaths / minute, Blood Pressure: 115/71, Oxygen saturation: 100% on room air. Patient was vitally stable, afebrile conscious, alert, lying comfortably on the bed. Abdomen: soft lax, no tenderness. CTG: At 145- 150 beats /minute, Moderate Variability with Acceleration, no Decelerations and with no Contractions (figure 1).

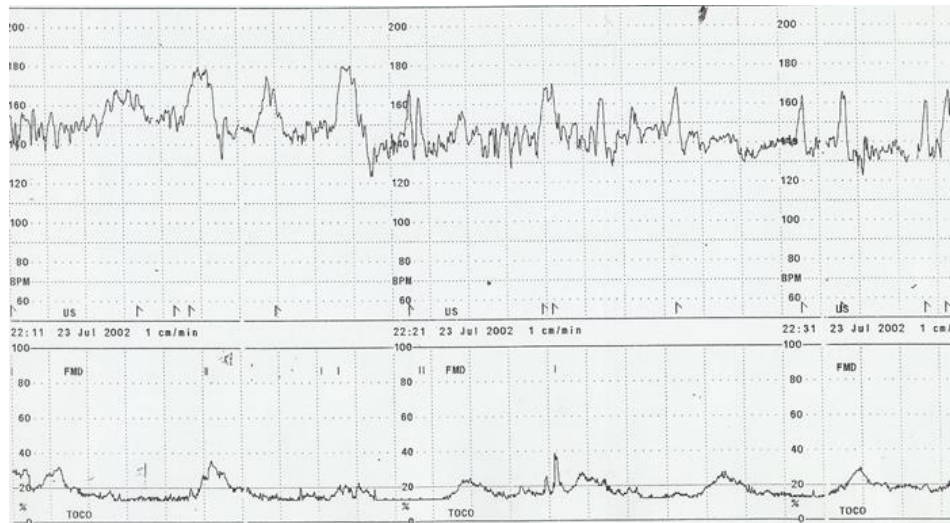


Figure 1 normal CTGs

Vaginal exam (VE): 1- 2 cm dilated internal OS, 2 cm long cervix, at -3 station, Clear liquor. After 5 hours patient started to have labor pain and upon assessment: she was vitally stable, afebrile, conscious, alert, lying comfortably on the bed.

Abdomen: soft lax, no tenderness.

CTG: At 140 b/min, Moderate Variability with no Decelerations, 3 Contractions/10 min.

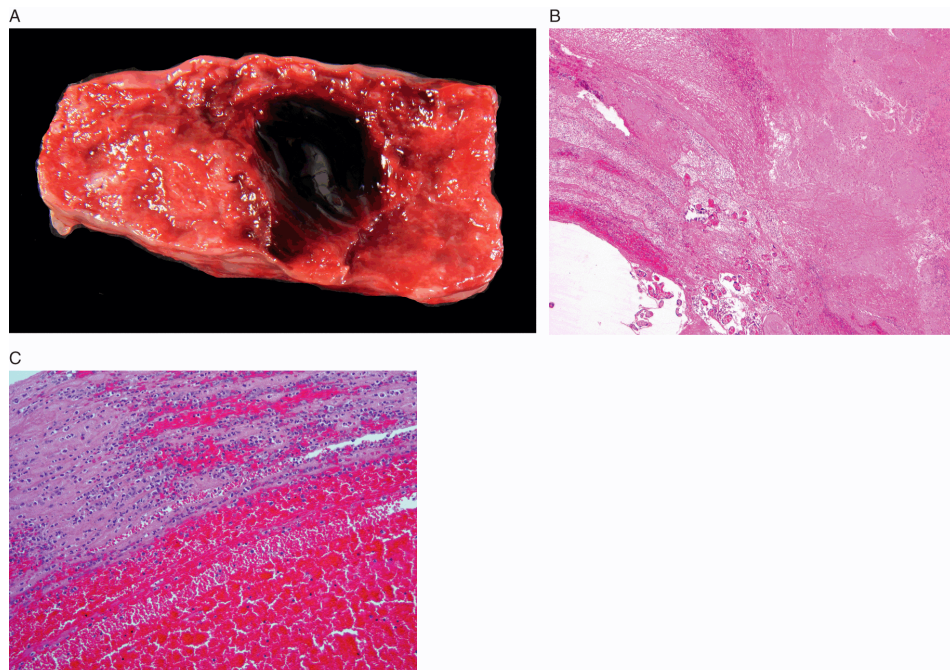


Figure 2 Cut surface of placental chorangiosis

VE: 3-4 cm dilated, 1 cm long, -3 station, mento-anterior face presentation, membrane absent- Clear liq.

So the patient shifted to labor room and started on intravenous fluid (IVF) ringer lactate at 120 ml / hour and epidural anesthesia given to the patient. After 4 hours, the patient progressed well in which VE revealed fully dilated internal OS, fully effaced cervix, at -1 station, mento-anterior face presentation.

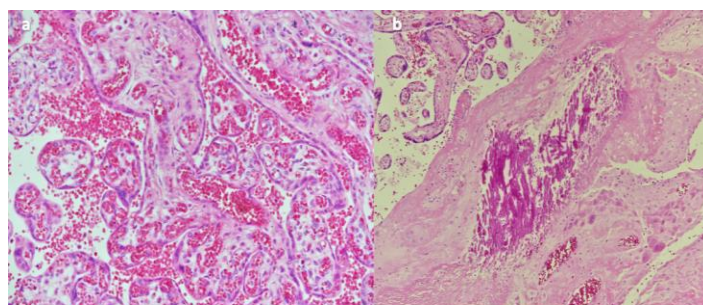
Patient remained with the same findings for 3 hours with normal CTG (figure 2) so the patient went for emergency lower segment Caesarean Section due to Failure to descent, Face mento anterior presentation at -1 station and prolonged second stage of labor. Outcome was hyperextended neck boy was delivered who was unresponsive with Apgar score of 1 and 0 at 1 and 5 minutes respectively with birth weight of 3.160 kg.

Baby was immediately intubated, 3 cycles of Epinephrine, bolus normal saline of 40 cc given; Cardiopulmonary resuscitation (CPR) continued for 15 minutes, and then the boy pronounced dead. Cord gas done upon delivery which showed marked metabolic acidosis:

*Venous blood gas:* pH : 6.82, pCO<sub>2</sub>: 55, HCO<sub>3</sub>: 7.8, ABE: 25

*Arterial blood gas:* pH: 6.75, pCO<sub>2</sub>: 87, HCO<sub>3</sub>: 7.6, ABE: 22.8

Maternal postpartum course was complicated by postpartum hemorrhage with blood loss: 2500 milliliter (ml) due to intraoperative uterine atony which managed medically. Then placenta delivered in which It consists of a singleton placenta with attached membrane and umbilical cord. The placental disc measures 17.0 x 16.0 x 2.0 cm and weighs 510 grams, the umbilical cord measuring 35.0 cm in length and 1.0 cm in diameter. The cord is trivascular, umbilical cord is centrally inserted, fetal membrane is pale and translucent and placental disc is spongy hemorrhagic. The pathological report described trivascular with no funisitis umbilical cord, Unremarkable fetal membranes and chorionic villi with foci of calcification and infarction with evidence of chorangiosis (figure 3).



**Figure 3.** Microscopic examination of the hematoxylin and eosin stained tissue sections from the placenta showed mature chorionic villi with increased number of capillaries (a). A focus of calcification was also noted (b)

### 3. DISCUSSION

Chorangiosis is a very rare Villous Capillary Lesion of Placenta, which accounts for 3 to 5 % of pregnancies will be presented with this lesion. Placental chorangiosis defined as increased vascularity of villous capillary as there is more than 10 terminal villi containing more than 10 capillaries per villous in 10 medium power fields occurring in multiple areas of the placenta (Fox Harold & Sebire, 2007).

The etiology of chorangiosis and its clinical association are not clear and well understood in literature, many reports found association with maternal, fetal and placental diseases (Gupta et al., 2006). Maternal diseases including; obesity, smoking, anemia, syphilis, maternal diabetes mellitus, pregnancy induced hypertension and preeclampsia. Fetal factors and diseases including; intrauterine growth retardation (IUGR), oligohydramnios, polyhydramnios, congenital anomalies, preterm delivery, abnormal non-stress test, low Apgar score. Placental abnormalities including; chronic villitis, placentomegaly, umbilical cord thrombus, umbilical cord knots and long umbilical cord (Manjarkhede et al., 2014; Doğan et al., 2006). 10 cases of chorangiosis in one center has been reviewed; found that majority of cases will be delivered less than 37 weeks of gestation and 60% delivered by cesarean section with low Apgar score (Doğan et al., 2006). Placental chorangiosis is associated with higher rate of cesarean section as this abnormality is associated with abnormal fetal heart rate due to prolonged fetal hypoxia because of capillary vessels abnormality (Petersen et al., 2017).

From our patient perspective, she is not known to have medical diseases that can lead to chorangiosis of placenta such as diabetes, obesity and syphilis. Obstetric ultrasound showed normal fetus with no IUGR or oligohydramnios. So the cause of

chorangiosis is not known to us in this case. Our patient presented with SROM and she developed spontaneous labour and CTG showed normal fetal heart rate. So patient was taken for cesarean section due to failure of descent despite regular spontaneous contractions and category 1 nonstress test, its ended by a bad outcome which was unreasonable till pathology report show chorangiosis and death of neonate was due to this finding. Almost all published articles on chorangiosis will be presented with abnormal fetal heart rate which leading to increase rate of cesarean section but in our case, the indication for C.S was different.

#### 4. CONCLUSION

Chorangiosis is rare placental vascular lesion that could be presented due to maternal and fetal diseases. Abnormal fetal heart rate in CTG is common findings due to prolonged tissue hypoxia but CTG could be normal like our case which ended up by neonatal death. Chorangiosis can't be identified antenatally and examination with histopathology of placenta post-partum is the only way for diagnosis. Clear examination of placental immediately post-partum is important in case of sick fetus and may give explanation about intrauterine environment of the fetus.

#### Abbreviations

CTG:	cardiactocography
SROM:	spontaneous rupture of membranes
CBC:	complete blood count
UA:	urine analysis
VE:	vaginal exam
IVF:	<i>in-vitro</i> fertilization

#### Funding

This study has not received any external funding.

#### Conflict of Interest

The authors declare that there are no conflicts of interests.

#### Informed consent

Written & Oral informed consent was obtained from all individual participants included in the study. Additional informed consent was obtained from all individual participants for whom identifying information is included in this manuscript.

#### Data and materials availability

All data associated with this study are present in the paper.

#### REFERENCES AND NOTES

- Altshuler G. Chorangiomas. An important placental sign of neonatal morbidity and mortality. *Arch Pathol Lab Med.* 1984; 108(1):71-4.
- Doğan BJS, Oler E, Armistead B, Elsayed NA, Weinberger DR, Bernier R, Burd I, Kapur R, Jacobsson B, Wang C, Mysorekar I, Rajagopal L, Adams Waldorf KM. The fetal origins of mental illness. *Am J Obstet Gynecol.* 2019; 221(6):549-562.
- Foxharold ED, Mithal LB, Otero S, Azad HA, Miller ES, Goldstein JA. Placental Pathology in COVID-19. *Am J Clin Pathol.* 2020; 154(1):23-32.
- Gupta R, Nigam S, Arora P, Khurana N, Batra S, Mandal AK. Clinico-pathological profile of 12 cases of chorangiomas. *Arch Gynecol Obstet.* 2006; 274(1):50-3.
- Manjarkhede H, Karimi Z, Akbarzadeh-Jahromi M, Asadian F. Association of placental chorangiomas with pregnancy complication and prenatal outcome: a case-control study. *BMC Pregnancy Childbirth.* 2021; 21(1):99.
- Petersen SS, Khangura R, Davydov D, Zhang Z, Sangha R. Placental Chorangiomas: Increased Risk for Cesarean Section. *Case Rep Obstet Gynecol.* 2017; 2017:5610945.
- Suzuki K, Itoh H, Kimura S, Sugihara K, Yaguchi C, Kobayashi Y, Hirai K, Takeuchi K, Sugimura M, Kanayama N. Chorangiomas and placental oxygenation. *Congenit Anom (Kyoto).* 2009; 49(2):71-6.