

Role of intra operative ultrasonography for real time localization in operative procedures for surgery, brain surgery and spinal surgery

Upadhyay PK¹, Tiwary G²

1. Head, Department of Neurosurgery, Institute of Human Behavior And Allied Sciences (IHBAS) Government of Delhi, Academic program of University of Delhi, Delhi, India
 2. Consultant Pathologist, CHL centre Delhi, India

* **Corresponding author:** Type VI Q. no 05 Institute of Human Behaviour and allied sciences, Dilshad Garden, Govt of NCT of Delhi, New Delhi 110095, E-mail: upadhyaypk5@yahoo.co.in

Received 19 July; accepted 26 September; published online 08 October; printed 28 October 2013

ABSTRACT

Intra operative ultrasonography guides the surgeon about exact intra operative position instantly and also defines the boundaries of mass lesion for excision during operation and also visualizes movement of lesion during surgery. It also provides information about the other nearby land marks for example ventricles, tentorium, lobes cerebellum, falx etc. It is cheap tool for navigation in intra cranial as well as abdominal organs etc and can be utilized for use in peripheral, rural centers & distant military outpost etc.

Key words: Neuronavigation, Brain tumours, ultrasonography, Image guided surgery.

Abbreviation: USG-Ultrasonography, IGS -Image guided surgery.

To Cite This Article

Upadhyay PK, Tiwary G. Role of intra operative ultrasonography for real time localization in operative procedures for surgery, brain surgery and spinal surgery. *Medical Science*, 2013, 2(5), 17-19

1. INTRODUCTION

Localization of lesions for operative interventions is becoming more & more available in surgical practice including neurosurgery. These have become a standard form of systems and equipments in the operation theatres including neurosurgical operative suits for planning and guidance of surgery including brain & spinal surgeries in worldwide scenario. It gradually being utilized by the higher, tertiary centers to distant, rural and outposts of military medical services. Many surgical operative rooms including neurosurgeons are utilizing the facilities an replacement and substitution of costly and non portable intra operative MRI (Upadhyay et al. 2010). In brain surgeries or surgery of any solid organism including abdominal and spinal lesions after start of surgery leads to organ shifts which make operations based on preoperative images obsolete (Unsguard et al. 2006). Therefore the need for intra operative real time feedback has become more important. Many intra operative guiding systems have been developed including intra operative Magnetic Resonance Imaging (Brain suit) to solve these problems as well as image guiding during surgical procedures (Albayrak et al. 2004; Nimsy et al. 2004). There are other instruments also but they are expensive while real time USG over comes both these problems during surgery & guides the surgeon to whole extent & position of tumor in real time & help excise the tumor, mass or hematoma in brain or spine in toto and confirmation of the same at the end of the operation itself. Furthermore it's cheap, portable

& accurate therefore there is much more interest at Present in real time intra operative USG guiding systems for neurosurgical procedures including its 3D versions.

2. MATERIALS & METHODS

Ten brain tumor cases were operated and a real time neuronavigation system was used. Multiple images are taken during surgery at start of the procedures and at the end of the procedures (Figures 1 & 2). At the end the extent of tumor excision was assessed and if there was any part of tumor left (Figure 3 & 4). Residual tumor are further excised according to the situation. Post operative CT or MRI images done and compared with the extent shown in intra operative USG to correlate the extent of tumor excision & reliability With CT or MRI imaging.

3. DISCUSSION

The USG images may be as good as if not superior to good quality MRI Images (Babcock et al. 1992; Bonsanto et al. 2001; Bochoz et al. 1997). The only disadvantage is that it requires burr hole or craniotomy to produce the picture but frequently USG imaging may easily be performed through the same opening as used for resection of tumors (Unsguard et al. 2006). Although neurosurgeons are familiar with the MRI images than the USG because they interpret MRI images in every day clinical practice, but Neurosurgeons who have started using USG & want to explore the possibilities, learnt the new technique very quickly (Unsguard et al. 2006). Many groups have reported

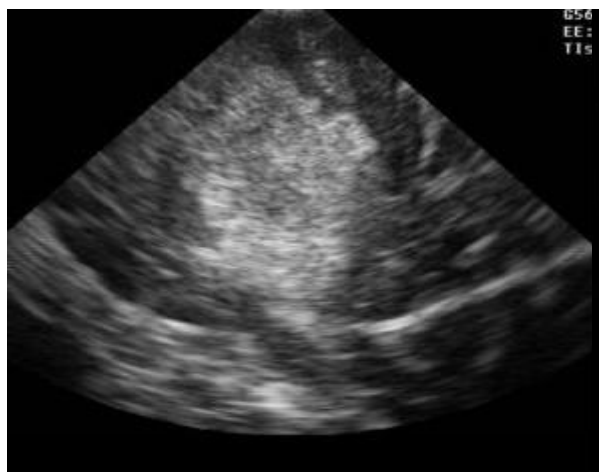


Figure 1
Pre excion 1st case

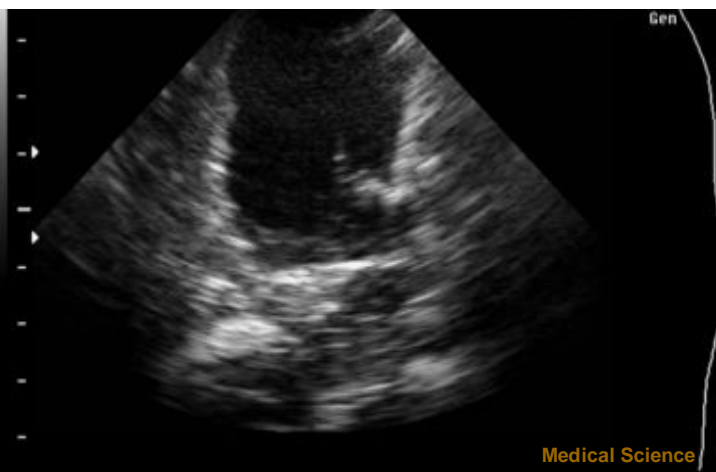


Figure 2
Post excision 1st case IOUS

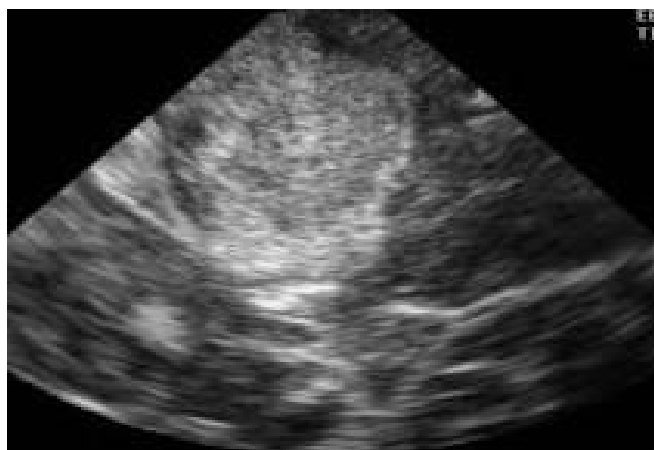

Figure 3
Pre excision 2nd case

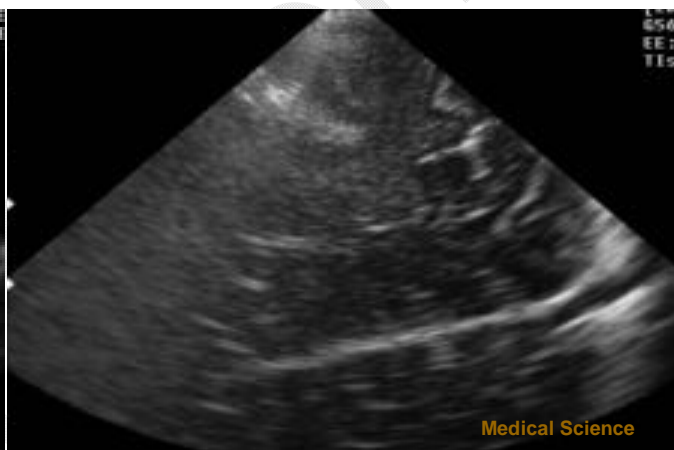


Figure 4
Post excision 2nd case

the clinical efficacy of using USG to get intra operative updates for surgical guidance and control (Chacko et al. 2003; Comeau et al. 1998; Dohermann et al. 2001; Griffith et al. 2004; Gronnungsacter et al. 1996, Jodicke et al. 1998; Koivukangas et al. 1993; Woydt et al. 2001). Its integration into some form of neuronavigation system (Jodicke et al. 2004) will further improve its usefulness. Thus USG guided neurosurgery represents a handy, reliable and relatively low risk procedure for the treatment of intra axial brain tumors (Russelli et al. 1993). Real time intra-operative ultrasonography (USG) in the surgical lesions is economical, fast, accurate and portable (Upadhyay et al. 2011). In this series it was found that the intra operative imaging using USG and thus expected extent of excision or decompression matched with post operative imaging using CT & MRI imaging.

4. RESULT

FUTURE ISSUES

In future development smaller probes need to develop so that window size required may be decreased. It may also be developed to be secured at the tip of an endoscopic instrument so that it can traverse to depth or in ventricle of in abdominal cavity distant from the place of entry.

DISCLOSURE STATEMENT

There is no financial support or nay other support for this work from any agency.

Thus in the series the real time intraoperative USG helped to guide the extent of the tumors & extent of excision or decompression of the tumors and correlated very well with the post operative CT or MRI imaging.

5. CONCLUSION

Some form of neuronavigation system is definitely required in present day neurosurgical procedures to certify the extent of tumor resection or decompression and also to over come the problems of brain shifted during procedures. It will help the surgeons to avoid litigations. Intra operative real time USG is proving to be very useful, contemporary, and cheap portable alternative as against very costly & cumbersome alternatives which also provide as good picture and guidance as other neuronavigational systems if not better. It can also be performed repeatedly & is portable so that the same machine may be utilized in multiple Operation theatre (OT)'s in the same OT complex.

ACKNOWLEDGMENT

Much thanks to Kartikeya for computer work and Ms Kritika for help in developing photographs and clerical assistance towards the successful completion of this study.

REFERENCES

1. Albayrak B, Samdani AF, Black PM. Intra-operative magnetic resonance imaging in neurosurgery. *Acta Neurochir (Wien)*, 2004, 146, 543-556
2. Babcock DS, Barr LL, crone KR. Intra operative use of ultrasound in the Pediatric neurosurgical patient. *Paediatric Neurosurgery*, 1992, 18, 84-91
3. Bochoz RD, Yeh DD, Trobaugh J, Mc durmont LL, Sturm CD, Baumann C, Henderson JM, Levy A, Kessman P. The correction of stereotactic inaccuracy caused by brain shift using an intra operative ultrasound device. *Cvrmed-Mrcas*, 1997, 459-466
4. Bonsanto MM, Metzner R, Aschoff A, Tronnier V, Kunze S. Initial experience with an ultrasound-integrated single-rack neuronavigation system. *Acta Neurochir (Wien)*, 2001, 143, 1127-1132
5. Chacko AG, Kumar NKS, Chacko G, Athyl R, Rajshekher V. Intraoperative ultrasound in determining the extent of resection of parenchymal brain tumours-a comparative study with computed tomography and histopathology. *Acta Neurochir (Wien)*, 2003, 145, 743-748
6. Comeau RM, Fenster A, Peter TM. Intraoperative US in interactive image guided neurosurgery. *Radiographics*, 1998, 18, 1019-1027
7. Dohermann GJ, Rubin JM. History of Intraoperative US in Neurosurgery. *Neurosurg Clin N Am*, 2001, 12, 155-166
8. Griffith S, Pozniak MA, Mitchell CC, Ledwidge ME, Dempsey R, Peters A, Taylor E. Intraoperative ultrasonography of intra cranial arteriovenous Malformation- How we do it. *J ultrasound Med*, 2004, 23, 1065-1072
9. Gronningsaeter A, Unsgard G, Ommedal S, Angelsen BA. Ultrasound guided neurosurgery: a feasibility study in the 3-30MHz frequency range. *Brit J Neurosurg*, 1996, 10, 161-168
10. Jodicke A, Deinsberger W, Krite A, Boker DK. Intraoperative ultrasonography: an approach to register brain shift using multidimensional image processing. *Minim Invasive Neurosurg*, 1998, 41, 13-19
11. Jodicke A, Sringer T, Boker DK. Real time integration of ultrasound into neuronavigation: technical accuracy using a light emitting-diode-based navigation system. *Acta neurochir (Wien)*, 2004, 146(11), 1211-20
12. Koivukangas J, Louhisalmi Y, Alakuijala J, Oikarinen J. Ultrasound controlled-neuronavigator-guided brain surgery. *J neurosurg*, 1993, 79, 36-42
13. Nimsy C, Ganslandt O, Von Keller B, Romstock J, Fahlbusch R. Intra operative high field-strength MR imaging implementation and experience in 200 patients. *Radiology*, 2004, 233, 67-78
14. Russell R, Iacoangeli M, Pentimalli L, Prezioso A, Scerati M, Rossi GF. Intra operative real time ultrasonography in the microsurgical removal of subcortical or deep-seated brain tumours. *Acta chir Belg*, 1993, 93(4), 185-7
15. Unsgard G, Rygh OM, Muller TB, Kolstad F, Lindseth F, Nagelhus TA. Intra-Operative 3D ultrasound in Neurosurgery. *Acta Neurochir (Wien)*, 2006, 148, 235-253
16. Upadhyay PK, Tiwary G. Real-time intraoperative ultrasonography in the surgical resection of brain lesions: A cheap, effective, and quick alternative. *J Neurosci Rural Pract*, 2010, 1(2), 127-128
17. Upadhyay PK, Tiwary G. Use of real time intra-operative ultrasonography (USG) in the surgical lesions is economical, fast, accurate and portable. *Jams*, 2011, 27-30
18. Woydt M, Krone A, Soerensen N, Roosen K. Ultrasound guided neuronavigation of deep-seated cavernous haemangiomas; clinical result and navigation techniques. *Brit J Neurosurg*, 2001, 15, 485-495