



Morphological and histopathological description of *Myxobolus niger* n. sp. infecting gills of a cold water native cyprinid fish, *Schizothorax niger* from Wullar Lake (India)

Dar SA¹, Kaur H^{3*}, Chishti MZ²

1. Research Scholar, Department of Zoology and Environmental Sciences, Punjabi University Patiala (India)
2. Professor Emeritus, Centre of Research for Development, University of Kashmir, Srinagar (India)
3. Associate professor, Department of Zoology, Panjab University, Chandigarh (India)

*Corresponding author: Dr. Harpreet Kaur email: harpreetbimbra@gmail.com

Publication History

Received: 7 April 2016

Accepted: 29 April 2016

Published: 12 May 2016

Citation

Dar SA, Kaur H, Chishti MZ. Morphological and histopathological description of *Myxobolus niger* n. sp. infecting gills of a cold water native cyprinid fish, *Schizothorax niger* from Wullar Lake (India). *Species*, 2016, 17(55), 109-118

Publication License



This work is licensed under a Creative Commons Attribution 4.0 International License.

General Note

Article is recommended to print as color digital color version in recycled paper.

ABSTRACT

The study was aimed to isolate myxozoan parasites infecting the native carp *Schizothorax niger* (Heckel) commonly called chush collected from fresh water ecosystems of Wullar Lake. Various organs were studied for the presence myxozoan infection. Results revealed prevalence rate of 20% infected with *Myxobolus niger* n. sp. Parasitological examination was done under stereozoom binocular microscope which revealed multiple minute plasmodia on the gills which on rupturing liberated myxospores. Identification upto species level was done on the basis of morphological and morphometric attributes of the myxospores in fresh and in stained preparations. Myxospores of *M. niger* n. sp. were ovoidal or subspherical in frontal view, having broad anterior end and narrow rounded posterior measuring 6.66 x 5.0µm. Polar capsules two, equal, oval in shape with pointed anterior end, measuring 3.33x1.66

Dar et al.

Morphological and histopathological description of *Myxobolus niger* n. sp. infecting gills of a cold water native cyprinid fish, *Schizothorax niger* from Wullar Lake (India), *Species*, 2016, 17(55), 109-118,

www.discoveryjournals.com

© 2016 Discovery Publication. All Rights Reserved

µm. Parietal folds and intercapsular process (ICP) absent. Sporoplasm agranular, homogeneous and hemispherical. Sporoplasm agranular, homogenous with a nucleus measuring 0.9µm in diameter. Iodinophilous vacuole present, measuring 1.2µm in diameter.

Key Words: *Schizothorax niger*; *Myxobolus nigeriae*; Wullar Lake, native carp

1. INTRODUCTION

Myxozoans are the members of phylum Cnidaria, parasitic in nature infecting fish as definitive host both in natural and farmed environments (Okamura et al., 2015). Many species have been recorded to cause serious damage to economically important fresh water and marine fish. Most of the infections do not cause any symptoms however many are well known for the serious diseases in trouts, salmon and carps (Lom and Dykova, 1992). Most abundant among the myxozoans are species belonging to the genus *Myxobolus* with as many as 905 species reported worldwide (Eiras et al., 2014) and is the most dominant group among the clade of Cnidarians. With the increasing knowledge of molecular biology and characteristic features such as host, organ and tissue specificity, the misidentification and classification of myxosporean have been resolved (Atkinson et al., 2015).

Kashmir Himalayas the northern part of India having the richest freshwater ichthyofauna especially the local snowtrout which is highly valuable and cheap food fish in this region. This fish occurs in both lotic and lentic water bodies. Various studies related to different parasitic groups have been done on these fishes but no substantial work on myxozoan fauna has been worked out. In North India many species of myxozoan parasites were recorded from freshwater fishes of wetlands of Punjab (Kaur and Singh, 2008, 2009, 2010a,b, 2011a-f, 2012a,b; Singh and Kaur, 2012a-c, 2014a, 2015; Kaur et al., 2013a,b, 2014a,b; Kaur and Attri, 2015).

Therefore, the present study was aimed to study myxosporean parasites of *S. niger* in Wullar Lake (J&K).

2. MATERIAL AND METHODS

Live specimens of *Schizothorax niger* were collected from Wullar Lake in Kashmir (India) using gill nets and from local fish markets around the study sites. The live fishes were transported to the Parasitology laboratory at Center of Research for Development, COD, University of Kashmir, Srinagar, India. The eyes, gills, fins, scales, intestine, visceral organs, and pericardial cavity were examined for myxozoan parasites. Ziehl-Neelsen and Giemsa stains were used to study the myxospore morphology. Identification up to generic level was done with the help of the keys given by (Lom and Dykova, 2006 and Kaur and Singh, 2012a). Species description was prepared according to the guidelines of (Lom and Arthur, 1989). For histopathology, infected gills were cut into small pieces and fixed in Bouin's fixative. Tissue samples were dehydrated in ascending grades of ethanol, cleared in xylene, embedded in paraffin wax, sectioned at 7–8µm thickness and stained with Luna's staining method. This technique demonstrated the location of cysts within the gills and therefore was considered useful in histological diagnosis of the myxosporean parasites. The location of myxosporean plasmodia in different areas of the gills were categorized into types according to Molnar (2002) such as Intralamellar-epithelial (LE) type; 2. Intralamellar-vascular (LV) type; 3. Intrafilamental-vascular (FV) type; 4. Plasmodium located in the gill arch (AC) type. The gill plasmodial index (GPI) was calculated on the basis of number of plasmodia present per gill (one side) visible under the stereozoom binocular microscope and with the naked eye (Kaur and Attri, 2015) 0 - 0 (no infection-0); 1-5 (light infection-1); 5-10 (moderate infection-2); 10-20 (heavy infection-3); 20-50 or more (severe infection-4). Categorization of plasmodia on the basis of size (Kaur and Katoch, 2016).

Type A. Plasmodia visible under binocular microscope size range 40-50 µm

Type B. Plasmodium visible under stereozoom size range 0.2-0.5mm

Type C. Plasmodia visible with naked eye size range 1.5-3.0mm

3. RESULTS

Myxobolus nigeriae n. sp.

Plasmodia

Minute, visible under binocular microscope round to ovoid (Fig. 2), measure 80-100 µm in diameter (Fig. 4), present in gill lamellae (intralamellar vascular type, LV₃), histozoic, 3–5 in number per gill, 100-125 myxospores per plasmodium (Fig. 1). Clinical symptomatology indicated mucous laden gills.




Figure 1. Photomicrograph of infected gills of *Schizothorax niger* showing plasmodia of *Myxobolus nigeriae* n. sp.

Taxonomic Summary

Host: *Schizothorax niger* (Heckel) vern. chush; common name: snowtrout (Cyprinidae)

Locality: Wullar lake, Kashmir Himalayas

Altitudinal zone: 1582m

Type Material: Paratypes are myxospores stained by Ziehl-Neelsen and Iron-haematoxylin, deposited in the Parasitology Laboratory, Department of Zoology and Environmental Sciences, Punjabi University, Patiala, India. Slide no. S/ZN/01.05.2016 and S/G/01.05.2016

Site of Tissue Development: Gill lamellae (Intralamellar vascular type, LV₃)

Prevalence of Infection: 20% (4/20)

Clinical Symptomatology: Mucous laden

Pathogenicity: Distortion of gill lamellae, lifting of lamellar epithelium

Gill Plasmodium Index (GPI): 2 (moderate infection)

Type of Plasmodium: A (Plasmodium visible under binocular microscope, size range 20-200 μm)

Etymology: The specific epithet '*nigeriae*' is based on the specific name of the fish host

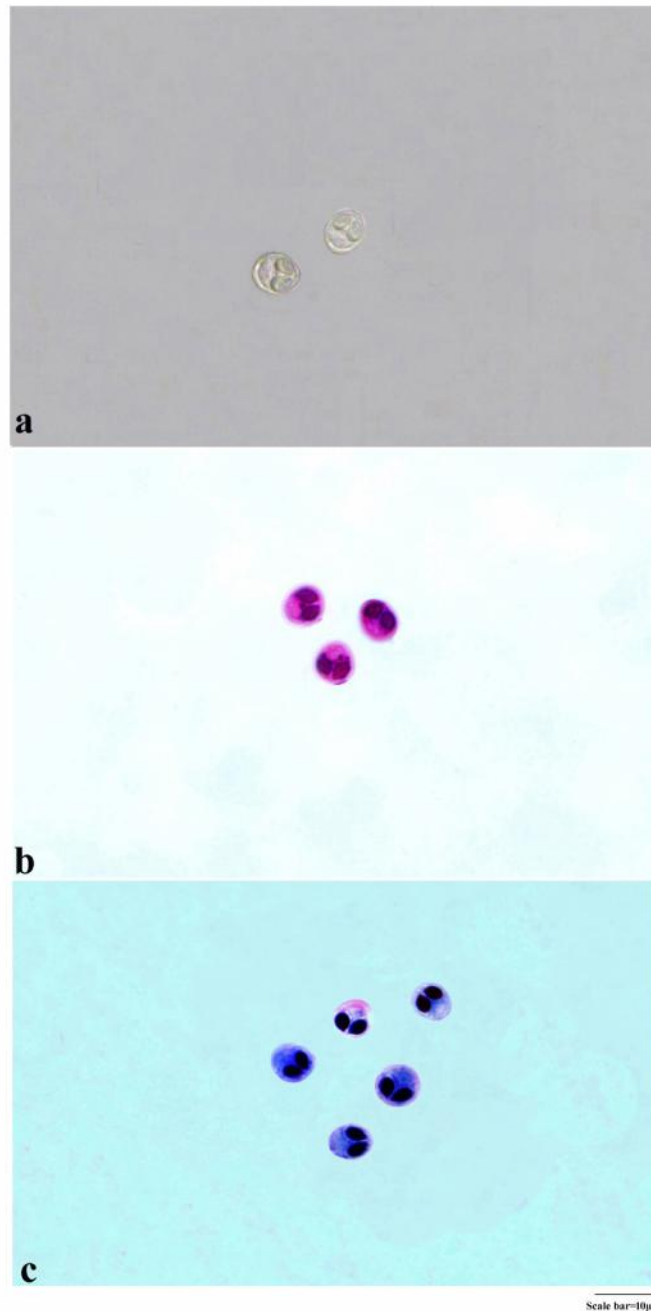


Figure 2. *Myxobolus nigeriae* sp. nov.
a. Fresh myxospores
b. Myxospores stained in Ziehl-Neelsen
c. Myxospores stained in Giemsa

Description of Myxospore of *M. nigeriae* n. sp.

(Measurements based on 9-10 myxospores in frontal view), (Table I)

Myxospores measure $6.66 \times 5.0 \mu\text{m}$, ovoidal or subspherical in frontal view, having broad anterior end and narrow rounded posterior end. Shell valves $0.6 \mu\text{m}$ in thickness and symmetrical. Sutural line curved and distinct. Parietal folds absent. Polar capsules two, equal, oval in shape with pointed anterior end, measuring $3.33 \times 1.66 \mu\text{m}$, positioned anteriorly inside the myxospore body cavity.

Dar et al.

Morphological and histopathological description of *Myxobolus nigeriae* n. sp. infecting gills of a cold water native cyprinid fish, *Schizothorax niger* from Wullar Lake (India), Species, 2016, 17(55), 109-118,

www.discoveryjournals.com

© 2016 Discovery Publication. All Rights Reserved

Polar filaments form 5 coils placed parallel to the polar capsule axis. Intercapsular process (ICP) absent. Sporoplasm agranular, homogeneous and hemispherical. Sporoplasmic agranular, homogenous with a nucleus measuring 0.9µm in diameter. Iodinophilous vacuole present, measuring 1.2µm in diameter.

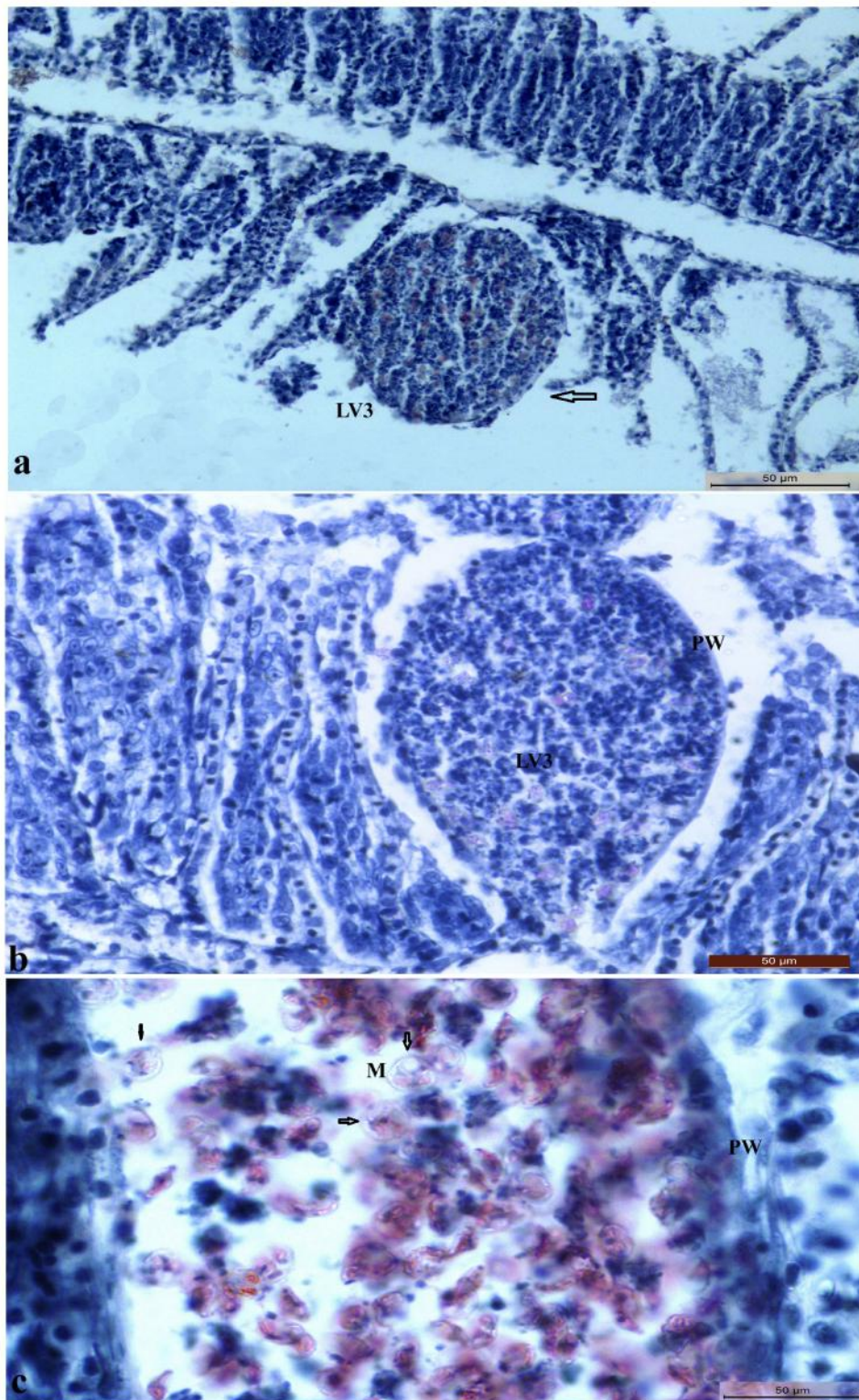
Table I Measurements (µm) and ratio of *M. nigeriae* n. sp.

Characters	Range	Mean Values	SD
LS	6.3-6.9	6.66	0.3
WS	4.8-5.2	5.0	0.2
LPC	3.1-3.5	3.33	0.2
WPC	1.5-1.7	1.66	0.1
Ratio: LS/WS		1.33	
ICP		Absent	
NC		5	
Parietal folds		Absent	

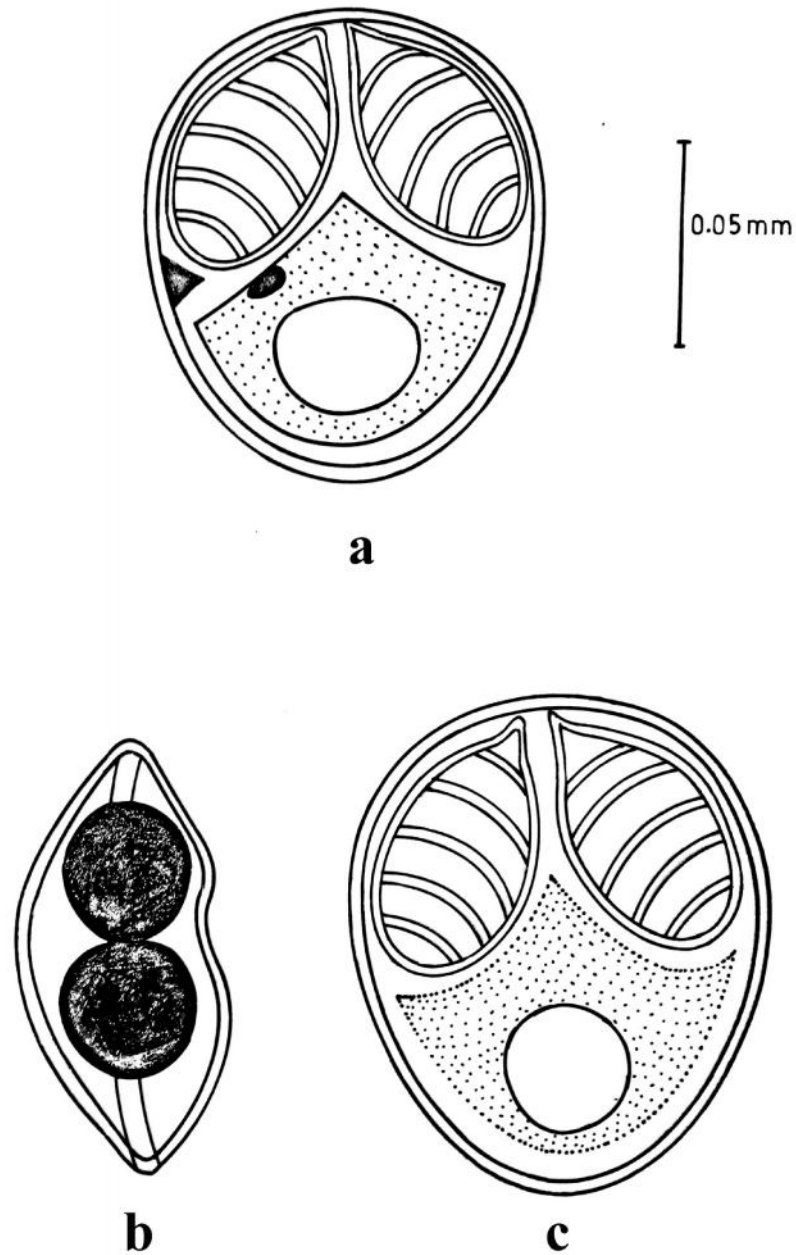
Table II Comparative description of *M. nigeriae* n. sp. with morphologically similar species (measurements are in micrometer)

Species	Host	Site of Infection	Locality	Myxospore size	Polar capsule size	ICP
<i>M. nigeriae</i> n. sp. (Present study)	<i>Schizothorax niger</i>	Gill lamellae	J&K (India)	6.66 × 5.0	3.33×1.66	Absent
<i>M. eirasi</i> Kaur and Singh (2009)	<i>Cirrhinus mrigala</i>	Caudal fin	Punjab (India)	8.6 × 6.7	3.2×1.57	Absent
<i>M. impressus</i> Miroshnichenko (1980)	<i>Barbus barbus</i>	Fin, Gills	Ukraine	12×10	6.2×3.4	Present
<i>M. indirae</i> Kundu (1985)	<i>Cirrhinus mrigala</i>	Head Cartilage, Tail fin	West Bengal (India)	12.6×9.6	4.7×2.2	Absent
<i>M. crucifilus</i> (Qadri,1962d)	<i>Labeo fimbriatus</i>	Gills	Andra Pradesh (India)	9.5×8.3	4.0-4.5	Absent
<i>M. nodulointestinalis</i> Masoumian <i>et al.</i> (1996)	<i>Barbus sharpeyi</i>	Intestinal wall	Iran	12.6×8.1	3.6×2.4	Present
<i>M. punjabensis</i> Gupta and Khera (1989)	<i>Labeo dyocheilus</i>	Gills, Fin	Punjab (India)	10.86×10.64	5.72× 4.4	Present
<i>M. sushmii</i> Kaur and Singh (2010c)	<i>Labeo rohita</i>	Eye ball	Punjab (India)	9.6 × 8.3	4.70× 3.20(L) 3.10× 2.0(S)	Present
<i>M. blicae</i> Donec and Tozzyakova (1984)	<i>Blicca bjoerkna</i>	Gill filaments	Hungary	12.4×10	6.2×3.4	Present
<i>M. vanivilasae</i> Seenappa and Manohar (1980)	<i>Cirrhinus mrigala</i>	Below scale, Muscles	Karnatka (India)	9×8	3.1×2.3	Present

ICP- intercapsular process



(Figure 3) Histopathology of gills of *S. niger* infected with *M. niger* n. sp.
 a. Section of gill lamellae of *Schizothorax niger* showing LV3 type plasmodium (100x)
 b. Section of LV3 type plasmodia showing myxospores (M) enclosed in plasmodium (400x)
 c. Magnified view of plasmodia showing thick cellular plasmodial wall (PW) and mature myxospores (M) (1000x)



(Figure 4) Line drawings of myxospores of *M. nigeriae* n. sp.
 a. Myxospore stained in Ziehl- Neelsen
 b. Myxospore in sutural view
 c. Myxospore stained in Giemsa

4. DISCUSSION

The present species is compared with myxospores of morphologically similar species i.e *M. impressus* (Miroshnichenko, 1980) infecting fin, gills of *Barbus barbus*; *M. indirae* (Kundu, 1985) infecting head cartilage, tail fin of *Cirrhinus mrigala*; *M. crucifilus* (synonyms *Gyrospora crucifilus* (Qadri, 1962) infecting gills of *L. fimbriatus*; *M. nodulointestinalis* (Masoumian et al., 1996) infecting intestine of *Barbus sharpeyi*; *M. eirasi* (Kaur and Singh, 2009) infecting caudal fin of *C. mrigala*; *M. punjabensis* (Gupta and Khera,

Dar et al.

Morphological and histopathological description of *Myxobolus nigeriae* n. sp. infecting gills of a cold water native cyprinid fish, *Schizothorax niger* from Wullar Lake (India), Species, 2016, 17(55), 109-118, www.discoveryjournals.com

© 2016 Discovery Publication. All Rights Reserved

1989) infecting gills and fins of *L. dyocheilus*; *M. vanivilasae* (Seenappa and Manohar, 1980) infecting below scale, muscles and integument of *C. mrigala*; *M. bliccae* (Donec and Tozyyakova, 1984) infecting efferent arteries of gill filaments of *Blicca bjoerkna* and *M. sushmii* (Kaur and Singh, 2010) infecting eye ball of *L. rohita*. (Table II).

The myxospores of *M. nigeriae* n. sp. are characterized in having ovoidal or subspherical shape having broad anterior end and rounded posterior end. In this respect, it is similar to *M. crucifilius*, *M. eirasi*, *M. impressus*, *M. indirae*, *M. nodulointestinalis*, *M. punjabensis*, *M. sushmi* and *M. bliccae*. But the presence of thick band in the sporoplasm of *M. crucifilius* and *M. eirasi* differentiate them from the myxospore of the present species in which sporoplasmic band is absent. Although sporoplasmic thread is also absent in *M. nodulointestinalis* and *M. impressus* however, a knob-like structure bearing a pore is present through which both the polar filaments are extruded together after crossing each other which differentiate them from the myxospore of the present study where the knob is absent. The presence of intercapsular process in *M. impressus*, *M. punjabensis*, *M. bliccae*, *M. vanivilasae*, *M. sushmii* and *M. nodulointestinalis* differentiate them from the present myxospores in which intercapsular process is absent. Furthermore, the presence of flat anterior end in the myxospores of *M. indirae* and *M. bliccae* differentiate them from the present myxospores in having broad anterior end. The elongated shape of myxospores in *M. nodulointestinalis* differentiate it from the present myxospores in having subspherical shape. In addition, the size of myxospores of *M. nigeriae* n. sp. are much smaller as compared to above mentioned species.

The differences discussed above indicate unique characteristics of the present species and is proposed as new to the science and named as *Myxobolus nigeriae* n. sp.

5. HISTOPATHOGENESIS

The plasmodium of *M. nigeriae* n. sp. is large located in the gill lamella of *S. niger*. The plasmodia are typed as intralamellar vascular type, LV₃ as per location in the secondary gill lamella. The plasmodia are round to oval and size ranging from 80-100 µm in diameter (Fig. 3). These plasmodia occupy whole of the gill lamella and due to enlarged diameter occupies interlamellar space thereby pushing the neighboring gill lamellae sideways, and also deforming them. This location is different from LV₁, LV₂ and LV₄ in which the plasmodia are located centrally, on the side and on the tip of the gill lamellae respectively. Furthermore, this type of plasmodia lead to deformation of whole of the infected gill lamellae in contrast to 1/4th in the LV₁, LV₂ and LV₄, therefore causing maximum loss of respiratory surface. Histological sections reveal hypertrophy of lamellar cells, inflammation, gill epithelial lifting and fusion of adjacent lamellae. Hyperplasia and vacuolization of the epithelial, vascular endothelial cells, goblet cells around the cysts are observed and due to the presence of myxospores within the lamellae, the blood vessels are dilated and bounding epithelial cells are highly stretched. The observations clearly indicated the destruction of the respiratory surface of *S. niger* infected with *M. nigeriae* n. sp. In view of above observation the parasite, *M. nigeriae* n. sp. is considered as highly pathogenic.

Similar observations were made by (Adriano et al., 2009) that the presence of plasmodia affect the gill functions and drastically reduces the respiratory surface. Myxoboliasis caused by myxozoans in the gills of *Catla catla* and gible carp were reported by (Sanaullah and Ahmed, 1980 and Dykova and Lom, 1978) which observed that infected carps with hemorrhagic condition and necrotic changes in the epithelia and in connective tissues of gills. Similarly it was observed in gill infections of American catfish with *Henneguya exilis* (MacCraren et al., 1975) in *Channa punctata* with *Henneguya waltirensis* (Kalavati and Narasimhamurti, 1985) and in carp with *Myxobolus koi* (Rukyani, 1990). Kaur and Katoch (2014) and (Kalavati and Narasimhamurti, 1985) observed that rupturing of cysts can also lead to hemorrhages, and sometimes may result in considerable loss of blood. In case of severe infection hypertrophy of the basal epithelial and goblet cells leading to increase in mucus production. The location of plasmodia in the intralamellar site was recorded to be associated with hypertrophy and inflammation. Cellular changes may lead to the fusion of adjoining secondary lamellae which was also reported by (Kaur et al., 2013b and Kaur and Katoch, 2014).

ACKNOWLEDGEMENTS

The authors acknowledge the funding by Department of Science and Technology, Government of India, New Delhi in the form of major research project (MRP- SERB No-SR/SO/AS/67/2011).

REFERENCES

- Adriano EA, Arana S, Alves AL, Silva MR, Ceccarelli PS, Henrique-Silva F, Maia AA. *Myxobolus cordeiroi* n. sp., a parasite of *Zungaro jahu* (Siluriformes: Pimelodiade) from Brazilian Pantanal: morphology, phylogeny and histopathology. *Vet Parasitol*, 2009, 162, 221-229
- Atkinson SD, Sojková P, Whipps CM. Approaches for characterizing Myxozoan species, in: B. Okamura, A. Gruhl, J.L. Bartholomew (Eds.) 2015. *Myxozoan Evolution, Ecology and Development*, Springer, Berlin.
- Dykova I, Lom J. Histopathological changes in fish gills infected with myxosporidian parasites of genus *Henneguya*. *J Fish Biol.*, 1978, 12: 197-202
- Eiras JC, Zhang J, Molnar K. Synopsis of the species of *Myxobolus* Butschli, 1882 (Myxozoa: Myxomyxosporae, Myxobolidae) described between 2005 and 2013. *Syst Parasitol*, 2014, 88, 11-36
- Gupta S, Khera S. Observations on *Myxobolus punjabensis* sp. nov. (Myxozoa: Myxobolidae), parasitic on gills and fins of

- Labeo dyocheilus*. *Riv. Parasitol*, 1989, 50, 131-138
6. Kalavati C, Narasimhamurti CC. Histopathological changes in the gills of *Channa punctatus* BL. infected with *Henneguya waltirensis*. *Arch Protistenkd*, 1985, 129, 199-202
 7. Kaur H, Attri R. Morphological and molecular characterization of *Henneguya bicaudi* n. sp. (Myxosporea: Myxobolidae) infecting gills of *Cirrhinus mrigala* (Ham.) in Harike Wetland, Punjab (India). *Parasitol Res*, 2015, 114, 4161-4167
 8. Kaur H, Katoch A. Gill disease caused by *Thelohanellus bifurcata* Basu and Halder, 1999 a pathogenic myxozoan parasite in cultured Indian carp, *Labeo rohita* (Hamilton, 1822) in Punjab, India. *J Anim Health Prod*, 2014, 2, 19-24
 9. Kaur H, Katoch A. Prevalence, site and tissue preference of myxozoan parasites infecting gills of cultured fish in Punjab (India). *Dis Aquat Org*, 2016, doi: 10.3354/dao02959
 10. Kaur H, Katoch A, Gupta M. *Thelohanellus filli* sp. n., a pathogenic myxosporean infecting gills of cultured carp, *Labeo rohita* (Hamilton 1822) in Punjab, India. *Species*, 2014a, 10, 31-38
 11. Kaur H, Katoch A, Shoaib A, Singh R. *Myxobolus nanokiensis* sp. nov. (Myxozoa: Bivalvulidae), a new pathogenic myxosporean parasite causing haemorrhagic gill disease in cultured Indian major carp fish, (Hamilton 1822) in Punjab, India. *J Parasit Dis*, 2013a, 39, 405-413
 12. Kaur H, Shoaib A, Katoch A. *Thelohanellus dykovi* sp. nov. (Myxozoa: Bivalvulidae). A pathogenic gill parasite in cultured Indian major carp, *Labeo rohita* (Hamilton 1822) in Punjab (India). *Species*, 2014b, 10, 24-30
 13. Kaur H, Shoaib A, Singh R. One new and three already known Myxosporean parasites of Indian major carps in Punjab (India). *Species*, 2013b, 4, 17-24
 14. Kaur H, Singh R. Observations on one new species of genus *Myxobolus* – *M. naini* and redescription of *M. magauddi* recorded from freshwater fishes of Kanjali Wetland of Punjab, India, 2008, pp. 75-79. In: Proc. 20th Natl. Congr. Parasitol., Department of Zoology North Eastern Hill University, Shillong (Meghalaya)
 15. Kaur H, Singh R. A new myxosporean species, *Myxobolus eirasi* sp. nov., a known species *M. venkateshi* Seenappa and Manohar (1981) from the Indian major carp fish *Cirrhina mrigala* (Ham). *Protistology*, 2009, 6, 126-130
 16. Kaur H, Singh R. A new myxosporean species *Myxobolus sclerii* sp. nov. and one known species *M. stomum* Ali et al. (2003) from two Indian major carp fishes. *J Parasit Dis*, 2010a, 34, 33-39
 17. Kaur H, Singh R. One new myxosporidian species, *Myxobolus splendrii* sp. nov., one known species, *M. punjabensis* Gupta, Khera (1989) infecting freshwater fishes in wetlands of Punjab, India. *Parasitol Res*, 2010b, 106, 1043-1047
 18. Kaur H, Singh R. Two new species of *Myxobolus* (Myxozoa: Myxosporea: Bivalvulida) from freshwater fishes of Punjab wetlands (India). *J Parasit Dis*, 2011a, 35, 33-41
 19. Kaur H, Singh R. Two new species of *Myxobolus* (Myxozoa: Myxosporea: Bivalvulida) infecting an Indian major carp in Ropar and Kanjali wetlands (Punjab). *J Parasit Dis*, 2011b, 35, 23-32
 20. Kaur H, Singh R. Two new species of *Myxobolus* (Myxozoa: Myxosporea: Bivalvulida) infecting an Indian major carp and a cat fish in wetlands of Punjab, India. *J Parasit Dis*, 2011c, 35, 169-176
 21. Kaur H, Singh R. Two new species of *Myxobolus* (Myxozoa: Myxosporea: Bivalvulida) infecting Indian freshwater fishes in Punjab wetlands (India). *Parasitol Res*, 2011d, 108, 1075-1082
 22. Kaur H, Singh R. *Myxobolus harikensis* sp. nov. (Myxozoa: Myxobolidae) infecting fins of *Cirrhinus mrigala* (Ham.), an Indian major carp in Harike wetland, Punjab (India). *Parasitol Res*, 2011e, 109, 1699-1705
 23. Kaur H, Singh R. Two new species of *Myxobolus* (Myxozoa: Myxosporea: Bivalvulida) infecting an Indian major carp and a cat fish in wetlands of Punjab, India. *J Parasit Dis*, 2011f, 35, 169-176
 24. Kaur H, Singh R. A synopsis of the species of *Myxobolus* Bütschli, 1882 (Myxozoa: Bivalvulida) parasitizing Indian fishes and a revised dichotomous key to myxosporean genera. *Syst Parasitol*, 2012a, 81, 17-37
 25. Kaur H, Singh R. One new myxosporean species, *Triangula cirrhini* sp. n., and one known species, *T. ludhiana* (syn. *M. ludhiana* Gupta and Khera, 1991) comb. n. (Myxozoa: Myxosporea), infecting Indian major carp in Harike wetland of Punjab. *Anim Bio*, 2012b, 62, 129-139
 26. Kundu T.K. *Myxosoma indira* sp. n. (Myxozoa: Myxosomatidae) from the head cartilage, scale and tail fin of *Cirrhina mrigala*. *Acta Protozool*, 1985, 24, 333-337
 27. Lom J, Arthur JR. A guideline for the preparation of species descriptions in Myxosporea. *J Fish Dis*, 1989, 12, 151-156
 28. Lom J, Dykova I. Protozoan parasites of fishes, 1994, pp: 159-235 In Elsevier Science Publishers B.V., Amsterdam, the Netherlands
 29. Lom J, Dykova I. Myxozoan genera: Definition and notes on taxonomy, life-cycle terminology and pathogenic species. *Folia Parasitol*, 2006, 53, 1-36
 30. MacCraren JP, Landolt MM, Hoffman GL. Variation in response of Channel catfish to *Henneguya* sp. infections (Protozoa: Myxosporidia). *J Wild Dis*, 1975, 11, 2-7
 31. Masoumian M, Baska F, Molnar K. *Myxobolus nodulointestinalis* sp. n. (Myxosporea, Myxobolidae), a parasite of the intestine of *Barbus sharpeyi*. *Dis Aquat Org*, 1996, 24, 35-39.
 32. Miroshnichenko AI. *Myxobolus impressus* n. sp., a new myxosporidian (Cnidosporidia, Myxosporidia) from freshwater fish in the Crimea. *Biologicheskie Nauki*, 1980, 9, 38-39.
 33. Molnar K. Site preference of fish myxosporeans in the gill. *Dis Aquat Organ*, 2002, 48, 197-207
 34. Qadri SS. On a new myxosporidian parasite, *Phlogospora mysti* gen. n., sp. n., from Indian freshwater fish *Mystus bleekeri*. *Arch Protistenkd*, 1962a, 106, 211-217
 35. Sanaullah M, Ahmed ATA. Gill myxoboliasis of major carps in Bangladesh. *J Fish Dis*, 1980, 3, 349-354
 36. Lom J, Dykova I. Myxosporidia (Phylum Myxozoa) In Protozoan parasites of fishes. Developments in aquaculture and fisheries. (eds. J. Lom and I. Dykova), El-

Dar et al.

Morphological and histopathological description of *Myxobolus niger* n. sp. infecting gills of a cold water native cyprinid fish, *Schizothorax niger* from Wullar Lake (India), *Species*, 2016, 17(55), 109-118, www.discoveryjournals.com

- sevier., Publ., Amsterdam, 1992, pp. 159-235
37. Seenappa D, Manohar L. *Myxobolus vanivilasae* n. sp. parasitic in *Cirrhina mrigala* (Ham.). *Proc Indian Acad. Sci*, 1980, 89, 485-491
 38. Singh R, Kaur H. Two new *Thelohanellus* Kudo, 1933 (Myxozoa: Myxosprea: Bivalvulida) infecting fins of major carps in wetlands of Punjab. *Trends Parasitol Res*, 2012a, 1, 34-43
 39. Singh R, Kaur H. Myxosporean species of the genus *Thelohanellus* Kudo, 1933 (Myxozoa: Myxosprea: Bivalvulida) from freshwater fishes of Punjab wetlands, India. *Protistology*, 2012b, 7, 208-217
 40. Singh R, Kaur H. Biodiversity of myxozoan parasites infecting freshwater fishes of three main wetlands of Punjab, India. *Protistology*, 2012c, 7, 79-89
 41. Singh R, Kaur H. Two new and two already known species of genus *Thelohanellus* Kudo, 1933 (Myxozoa: Myxosprea: Bivalvulida) infecting Indian major carp fishes in Punjab wetlands (India). *J Parasitol Dis*, 2014a, 38, 49-60
 42. Singh R, Kaur H. Two new and one already known species of the genus *Thelohanellus* (Myxozoa: Myxosprea: Bivalvulida) parasitizing fresh water fishes in wetlands of Punjab, India. *Biologia*, 2015, 70, 85-93

Species