

Prevalence and Tissue Specificity of *Myxobolus saugati* Kaur and Singh, 2011 (Myxozoa; Myxosporea; Bivalvulida) Causing Dermal myxoboliosis in Wild and Cultured Indian Major Carps in Punjab

Harpreet Kaur^{1*}, Rajni Attri²

1. Assistant Professor, Parasitology Laboratory, Department of Zoology and Environmental Sciences, Punjabi University, Patiala-147002

2. Research Scholar, Parasitology Laboratory, Department of Zoology and Environmental Sciences, Punjabi University, Patiala-147002, Mail:- rajniattri491@gmail.com

*Corresponding author: Kaur H; Mail: harpreetbimbura@gmail.com

Publication History

Received: 7 April 2015

Accepted: 10 May 2015

Published: 1 July 2015

Citation

Harpreet Kaur, Rajni Attri. Prevalence and Tissue Specificity of *Myxobolus saugati* Kaur and Singh, 2011 (Myxozoa; Myxosporea; Bivalvulida) Causing Dermal myxoboliosis in Wild and Cultured Indian Major Carps in Punjab. *Species*, 2015, 15(47), 14-18

ABSTRACT

During a survey from Jan. 2011 to Jan. 2013, a total of 360 specimens of Indian major carps, *Labeo rohita* (Ham.) vern. rohu and *Cirrhinus mrigala* (Ham.) vern. mrigala *Catla catla* (Ham.) vern. thail and *Hypophthalmichthys molitrix* (Val.) vern. silver carp, brigade were collected from Harike wetland and aquaculture ponds in Punjab, out of which scales of 155 fishes were found to be infected with a myxobolid parasite viz., *M. saugati* Kaur and Singh, 2011. Total infection rate was recorded to be 43%. Highest rate of infestation was found in summer season (72.2%) and maximum infection was recorded in *Labeo rohita* (64.6%) followed by *Catla catla* (56%), *Cirrhinus mrigala* (54.5%) and *Hypophthalmichthys molitrix* (20%). The parasitic prevalence in fish specimens collected from Harike wetlands was higher than from fish farms (44% vs 37.2%). Scale Pseudocyst Index indicated severe infestation (SPI- 4) in all the major carps.

Key words: Indian major carps, wetlands of Punjab, aquaculture, *Myxobolus*, scales.

1. INTRODUCTION

Several species of parasites are recognized as severe pathogens that cause significant ecological damages, as well as economic losses in the fishing and aquaculture industries. The Indian major carps are the most important fresh water species in India, thus presenting great commercial value in wetlands and also in aquaculture. Some of the myxozoans species infecting fish are known to cause serious growth delays thereby hindering the large-scale production. However, in Punjab (India), there is little information regarding the impact of infection of myxozoans in wild and aquaculture environments. The infestations could be more severe in semi-intensive and intensive culture systems where the environmental factors and human interference would allow the entry of pathogens. Lakes, rivers have become the end point of the pollutants discharge (Elnwshy *et al.*, 2007) leading to an increased threat of parasitic infections associated with environmental pollution (Hussain *et al.*, 2003).

Myxosporeans are common parasites of fish world-wide (Lom & Dykova, 1994), which cause serious damage to economically important freshwater and marine fish species. There are approximately 2500 species of myxosporeans in 52 genera and most of them parasitize freshwater fish (Kent *et al.*, 2001). New species are being described every year (Schlegel *et al.*, 1996), which parasitize a wide variety of fish tissues and produce pseudocysts that contain hundreds of thousands of small spores. Eiras *et al.*, 2005a, b published a synopsis of the *Myxobolus* species listing the characteristics of 744 nominal species. Since then (2005-2012) 112 new species were described within a wide geographical range, all of them infecting fish (Eiras *et al.*, 2014), is one of the most important pathogens of fresh water and marine fishes. Therefore, this study was aimed at estimation of prevalence of *M. saugati* (Kaur and Singh, 2011) causing serious form of dermal myxoboliosis in *Labeo rohita*.

2. MATERIALS AND METHODS

Fishes were collected from Harike wetland and fish farms in Patiala and Amritsar districts of Punjab. Fishes were brought to the laboratory and examined for the myxozoan infection. The scales were removed and placed in petridish with saline solution. Pseudocysts on infected scales appeared as opaque white patches. Scales were teased on a clean slide, cover slip was laid over and examined under the microscope. The myxospore were identified as *M. saugati* Kaur and Singh, 2011 on the basis of morphological and morphometrical characters as per the guidelines of Lom and Dykova, 1989.

2.1. Scanning electron microscopy (SEM) (Kelley *et al.*, 1973)

For scanning electron microscopy, scales containing plasmodium were washed several times in distilled water and fixed in 4% gluteraldehyde in phosphate buffer (pH 7.4) for 4-72 hrs at 4°C. After rinsing the specimens in buffer for 5-10 min, they were again incubated in 1% Osmium tetroxide for 30-60 min and washed in distilled water 5-10 times over a period of 15min. They were then dehydrated through an acetone series to amyl acetate. After complete dehydration, the specimens were dried in critical point drier and mounted on stubs, teased and coated with gold in sputter. The specimens were photographed in LEO 435 (VP) make electron microscope at AIIMS, New Delhi.

$$2.2. \text{Prevalence (\%)} = \frac{\text{Number of infected fish} \times 100}{\text{Total number of fish examined}}$$

2.3. Scale Pseudocyst Index (SCI)

The intensity of infection on scales was determined by the following "scale pseudocyst index" **0** = no infection; **1**= one pseudocyst per scale in 10% of total scales (indicating light infection); **2**= two pseudocysts per scale in 15-20% of total scales (moderate infection); **3**= three to five pseudocysts per scale in 50% of total scales (heavy infection); **4**= five to ten pseudocysts per scale in 100% of scales (severe infection) (Fig.1).

3. RESULTS

3.1. Pseudocyst

The pseudocysts were ovoid to round, measure 0.5 to 3.6 mm in diameter, opaque white patches sandwiched between the layers of the scale, 5-10 in number per scale. 500-1000 myxospores were present per pseudocyst (Fig. 1, 2).

3.1.1. Parasitological examination

The myxospores of *M. saugati* Kaur and Singh, 2011 were liberated from the pseudocysts after the scales were cut through. Spores were released in the form of milky white fluid. The mature myxospores were rounded, measure 6.84×4.98µm with two equal polar capsules. The number of pseudocysts per scale and number of scales infected per fish host were counted to calculate the Scale Pseudocyst Index (SPI). The SPI was recorded as 4 as five to ten pseudocysts per scale in 100% of scales on the body of the fish indicating severe infection. *M. saugati* Kaur and Singh, 2011 infecting scales has been recorded from the fish hosts of closely related taxa, *L. rohita*, *C. catla*, *C. mrigala* and *Hypophthalmichthys molitrix*, belonging to family Cyprinidae (commonly called as carp family), however, were highly organ and tissue specific in nature. This indicated that this parasite has predilection for hardened connective tissue in the scales which is otherwise is highly resistant to bacterial and fungal infections. Scanning electron microscopic studies have indicated that in infected scales the annuli and radii on the surface of the cycloid scales were not affected and myxopores were detected to be present in between the two layers of the scale rather on its

Harpreet Kaur and Rajni Attri,

Prevalence and Tissue Specificity of *Myxobolus saugati* Kaur and Singh, 2011 (Myxozoa: Myxosporea; Bivalvulida) Causing Dermal myxoboliosis in Wild and Cultured Indian Major Carps in Punjab, Species, 2015, 15(47), 14-18,

<http://www.discovery.org.in>

© 2015 Discovery Publication. All Rights Reserved

superficial surface therefore is regarded as histozoic (Fig.3, 4). It is presumed that this parasite make an entry through the root of the scale and spread to the rest of its parts just like in the case of dental cavity. The clinical symptomatology of the infected fish was white, cloudy appearance and mucoid body surface. Since frequency of severe infection (SPI-4) was 100% in all the four major carps, the fish was rendered unsightly and not fit for consumption. The present study indicated that this is the only myxobolid species which infect scales with so much of severity in this region of India and also has lot of economic importance affecting marketability of infected fish. Since this parasite has been recorded to cause great impact on the fish host not only physically but may also be affecting its survivability and development.

3.1.2. Prevalence of dermal myxoboliosis

43% of a total of 360 cyprinid examined were infested with *M. saugati* (Kaur and Singh, 2011), with seasonal prevalence 35, 50 and 16.6% in winter, spring and autumn, respectively. The highest rate of infestation (72.2%) was recorded in summer (Table I). *M. saugati* was more prevalent in major carps from natural water ecosystems than in fish from fish farms (Table II).

Table 1

Seasonal prevalence of *M. saugati* Kaur and Singh, 2011 in different varieties of Indian major carps in wild and aquaculture Indian major carps in Punjab during Jan. 2011 –Jan. 2013

Season	Number of fish Examined	Number of fish Infected	Total infestation (%)
Winter	90	30	33.3
Spring	90	45	50
Summer	90	65	72.2
Autumn	90	15	16.6

Table 2

Infestation of *M. saugati* Kaur and Singh, 2011 in different varieties of Indian major carps in wild and aquaculture fish in Punjab

Site	Number of fish examined	Number of fish infected	Total Infestation (%)
Wild	280	125	44
Aquaculture	80	30	37.5

Table 3

Infestation and Scale Pseudocyst Index (SPI) of *M. saugati* Kaur and Singh, 2011 in different varieties of Indian major carps

Name of Host Collected	Number examined	Number Infected	Prevalence	Scale Pseudocyst Index (SPI)	Frequency of severe infection
<i>Labeo rohita</i>	150	97	64.6%	4 (severe infection)	100%
<i>Catla catla</i>	125	70	56%	4 (severe infection)	100%
<i>Cirrhinus mrigala</i>	55	30	54.5%	4 (severe infection)	100%
<i>Hypophthalmichthys molitrix</i>	30	6	20%	4 (severe infection)	100%

4. DISCUSSION

Myxozoan infection is one of the most commonly occurring disease affecting various organs and tissues of fresh water fishes belonging to different taxa. In the present study, the Indian major carps in wild fishes (collected from Harike wetland) and aquaculture were heavily infested in the scales causing the disease, dermal myxoboliosis. These fishes were often dumped by fisherman as these were regarded as unmarketable, because of the large visible cysts on the scales. According to Betke *et al.* (2001) these fishes were ineligible for consumption according to food hygiene regulations. Myxosporeans parasitizing fishes generally reveal strong host and tissue specificity in well definable life cycle (Molnar, 1994). This tendency as well as the morphology of spore stage have also provided valuable information for the taxonomic classification of these parasites. The prevalence of *M. saugati* showed seasonal cycle of development, as parasite start forming small patches from winter reaching the maximum number in summer then started to decrease by the rupture of the cysts and released the spores in the environment to start infestation. Seasonal reproductive cycles have also been reported earlier for other species of *Henneguya* (Sabri *et al.*, 2010). The higher prevalence of *M. saugati* in major carps from Harike wetland was due to different kinds of pollutants threatening the natural water. Maximum infection in *Labeo rohita* (64.6%) followed by *Catla catla* (56%), *Cirrhinus mrigala* (54.5%) and *Hypophthalmichthys molitrix* (20%) have been recorded. Accumulation of toxic substances and water eutrophication with algae blooms contribute to the poor water quality that acts as stress factor in increasing fish susceptibility to parasites and stimulates an unbalanced state of the host/parasite/environment system (Coutant, 1998). The present study indicated that the total percentage of infection in fresh water fishes in wild and aquaculture was 43%, and this study indicated that the *M. saugati* is a tissue specific parasite. Kaur and Singh (2008-2009) had recorded 13.0% myxozoan infection in Harike wetland. Earlier, Gupta and Khera (1987) had reported 36.3% of infection rate in fresh water fishes of North India. In addition, Singh and Kaur (2012) had recorded 56.4% prevalence of infection in *M. saugati* in the Kanjali wetland, Punjab, India.

REFERENCES

1. Betke P, Engelhardt A, Habedank B, Schein E, Thiele S. Identification of *Henneguya zschokkei* (Gurley, 1894) (Myxosporea: Myxobolidae) in smoked salmon. *Archivfurleben Smittel Hygiene Hannove*, 2001, 52, 100–102
2. Coutant CC. What is normative for fish pathogens? A perspective on the controversy over interactions between wild and cultured fish. *J Aquat Anim Health*, 1998, 10, 101–106
3. Eiras JC, Malta JCO, Varela AMB, Pavanelli GC. *Myxobolus insignis* sp. n. (Myxozoa, Myxosporea, Myxobolidae), a parasite of the Amazonian teleost fish *Semaprochilodus insignis* (Osteichthyes: Prochilodontidae). *Mem Inst Oswaldo Cruz*, 2005a, 100, 245–247
4. Eiras JC, Molnar K, Lu YS. Synopsis of the species of *Myxobolus* Butschli, 1882 (Myxozoa: Myxosporea: Myxobolidae). *Syst Parasitol*, 2005b, 61, 1–46
5. Eiras JC, Zhang J, Molnar K. Synopsis of the species of *Myxobolus* Butschli, 1882 (Myxozoa: Myxosporea: Myxobolidae) described between 2005 and 2013. *Syst Parasitol*, 2015, 88, 11–36
6. Elnwishi N, Ahmed M, El-Shreif M, Abd Elhameed M. The effect of diazinon on glutathine and acetylcholinesterase in tilapia (*Oreochromis niloticus*). *J Agric Soc Sci*, 2007, 3, 52–54
7. Gupta S, Khera S. On the genera *Henneguya* Thelohan, 1892 and *Unicauda* Davis, 1944. *Res Bull (Sci.) Panj Univ.*, 1987, 38, 153–163
8. Hussain S, Hassan MZ, Mukhtar Y, Saddiqui BN. Impact of Environmental pollution on human behavior and up-lift of awareness level through mass media among the people of Faisalabad city. *Int J Agric Biol*, 2003, 5, 660–661
9. Lom J, Arthur JR. A guideline for the preparation of species descriptions in Myxosporea. *J Fish Dis*, 1989, 12, 151–156
10. Lom J, Dykova I. Studies on protozoan parasites of Australian fishes. 3 Species of the genus *Myxobolus* Butschli, 1882. *Eur J Protistol.*, 1994, 30, 431–439
11. Schlegel M, Lom J, Stechmann A, Bernhard D, Leipe L, Dykova I, Sogin ML. Phylogenetic analysis of complete small subunit ribosomal RNA coding region of *Myxidium lieberkuehni*: evidence that Myxozoa are Metazoa and related to the Bilateria. *Arch Protistenkd.*, 1996, 147, 1–9
12. Molnar K. Comments on the host, organs and tissue specificity of fish myxosporean and on the types of their intrapiscine development. *Parasit hung.*, 1994, 27, 5–20
13. Kaur H, Singh R. Incidence of Myxozoan Parasites in freshwater fishes of Wetlands of Punjab. *J Punj Acad Sci (JPAS)*, 2008/2009, 5-6 (1&2), 88–91
14. Kaur H, Singh R. Two new species of *Myxobolus* (Myxozoa: Myxosporea: Bivalvulida) infecting an Indian major carp and a cat fish in wetlands of Punjab, India. *J Parasitic Dis.*, 2011, 35 (2), 169–176
15. Kelley RO, Dekker RO, Bluemink JG Ligand mediated osmium binding: its application in coating biological specimens for SEM. *J Ultrastruct Res.*, 1973, 45, 254–258
16. Kent ML, Andree KB, Bartholomew JL, Matbouli M, Dessler SS, Devlin RH, Feist SW, Hedrick, RP, Hoffman RW, Khattri J, Hallett SL, Lester JG, Longshaw M, Palenzeula O, Siddall ME, Xiao C. Recent advances in our knowledge of the Myxozoa. *J Eukaryot Microbiol.*, 2001, 48, 395–413
17. Sabri Dm, Eissa I Am, Danasoury Ma, Khouraiha Hm. Prevalence of *Henneguya branchialis* in Catfish (*Clarias gariepinus*) in Ismailia, Egypt. *Int J Agric Biol.*, 2010, 12(6), 897–900
18. Singh R, Kaur H. Biodiversity of myxozoan parasites infecting freshwater fishes of three main wetlands of Punjab, India. *Protistology*, 2012, 7 (2), 79–89



Fig. 1

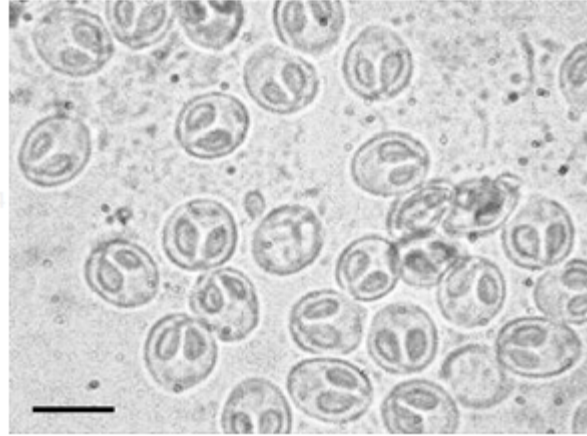


Fig. 2




Fig. 3




Fig. 4

Figure 1
Infested scales of *Labeo rohita*

Figure 2
Fresh spores of *M. saugati* (Kaur and Singh, 2011); Scale bar: 0.01mm

Figure 3
SEM of infested scale of *Labeo rohita* (Ham.)

Figure 4
SEM of pseudocyst ruptured showing several myxospores of *M. saugati* Kaur and Singh, 2011