

## The study of Acanthocytes, a red cell abnormality in the male and female false Vampire Bat *Megaderma lyra lyra* (Geoffroy)

Sastry MS<sup>1\*</sup>, Gaurkar RV<sup>2</sup>

1. Professor and Head , Department of Zoology, RTM Nagpur University, Nagpur-440033, India
2. Research Scholar, Department of Zoology, RTM Nagpur University, Nagpur-440033, India

\*Corresponding author: Professor and Head, Department of Zoology, RTM Nagpur University, Nagpur-440033, India, e-mail: sastry\_nidhi@rediffmail.com

### Publication History

Received: 4 December 2014

Accepted: 17 January 2015

Published: 11 March 2015

### Citation

Sastry MS, Gaurkar RV. The study of Acanthocytes, a red cell abnormality in the male and female false Vampire Bat *Megaderma lyra lyra* (Geoffroy). *Species*, 2015, 13(38), 15-19

### ABSTRACT

Since different types of abnormal red blood cells arise by different etiologic processes, disease diagnosis can often be made by interpretation of red blood cell pathology in conjunction with hematological data and other clinical and laboratory information. The presence of red blood cell abnormalities can give important diagnostic clues for the well being of any species. It is important therefore, that all features of the erythrocytes be assessed including number, color, size, polychromasia, the presence of precursors, alterations in shape, inclusions, the presence of RBC parasites and arrangement. Erythrocytes can occur in many different shapes. Most of them are pathological and can be involved in diseases such as hemolytic anemias and sickle cell anemia. Acanthocytes are such type of red cells with one or more bleb-like protruberances with few spine-like processes. Intermediate forms include crenated spheres and cells that appear normal in size but have several spiny excrescences. These cells have a peculiar crenated appearance due to the presence of pseudopods or protoplasmic projections varying in size and shape. The recorded data of Acanthocytes throughout the year was in the range of 2-26% from both the sexes of *Megaderma lyra lyra* pointing to mild Acanthocytosis.

**Keywords:** Haematology, Acanthocytes, Microchiropteran bat, *Megaderma lyra lyra*.

## 1. INTRODUCTION

The term "acanthocyte" refers specifically to the thorny-shaped red cells found in patients with a congenital absence of low density (beta) lipoprotein (Bassen and Kornzweig, 1950). Cells of similar morphology referred to as "spur cells", have been described in association with hemolysis in patients with severe liver disease (Smith et al., 1964; Cooper, 1969). Acanthocyte membranes have an increased amount of spingomyelin and a decreased amount of lecithin (Phillips, 1962; Ways et al., 1963), however, spur cells are actually somewhat enriched with lecithin (Cooper et al., 1972). Acanthocytosis represents an unusually pathological variant of red cell morphology which is encountered in diverse group of inherited and acquired disease status. While the morphological features are similar in all instances, the biochemical lesions frequently differ. Acanthocytosis occur in association with at least three neurological syndromes associated with a variety of inherited and acquired disorders (Biemer, 1980; Walensky et al., 2003). Acanthocytosis (Ways and Simon, 1962) is a hereditary syndrome characterized clinically by retarded growth, steatorrhea, progressive neurological disease and retinal degeneration (Bassen and Kornzweig, 1950). In the blood, half or more of the red cells are acanthocytes ("thorny" cells) and low density (beta) lipoproteins are greatly decreased or completely absent (Phillips, 1962; Ways et al., 1963; Cooper et al., 1972). Acanthocytosis and disordered lipoprotein metabolism are inextricably linked in medical history (Simon and Ways, 1964; Al-Shali and Hegele, 2005) hence it was felt to describe the presence of acanthocytes in the annual collection of blood samples of *Megaderma lyra lyra*.

## 2. MATERIALS AND METHODS

### Collection of specimens

The specimens of *Megaderma lyra lyra* were collected with the help of a mist net placed at the entrance of the underground mines at Mansar / Kandri near Nagpur, Maharashtra (20°92'N 78°95'E) once every calendar month throughout the complete annual cycle from April 2011-March 2012.

### Blood sampling

The bats were held in hands and no anesthesia was used at the time of sample collection. 2 ml of blood was collected into sterile Eppendorf tubes with no anticoagulants (neither EDTA nor heparin) after puncturing a wing vein. After blood sampling each bat was released.

### Preparation of a blood film

Blood from males and females were used without any anticoagulant directly from the syringe or needle immediately after collection by applying the "wedge smear" or the "slide and coverglass" technique. A routine preparation of at least three smears per blood samplings were performed. The air-dried smears were kept in a dust free environment until they were stained.

### Giemsa staining of blood smeared slide

The occurrence of acanthocytes in red blood cells were studied throughout the annual cycle, from April 2011 to March 2012 by staining blood smears with Giemsa for 24 hours (Giemsa, 1904).

### Statistical Analysis

The data was analyzed statistically, standard errors were calculated on the basis of which graphs were plotted to compare the seasonal variation (Delgaard, 2008).

## 3. OBSERVATIONS

Acanthocytes were seen during the months May (26%), August (12%), November (25%) and February (2%) from females, however, the remaining months revealed the presence of acanthocytes in a declining percentage (Table-1, fig.-1, Panel A and B) and during August (10%), November (9%), December (10%) from males (Table-1, fig.-1, Panel C and D).

## 4. DISCUSSION AND CONCLUSION

The annual study of blood smear of the false vampire bat *Megaderma lyra lyra* revealed that the occurrence of acanthocytes from both the sexes were in the range of 2-26%. On comparison with the literature in human it was found that average red cells were of normal size and normochromic but 60-70% of the cells were distorted (Phillips, 1962; Ways et al., 1963; Smith et al., 1964; Cooper et al., 1972). A variety of reasons have been demonstrated in the literature for the acanthocytosis. Thus this may due to changes in the organization of cell membrane components, or defect in the lipid or protein composition of RBC since mammalian red cells lack the ability to synthesize lipids de novo, the state of their fluidity depends to a large extent on the control of lipoprotein lipid composition (Bretscher, 1972). While this serves adaptive and homeostatic roles under normal conditions, abnormalities in the lipid composition and thereby in the fluidity and function of red cell membranes depends to a large extent on the control of lipoprotein lipid composition (Cooper, 1977).

Similarly the acanthocytes are normal with respect to the pathways of red cell intermediary carbohydrate metabolism considered of major importance to red cell integrity (Ways and Simon, 1962). The degree of cell deformity increases with cell maturation or aging or both. Glycolysis, phosphogluconate oxidation and pentose phosphate metabolism in acanthocytes are characteristic of a population slightly enriched with young cells. The capacity of acanthocytes to utilize these pathways for reduced glutathione and adenosine triphosphate maintenance and

Sastry and Gaurkar,

The study of Acanthocytes, a red cell abnormality in the male and female false Vampire Bat *Megaderma lyra lyra* (Geoffroy),

Species, 2015, 13(38), 15-19,

<http://www.discovery.org.in/s.htm>

[www.discovery.org.in](http://www.discovery.org.in)

© 2015 Discovery Publication. All Rights Reserved

for methemoglobin reduction is normal (Ways and Simon, 1962). The cholesterol /lecithin mole ratios are greater in spur cells (Cooper et al., 1972). The term “acanthocytosis” was itself coined a half-century ago to describe the dysmorphic erythrocytes seen in abetalipoproteinemia (ABL), a complex metabolic disorder that is characterised by fat malabsorption, atypical retinitis pigmentosa and spinocerebellar ataxia (Al-Shali and Hegele, 2005).

Even though the exact mechanism of acanthocytosis remains uncertain, passive changes in membrane lipids with very low levels of total lipid, phospholipid and cholesterol, accompanied by an altered distribution of lecithins and sphingomyelins may result in acanthocytosis (Phillips, 1962; Ways et al., 1963; Cooper et al., 1972). Surface receptor, ligand interactions and a primary membrane defect are the possible factors for acanthocytosis (Smith et al., 1964; Cooper, 1980; Hardie, 1989; Wong, 2004). From the foregoing discussion the present situation of acanthocytosis in both the sexes of males and females might have arisen from the various causes mentioned for humans. The present results are also comparable with some of the bats studied till now (Grundboeck and Krzanowski, 1957; Sealander, 1964; Valdivieso and Tamsitt, 1971; Korine et al., 1999; Sastry and Bhatkulkar, 2006). In the present study acanthocyte abnormality was comparatively less in the male than in female *Megaderma*. Such occurrence may be correlated to a decreased survival of erythrocytes in the circulation owing to splenic sequestration and destruction which appears to be harmful to the general health of the bat.

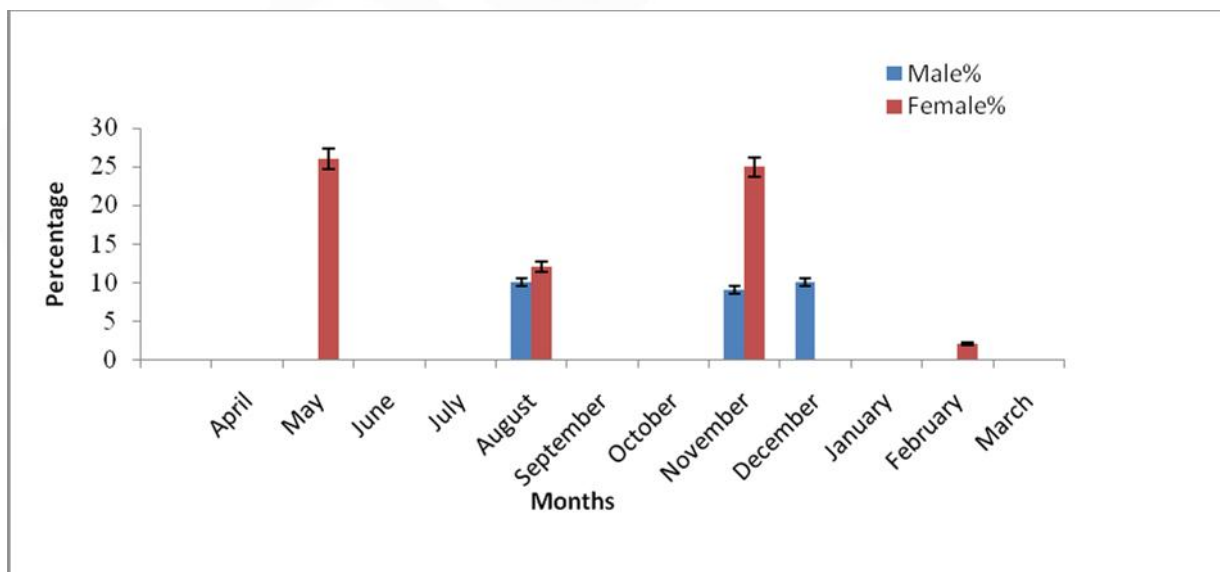
## REFERENCES

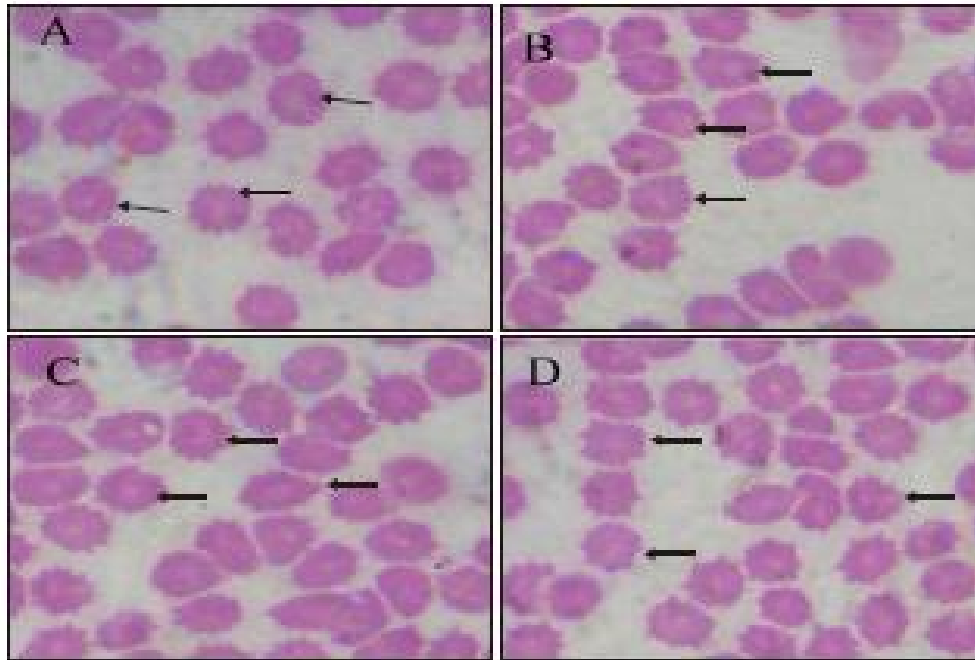
1. Al-Shali K, Hegele RA. Acanthocytes and Disorders of Lipoprotein Metabolism. In: Danek A, ed. *Neuroacanthocytosis Syndromes*, 2005, pp 21-30
2. Bassen FA, Kornzweig AL. Malformation of the erythrocytes in a case of atypical retinitis pigmentosa. *Blood* 1950, 5, 381-386
3. Biemer JJ. Acanthocytosis- biochemical and physiological considerations. *Ann Clin Lab Sci* 1980, 10, 3, 238-249
4. Bretscher MS. Asymmetrical lipid bilayer structure for biological membranes. *Nat New Biol*, 1972, 236, 11-12
5. Cooper RA. Anemia with spur cells : A red cell defect acquired in serum and modified in the circulation. *J Clin Invest*, 1969, 48, 1820- 1831
6. Cooper RA, Diloy Puray M, Lando P, Greenverg MS. An analysis of lipoproteins, bile acids, and red cell membranes associated with target cells and spur cells in patients with liver disease. *J Clin Invest*, 1972, 51, 12, 3182-3192
7. Cooper RA. Abnormalities of cell-membrane fluidity in the pathogenesis of disease. *N Engl J Med*, 1977, 297,371-377
8. Delgaard P. Introductory statistics with R, 2<sup>nd</sup> edition. *Springer Verlag*, 2008
9. Giemsa G. Eine Vereinfachung und Vervollkommnung meiner Methylenblau-Eosin-Färbemethode zur Erzielung der Romanowsky-Nocht'schen Chromatinfärbung. *Centralblatt für Bakteriologie I Abteilung* . 1904, 32, 307–313
10. Grundboeck M, Krzanowaski A. Morphological investigations on the blood of some European species of bats. *Zool Poloniae*, 1957, 8, 349 – 368
11. Korine C, Zinder O, Arad Z. Diurnal and seasonal changes in blood composition of the free living Egyptian fruit bat (*Rousettus aegyptiacus*). *J Comp Physiol B*, 1999, 169, 280 – 286
12. Phillips GB. Quantitative chromatographic analysis of plasma and red blood cell lipids in patients with acanthocytosis. *J Lab Clin Med*, 1962, 59 : 357
13. Sastry MS, Bhatkulkar M. Variations in the haematocrit values during the male and female reproductive cycle of a Megachiropteran bat *Rousettus leschenaulti* (Desmerest). *J Env Develp*, 2006 Chap.26, pp 255-265
14. Sealander JA. The influence of body size, season, sex, age and other factors upon some blood parameters in small mammals. *J Mammal*, 1964, 45 : 598 – 616
15. Simon ER, Ways P. Incubation hemolysis and red cell metabolism in acanthocytosis. *J Clin Invest*, 1964, 43,7, 1311-1321
16. Smith JA, Lonergan ET, Sterling K. Spurr- cell anemia. Hemolytic anemia with red cells resembling acanthocytes in alcoholic cirrhosis. *N Engl J Med*, 1964, 271 , 396
17. Valdivieso D, Tamsitt JR. Hematological data from tropical American bat. *Can J Zool*, 1971, 49 : 31 – 36
18. Walensky L, Narla M , Lux SE. Disorders of the red blood cell membrane. In: *Blood, Principles and Practice of Hematology*, 2<sup>nd</sup> edn. (ed. by RI Handin, SE Lux & TP Stossel) 2003, 1726–1744
19. Ways P, Simon ER. The pathogenesis of abnormal red cell function in acanthocytosis (abstract). *Blood* 1962, 20, 788-799
20. Ways P, Reed CF, Hanahan DJ. Red-cell and plasma lipids in acanthocytosis. *J clin Invest*, 1963, 42,8, 1248-1261

**Table 1**

The results of hematologic investigations are presented in Table-1. Pertinant data regarding collection of *Megaderma lyra lyra* used for the present study is also been incorporated. The number in paranthesis is for animals used

Specimen (n = 3)	Date of collection	Time of collection	Body weight(g)	Occurrence of Acanthocytes (%)
Female	22/4/2011	3.00 p.m.	39	Non occurrence
Male			30	Non occurrence
Female	19/5/2011	2.30 p.m.	36	Occurrence (26%)
Male			32	Non occurrence
Female	25/06/2011	10.30 a.m.	34	Non occurrence
Male			31	Non occurrence
Female	30/07/2011	11.00 a.m.	34	Non occurrence
Male			32	Non occurrence
Female	16/08/2011	10.30 a.m.	34.5	Occurrence (12%)
Male			31	Occurrence (10%)
Female	02/09/2011	3.30 p.m.	33	Non occurrence
Male			32	Non occurrence
Female	04/10/2011	11.25 a.m.	33	Non occurrence
Male			32	Non occurrence
Female	05/11/2011	11.30 a.m.	34	Occurrence (25%)
Male			31.5	Occurrence (9%)
Female	08/12/2011	11.00 a.m.	33.5	Non occurrence
Male			31.5	Occurrence (10%)
Female	07/01/2012	11.30 a.m.	34	Non occurrence
Male			30	Non occurrence
Female	02/02/2012	2.00 p.m.	34	Occurrence (2%)
Male			32.5	Non occurrence
Female	03/03/2012	11.00 a.m.	36	Non occurrence
Male			32	Non occurrence





**Figure 1**

Acanthocytes (arrow) from the blood smears in panels A and B from females collected on 16/8/11 and 5/11/11 respectively. Acanthocytes (arrow) from the blood smears in panels C and D from males collected on 5/11/11 and 8/12/11 respectively. RBCs with blunt spiny (thorny) projections. The projections varies in width, length and surface distribution. There are 10-12 spicules per cell, which shows irregular spacing and thickness X 400.