

**To Cite:**

Tayade V, Vardhan V. Goal-oriented rehabilitation in a 15-year-old case of cystic bronchiectasis secondary to Pierre-robin sequence- Case report. Medical Science 2022; 26:ms328e2267.

doi: <https://doi.org/10.54905/disssi/v26i126/ms328e2267>

**Authors' Affiliation:**

<sup>1</sup>Resident, Department of Cardio-Respiratory Physiotherapy, Ravi Nair Physiotherapy College, Datta Meghe Institute of Medical Sciences Wardha, Maharashtra, India; Email:

vishakha.vishakhatayade.tayade@gmail.com, ORCID:

<https://orcid.org/0000-0003-4995-7543>

<sup>2</sup>Professor & HOD, Department of Cardio-Respiratory Physiotherapy, Ravi Nair Physiotherapy College, Sawangi (Meghe), Wardha, Maharashtra, India; Email: vishnudiwakarpt@gmail.com, ORCID:

<https://orcid.org/0000-0002-3780-2854>

**\*Corresponding Author**

Professor & HOD, Department of Cardio-Respiratory Physiotherapy, Ravi Nair Physiotherapy College, Sawangi (Meghe), Wardha, Maharashtra, India; Email: vishnudiwakarpt@gmail.com

**Peer-Review History**

Received: 27 April 2022

Reviewed & Revised: 29/April/2022 to 29/July/2022

Accepted: 02 August 2022

Published: 06 August 2022

**Peer-review Method**

External peer-review was done through double-blind method.

URL: <https://www.discoveryjournals.org/medicalscience>



This work is licensed under a Creative Commons Attribution 4.0 International License.

# Goal-oriented rehabilitation in a 15-year-old case of cystic bronchiectasis secondary to Pierre-robin sequence- Case report

Vishakha Tayade<sup>1</sup>, Vishnu Vardhan<sup>2\*</sup>

**ABSTRACT**

**Background:** Bronchiectasis is marked by persistent respiratory infections, a productive cough, shortness of breath, and a decreased ability to exercise. In Pierre robin Mandibular distraction is a current effective therapeutic approach for elongating the jaw and resolving obstruction of the respiratory system. The goal of the treatment is to relieve the dyspnoea and increase the chest expansion. Treatment options may involve modified postural drainage positioning, breathing exercises, acapella device, aerobic exercises, and mandibular distraction with physiotherapeutic management. **Case presentation:** A 15 years old girl visited the hospital with complaints of dyspnoea (MMRC grade IV), productive cough, weight loss for one month, and a history of pulmonary arterial hypertension 2 years back. **Investigations:** investigations include HRCT scan of the thorax which revealed patchy areas of centrilobular consolidation and 2D echo shows severe pulmonary arterial hypertension. **Treatment:** Physiotherapy management included patient education, breathing exercises, airway clearance techniques, acapella device, positioning and mandibular distraction. Outcome measures have shown improvement in aerobic capacity and performance of activities of daily living.

**Keywords:** Cystic bronchiectasis, Pierre-robin sequence, retrognathia, mandibular distraction, physiotherapy rehabilitation

**1. INTRODUCTION**

The Pierre Robin syndrome is characterized by micrognathia, glossoptosis and upper respiratory obstruction, with or without cleft palate (Martínez Plaza et al., 2015). One rationale for the rarity of RS birth prevalence statistics is that no diagnostic criteria for the illness have been agreed upon (Bush and Williams, 1983). The jaw is smaller in people with the PRS, and the tongue is retracted, making the pharynx even smaller, causing upper airway obstruction (Chigurupati and Myall, 2005; Sidman et al., 2001). The treatment for the PRS can range from conservative to surgical. The majority of these children will

benefit from being positioned in a prone decubitus position until their mandible has grown sufficiently to advance the tongue and open the airway

Bronchiectasis is a chronic lung disease marked by recurrent respiratory infections, a productive cough, shortness of breath, and a reduced ability to exercise (O'Neill et al., 2019). Although a past acute lung infection is the most prevalent cause of bronchiectasis, there are many other causes, and bronchiectasis may continue to be a common illness even in high-income countries. In 2013, the female and male incidence was 35.2 and 26.9 per 100 000 person-years respectively. The chest x-ray in presumed bronchiectasis is usually normal (Pasteur et al., 2010). Bronchiectasis is typically diagnosed via a high-resolution CT scan, which may be used to evaluate recurrent infections or to determine the source of chronic cough (Morice, 2004). The physical examination may reveal information about the diagnosis. In mild to advanced bronchiectasis, clubbing is prevalent. Auscultatory findings include wheezes, rhonchi, crackles, and pleural rub.

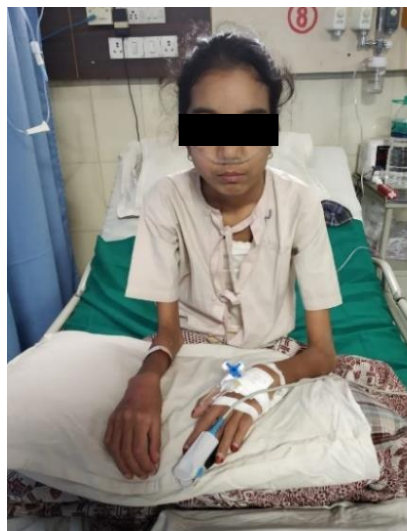The goal of bronchiectasis treatment is to minimize the symptoms. Bronchodilators inhaled and postural drainage may be beneficial. Devices, such as the acapella device, intrapulmonic percussive ventilation device, and incentive spirometry, are available to help mobilize and remove airway mucus. International recommendations encourage the use of physiotherapy in the treatment of bronchiectasis and should be instructed an airway clearance technique (ACT) by a certified cardiorespiratory physiotherapist (Chang et al., 2015).

## 2. PATIENT INFORMATION

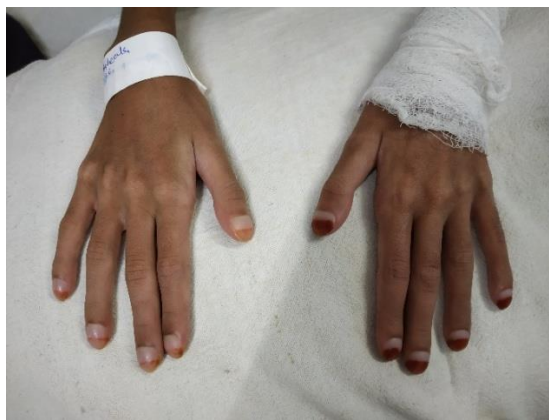A 15 years old girl was diagnosed with an acute chest infection at the age of 3 months and was treated with medications and an inhaler. 2 years back she again started symptoms of breathlessness and cough with sputum production and was taken to a tertiary care hospital and was diagnosed with pulmonary arterial hypertension for which medications were given. CECT was done which revealed loss of volume of the left lower lobe with cystic bronchiectasis, showing air-fluid levels along with mild cylindrical bronchiectasis changes in left lingula segments, right middle and lower lobe. But before 1 month her symptoms were aggravated. For 1 month she was experiencing dyspnea usually severe grade 4 present at rest on MMRC associated with desaturation and hypotension on several occasions and weight loss. The patient was then referred to our hospital and was diagnosed with cystic bronchiectasis. The patient was then admitted to pediatric ICU and was put on 4L of O<sub>2</sub>/min via nasal mask and was maintaining oxygen saturation of 95%. Her Paternal grandmother is a known case of asthma.

## 3. CLINICAL FINDINGS

On observation, her body built was ectomorphic (fig 1), eyes and sclera were protruded and teeth were retrognathia. The patient's nails were yellowish in colour and clubbing was present (fig 2). On examination, she was alert and oriented to time, person, and self, febrile at 98°F. Heart rate-76 beats/min, BP-116/80 mm/Hg, tachypnoeic at 26 breaths/min, and O<sub>2</sub> saturation at 95% maintained by nasal mask. On inspection, the chest movement is reduced on both sides with an increase in the work of respiration due to greater activation of accessory muscles. On palpation, chest excursion confirmed the decreased chest expansion on both sides. Chest auscultation revealed bilateral symmetric expansion, air entry was reduced in upper zones and crackles were present.



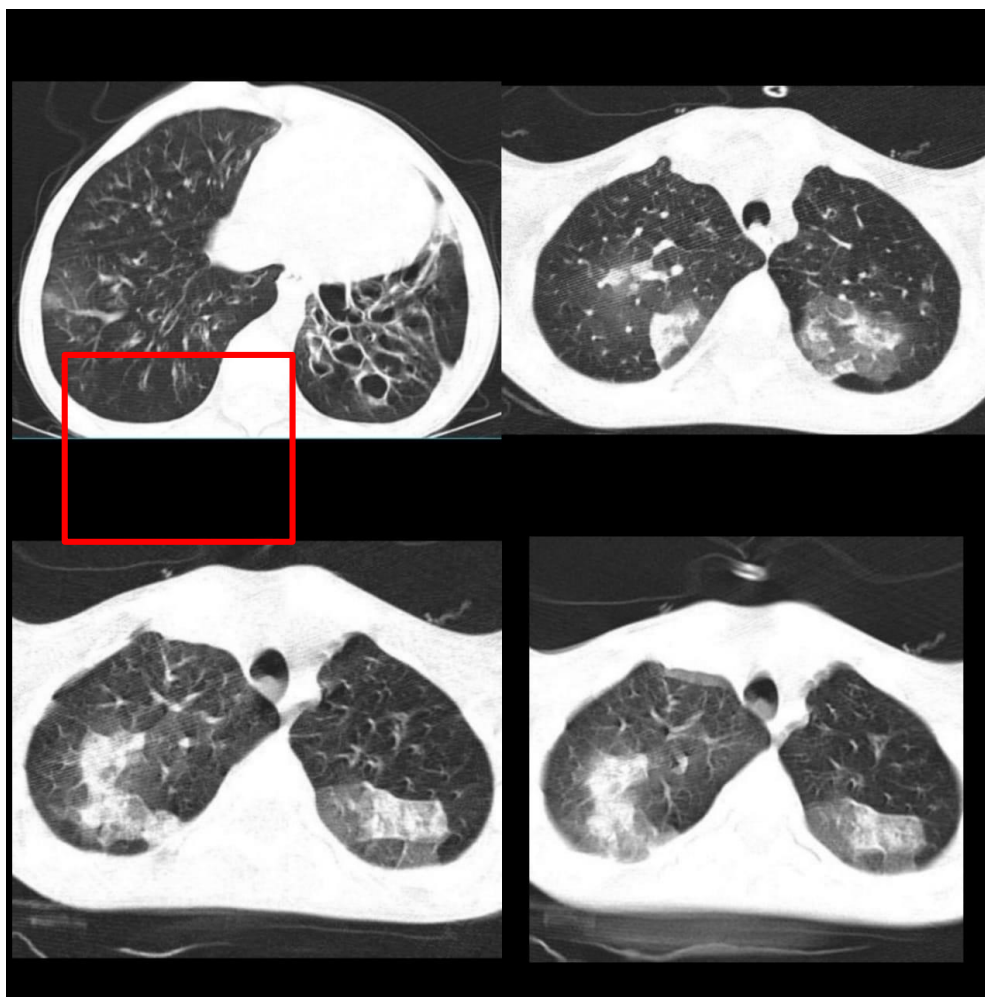
**Figure 1** Lean body mass (difficulty in gaining weight)



**Figure 2** Showing grade II clubbing of nails (obliteration of Lovibond angle)

### Investigation

CECT shows loss of volume of the left lower lobe with cystic bronchiectasis, showing air-fluid levels along with mild cylindrical bronchiectasis changes in left lingula segments, right middle and lower lobe. HRCT scan of thorax shows patchy areas of centrilobular consolidation with the surrounding of the right lung and left upper lobe having ground-glass opacity. Bronchiectasis in bilateral lower lobes, more on left (fig 3). The 2D echo shows severe pulmonary arterial hypertension.



**Figure 3** showing HRCT scan of cystic bronchiectasis- Dilated bronchi are close together that resemble a cluster of grapes.

## Therapeutic intervention

### Pharmaceutical management

Tab lasilactone ½ tab BD (1mg/kg/day), Tab bosentan 62 mg 1/3-tab BD (2mg/kg/day), vitamin D sachets 60000IU OD, nebulizer with duolin.

### Physiotherapy management

Physiotherapy intervention was undertaken with the targets of enhancing the patient's airways and promoting the patient's ventilation, minimizing the work of respiration, and enhancing relaxation. It enables her to carry out routine activities without experiencing dyspnoea.

### Patient's education

The patient and her family were briefed about her disease, recovery, the necessity of physiotherapy treatment, and all necessary measures. The patient was taught active limb movement as well as deep breathing techniques. The patient was also advised to follow the prescribed routine and report for follow-up consultations. Further physiotherapeutic intervention with their dosage and rationale is given in table 1.

**Table 1** showing physiotherapeutic treatment with their dosage and rationale

Treatment given	Dosage	Rationale
A comfortable position for relaxing the upper chest and mobilizing the lower chest.	For 10-15 minutes	Forward bending stimulates diaphragmatic breathing by dropping viscera forward and thus diaphragm descends more easily
Controlled diaphragmatic breathing	Every 2 hourly, 10 repetitions	It provides peripheral distribution of nebulized particles
Modified postural drainage to areas where secretions are identified	10-15 minutes in MPD position for both the side	It assists in the removal of secretions
Percussion and vibration over affected lobes	3 times a day	It dislodges viscous and adherent mucus from the airways and helps to move secretions to larger airways
Segmental breathing and lateral coastal expansion	3 times per day, 5 repetitions- 2 sets	It facilitates diaphragmatic excursion
Active Cycles of Breathing Technique (ACBT)	3 times a day	to improve the functions of the lungs by mobilizing and clearing excess pulmonary secretions
Huffing and coughing	3 times a day	It allows the air to move past the mucus in the airways
Emphasize movement of the lower rib cage during deep breathing	3 times per day, 5 repetitions- 2 sets	To increase chest expansion
Incentive spirometry	3-4 times a day, 5 reps- 2 sets with 5-sec hold	To prevent lung collapse
Acapella device	3-4 times a day	To remove mucus from the airways
Aerobic exercises such as walking, cycling or swimming	2 times a day	It enhances the aerobic capacity of the inspiratory muscles and decreases the occurrence of inspiratory muscle fatigue
Mandibular Distraction	2 times a day, 5 repetitions- 2 sets	To treat upper airways

### Follow-up and Outcomes

In the hospital inpatient setting, the physiotherapy framework was initiated for two weeks with four sessions per week. After 2 weeks, the patient and her relatives were given a well-explained home exercise program before being discharged and was scheduled for a follow-up session. Pre and post-pulmonary rehabilitation outcome measures are given in table 2.

**Table 2** Pre and post pulmonary rehabilitation outcome measure

Outcomes	1 <sup>st</sup> day of assessment	At the time of discharge	Follow up
Grade of dyspnoea	IV	II	I
Rate of perceived exertion after activity	7	4	2
Sputum volume	25ml	occasional	No complaints
Six-minute walk test	200m	320m	440m

## 4. DISCUSSION

A chronic productive cough is common in patients with bronchiectasis and might last all year or only appear after an illness. Because secretions build in dependent areas, the cough is greater when the patient is lying down. Sputum is frequently purulent and ranges in volume from 20 to 500 mL each day. Some strains of bronchiectasis, such as those caused by *Mycobacterium tuberculosis*, affect only the upper lobes. Sputum production is usually normal in these patients because secretions do not accumulate, resulting in dry bronchiectasis. An underdeveloped jaw, backward tongue displacement, and upper airway blockage describe the Pierre robin sequence. Health care practitioners must acknowledge the architecture and airway mechanism of blockage in order to establish a specific intervention to restore breathing and achieve maximum growth for each patient with RS. Nafeez Syed et al., (2009) done a study on airway clearing in bronchiectasis, the ACBT was compared to traditional chest physiotherapy and concluded that On airway clearance in bronchiectasis, ACBT versus standard chest physical treatment. A study done by Miloro, (2010) in the Pierre-robin syndrome, mandibular distraction osteogenesis is used for paediatric airway management and came up with a result that for a young patient with an obstruction in the upper airway due to mandibular insufficiency, mandibular distraction osteogenesis is a potential alternative to a tracheostomy or other surgical procedure.

One of the study done by Paneroni et al., (2011) was on Short-term Intrapulmonary Percussive Ventilation in Bronchiectasis Patients: Safety and Efficacy and concluded that IPV was equally safe and effective as conventional chest physiotherapy in individuals with bronchiectasis and productive cough, with little discomfort. Another study done by Martínez Plaza et al., (2015) was on After mandibular distraction, variations in airway diameters in patients with PR syndrome abnormality syndromes and found that because of their beneficial effects on the airways, the horizontal distraction vector and the vector of oblique distraction would be the procedures of choice.

Another study was done by Phillips et al., (2021) on the utilisation of airway clearing procedures by physiotherapists during an acute exacerbation of bronchiectasis and found that individuals having an acute exacerbation of bronchiectasis are frequently treated with airway clearing procedures as part of their physiotherapy treatment, and the technique employed and perceived success differs depending on the patient's age.

## 5. CONCLUSION

Pulmonary rehabilitation and mandibular distraction have been shown to decrease dyspnoea. An integrated and comprehensive cystic bronchiectasis rehabilitation protocol is documented in this case report. Despite the fact that the patient's lung vital capacity did not improve completely following rehabilitation, the improvements were significant.

### Informed Consent

Written & Oral informed consent was obtained from all individual participants included in the study. Additional informed consent was obtained from all individual participants for whom identifying information is included in this manuscript.

### Acknowledgement

We thank the participants who were all contributed samples to the study.

## Author Contributions

Details of contribution of each authors regards manuscript work & production.

## Funding

This study has not received any external funding.

## Conflicts of interest

The authors declare that there are no conflicts of interests.

## Data and materials availability

All data associated with this study are present in the paper.

## REFERENCES AND NOTES

1. Bush PG, Williams AJ. Incidence of the Robin Anomalad (Pierre Robin syndrome). Br J Plast Surg 1983; 36:434–437. doi: 10.1016/0007-1226(83)90123-6
2. Chang AB, Bell SC, Torzillo PJ, King PT, Maguire GP, Byrnes CA, Holland AE, O'Mara P, Grimwood K. Chronic suppurative lung disease and bronchiectasis in children and adults in Australia and New Zealand Thoracic Society of Australia and New Zealand guidelines. Med J Aust 2015; 202: 21–23. doi: 10.5694/mja14.00287
3. Chigurupati R, Myall R. Airway Management in Babies with Micrognathia: The Case against Early Distraction. J Oral Maxillofac Surg 2005; 63:1209–1215. doi: 10.1016/j.joms.2005.04.011
4. Martínez PA, Fernández VR, España LA, García MB, Capitán LM, Monsalve IF. Changes in airway dimensions after mandibular distraction in patients with Pierre-Robin sequence associated with malformation syndromes. Rev Esp Cir Oral Maxilofac Engl 2015; 37:71–79. doi: 10.1016/j.maxile.2013.10.001
5. Miloro M. Mandibular Distraction Osteogenesis for Pediatric Airway Management. J Oral Maxillofac Surg 2010; 68:1512–1523. doi: 10.1016/j.joms.2009.09.099
6. Morice AH. The diagnosis and management of chronic cough. Eur Respir J 2004; 24:481–492. doi: 10.1183/09031936.04.00027804
7. O'Neill K, O'Donnell AE, Bradley JM. Airway clearance, mucoactive therapies and pulmonary rehabilitation in bronchiectasis. Respirol 2019; 24:227–237. doi: 10.1111/res.p.13459
8. Paneroni M, Clini E, Simonelli C, Bianchi L, Antoni FD, Vitacca M. Safety and Efficacy of Short-Term Intrapulmonary Percussive Ventilation in Patients With Bronchiectasis. Respir Care 2011; 56:984–988. doi: 10.4187/respcare.01098
9. Pasteur MC, Bilton D, Hill AT, British Thoracic Society Bronchiectasis (non-CF) Guideline Group. British Thoracic Society guideline for non-CF bronchiectasis. Thorax 2010; 65:i1–i58. doi: 10.1136/thx.2010.136119
10. Phillips J, Lee A, Pope R, Hing W. Physiotherapists' use of airway clearance techniques during an acute exacerbation of bronchiectasis: a survey study. Arch Physiother 2021; 11:3. doi: 10.1186/s40945-020-00097-5
11. Sidman JD, Sampson D, Templeton B. Distraction Osteogenesis of the Mandible for Airway Obstruction in Children. Laryngoscope 2001; 111:1137–1146. doi: 10.1097/0005537-200107000-00004
12. Syed N, Maiya AG, Siva KT. Active Cycles of Breathing Technique (ACBT) versus conventional chest physical therapy on airway clearance in bronchiectasis – A crossover trial. Adv Physiother 2009; 11:193–198. doi: 10.3109/14038190802294856