

To Cite:

Nagaraj NJ, Pallavi S, Ravisankar MS, Kumar TS. Endodontic management of an open apex with apexification using Mineral trioxide aggregate: A case report. *Medical Science* 2022; 26:ms315e2331. doi: <https://doi.org/10.54905/disssi/v26i125/ms315e2331>

Authors' Affiliation:

¹Assistant Professor, Department of Conservative Dentistry and Endodontics, Rajas Dental College and Hospital, Kavalkinaru Tirunelveli, Tamilnadu, India; Email: dr.njendo1992@gmail.com; ORCID ID: <https://orcid.org/0000-0002-0166-2327>

²Assistant Professor, Department of Conservative Dentistry and Endodontics, Rajas Dental College and Hospital, Kavalkinaru Tirunelveli, Tamilnadu, India; Email: itspalluhere@gmail.com; ORCID ID: <https://orcid.org/0000-0002-6901-3323>

³Associate Professor, Department of Conservative Dentistry and Endodontics, Rajas Dental College and Hospital, Kavalkinaru Tirunelveli, Tamilnadu, India; Email: msrendo@gmail.com; ORCID ID: <https://orcid.org/0000-0002-4175-1279>

⁴Assistant Professor, Department of Periodontology, Rajas Dental College and Hospital, Kavalkinaru, Tirunelveli, Tamilnadu, India; Email: tamilbdstirupur@gmail.com; ORCID ID: <https://orcid.org/0000-0003-4960-5118>

***Corresponding author**

Assistant Professor, Department of Conservative Dentistry and Endodontics, Rajas Dental College and Hospital, Kavalkinaru Tirunelveli, Tamilnadu, India; Email: dr.njendo1992@gmail.com

Peer-Review History

Received: 03 June 2022

Reviewed & Revised: 05/June/2022 to 20/July/2022

Accepted: 21 July 2022

Published: 27 July 2022

Peer-review Method

External peer-review was done through double-blind method.

URL: <https://www.discoveryjournals.org/medicalscience>



This work is licensed under a Creative Commons Attribution 4.0 International License.

Endodontic management of an open apex with apexification using Mineral trioxide aggregate: A case report

Nagaraj NJ^{1*}, Pallavi S², Ravisankar MS³, Tamil Selvan Kumar⁴

ABSTRACT

Endodontic treatment of a tooth with an immature apex poses a lot of challenges. The absence of an apical stop makes obturation and achieving a good apical seal more difficult. Because of their thin walls, these teeth are also more prone to fracture. Apexification with Mineral Trioxide Aggregate (MTA) is the preferred treatment because it creates a calcific barrier at the apex, allowing root canal filling to take place in a more favorable environment. This case report discusses the use of MTA to create a barrier at the apex in a previously root filled discolored maxillary right central incisor with an open apex. MTA aided in the creation of an apical barrier in the maxillary right central incisor with an open apex, resulting in satisfactory clinical and radiographic outcomes.

Keywords: Apexification, Calcium Hydroxide, Mineral Trioxide Aggregate, Open apex

1. INTRODUCTION

Traumatic injuries are more prevalent in the anterior teeth, particularly the maxillary central incisors. Dental traumatic injuries affect 13.8-15.1% of the population. When the problem is drastic, it can cause pulp inflammation, which can lead to pulpal necrosis (Nagarajappa et al., 2020). Hemolyzed red blood cell products may enter the dentinal tubules after pulpal necrosis, causing discoloration of tooth (Waterhouse & Nunn, 1996). Trauma during early - life disrupts root formation and causes inadequate dentinal wall growth at the root apices, resulting in blunderbuss canals (Gawthaman et al., 2013). To restore the function and appearance of the intrinsically discoloured tooth with an immature apex, extensive endodontic, restorative, and aesthetic treatment modalities are required. A single anterior discoloured tooth, in particular, might be an aesthetic difficulty since direct and indirect restorative techniques seldom provide satisfactory results (Srinivasan, 2015).

Maintaining a suitable apical barrier with a three-dimensional seal is challenging in the case of a blunderbuss canal. In addition, the absence of an

apical stop and extrusion of materials might result in a leaky canal. Blunderbuss open apex teeth with weak dentinal walls are also prone to fracture during and after treatment (Ingle et al., 2013). As a result, selecting material to treat these sorts of situations must be done with great care. The material used to treat these situations should have a set of criteria, including being bioactive, being able to produce a fluid-tight seal, reinforcing the root dentin, and being antimicrobial (Shikha et al., 2012). In 1993, Mahmoud Torabinejad developed Mineral trioxide aggregate (MTA) as a filling material in dentistry. Apexification with MTA offers numerous benefits, including the fact that it is not resorbed, does not damage the root dentin, and sets in a moist environment. Because of its alkaline pH and the release of calcium and phosphorus ions, MTA helps to create cementum and bone-like tissue (Komabayashi & Spångberg, 2008). This case report shows how MTA was employed to repair a non-vital open apex tooth that was inherently discoloured due to trauma.

2. CASE REPORT

A 23-year-old male patient approached with the major complaint of discolouration in the right upper front tooth with intermittent pain that had been bothering him for the last 3 years. The patient experienced a trauma that occurred 3 years ago. Past dental history revealed previously endodontic therapy was performed in relation to maxillary right central incisor (11) (Federation Dentaire International Tooth Numbering System) before 3 yrs. Clinical examination revealed discolored maxillary right central incisor (11) and Ellis Class II fracture in maxillary left central incisor (21) (Figure 1). An intraoral periapical radiograph revealed an incompletely developed apex with a radiopaque filling material present in the root canal with thin dentinal walls in the apical area in reference to the maxillary right central incisor (Figure 2). Pulp sensibility tests including electric pulp testing and cold test elicits non-vitality of tooth 11 and normal response in case of 21. The case was diagnosed as a discolored endodontically treated tooth with blunderbuss canal in 11. Considering the width of the apical foramen, the treatment strategy involved the removal of old root canal filling material and the induction of a calcified apical barrier using MTA (apexification). After notifying the patient, he gave his informed consent.

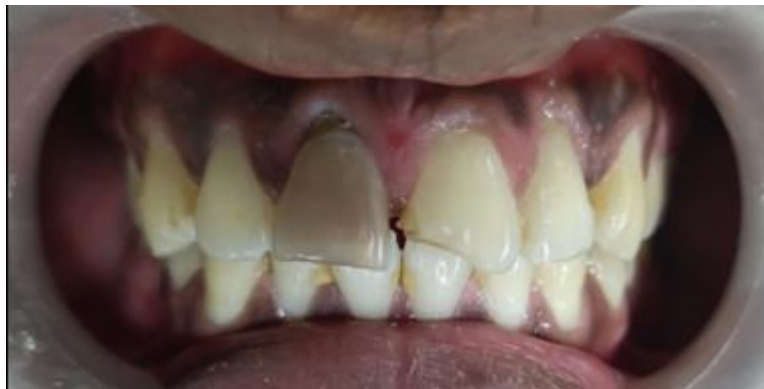

Figure 1 Discoloured tooth in relation to 11

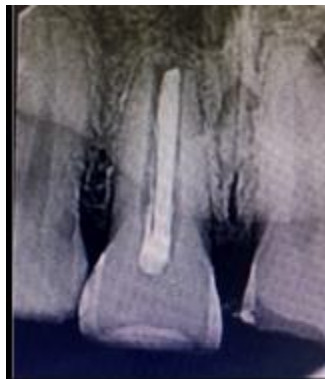

Figure 1 Preoperative radiograph showing previously root filled teeth with open apex in 11

The previous interim restoration was taken out, and the access cavity of 11 was modified with an endo access bur under the rubber dam isolation. The gutta percha was removed with the help of Protaper retreatment files (Dentsply Maillefer, Ballaigues, Switzerland) and a 60 size H-file (Mani INC; Japan) with the aid of solvent. A radiograph was taken to ensure the complete removal

of the old gutta percha from the canal (Figure 3). To avoid injuring the periapical tissue, the working length was set 2mm below the apex (Figure 4). A K-file of size no.60 (Mani INC; Japan) was used to instrument the root canal, and 3% sodium hypochlorite (NaOCL) (Prevest Denpro Limited, India) was used for irrigation. The final irrigation was done with a 2% chlorhexidine (CHX) (Asep RC, Anabond Stedman Pharma Research (P) LTD, India) irrigant. The canal was then dried with paper points after irrigation.

The root canal system was disinfected with calcium hydroxide (CH) (Ultradent Ultracal Xs, South Jordan, UT), and the tooth was coronally insulated with an interim restoration. Patient was recalled after 2 weeks. During the second appointment, Patient was found to be asymptomatic. CH was removed mechanically and washed out of the root canals using copious irrigation. MTA (White MTA, Angelus) was blended with distilled water provided by the manufacturer and inserted into the canal using an amalgam carrier. Preselected pluggers were employed to condense MTA into the root canal, resulting in a 5 mm plug. After examining the apical blockage of the MTA with a radiograph (Figure 5), moist cotton was inserted into the root canal to hydrate the material. The patient was called back the next day, and the setting of MTA was checked. Obturation was done with 2% gutta percha (META-BIOMED Co, Ltd, Cheongju-si, South Korea) and AH plus sealer (Dentsply Maillefer, Ballaigues, Switzerland) using lateral compaction method (Figure 6a, 6b).

The tooth was restored with a light cured composite material (Tetric N-Ceram, Ivoclar Vivadent AG, Schaan, Liechtenstein). For discolouration, non-vital bleaching was not performed due to the severe intrinsic discolouration. Hence, full coverage restoration was advised for the patient. Following the subsequent visit, tooth preparation was performed and metal ceramic crown was luted using Type I Glass ionomer cement (Figure 7).

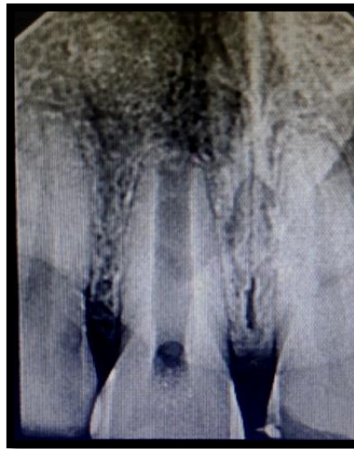

Figure 2 Radiograph showing the complete removal of guttapercha from the root canal in 11

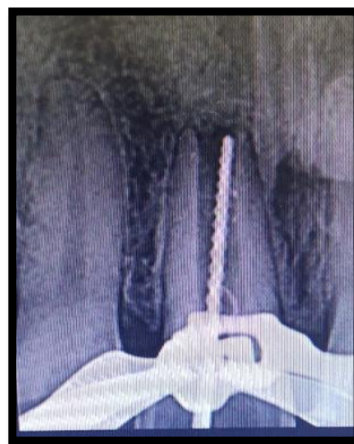

Figure 3 Working length determination

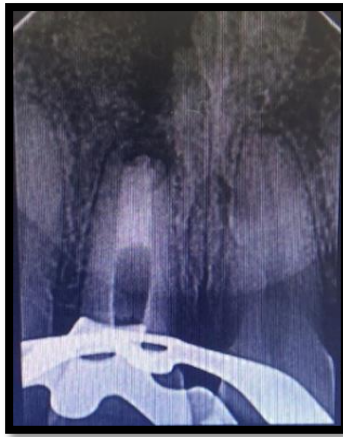

Figure 4 MTA apical plug

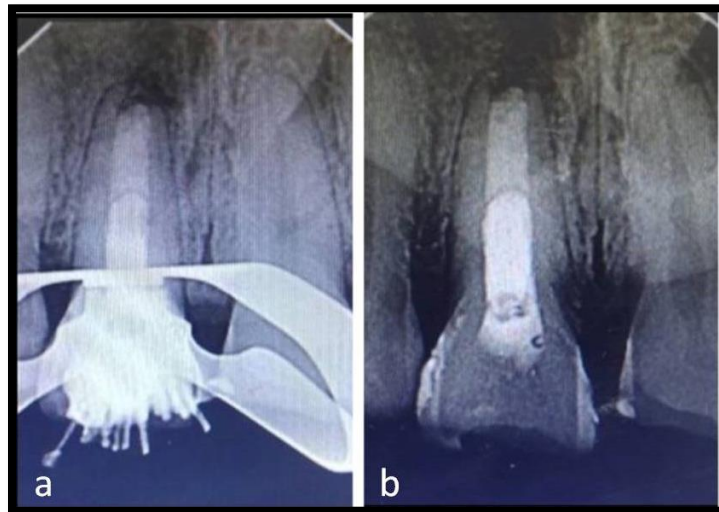


Figure 5 a) Obturation done with Lateral condensation technique. b) Post obturation radiograph

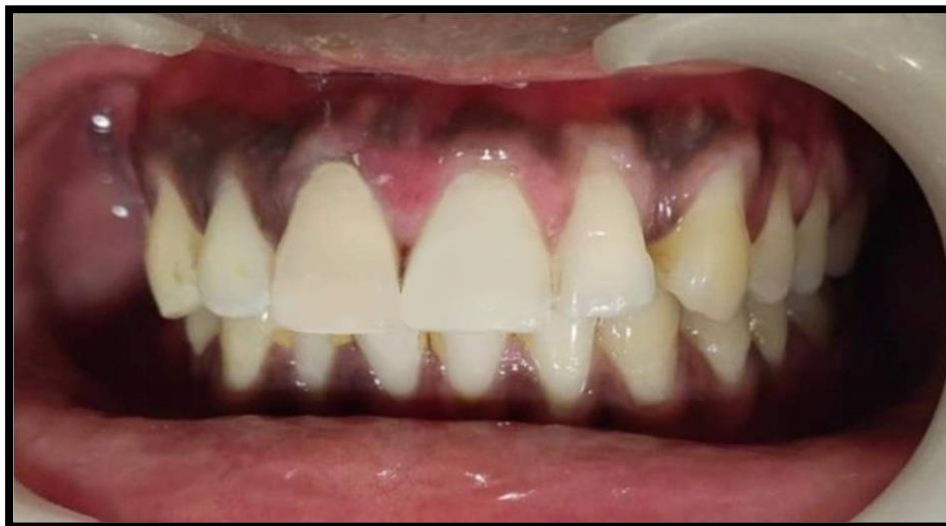

Figure 6 Metal ceramic crown in 11 to mask the discolouration

3. DISCUSSION

Endodontic success is contingent on achieving a complete seal in the apical region. Because of necrotic pulp tissue, broad open apices, diverging root walls, and weak dentinal walls, endodontic treatment of non-vital young anterior teeth following trauma is difficult. The main goal of root end material is to encase the apical region of the canal and provide a tight seal between the periodontium and the root canal system (Bodrumlu, 2008). MTA forms a bond between the cement and the tooth when used as an apexification material. An appetite-like barrier forms during MTA maturation, filling the space created during the contraction phase and reinforcing the fracture strength of the root canals (Torabinejad & Chivian, 1999). MTA stimulates osteoblastic or cementoblastic activity, which is aided by calcium and phosphorus ions (Kubasad & Ghivari, 2011; Chaudhari et al., 2022). The thickness of the MTA barrier, as well as the material used, both had an influence on its clinical efficacy. A 5 mm thick apical MTA barrier has been demonstrated to be substantially stronger and leakage-free (Adel et al., 2012). Aminoshariae et al., (2003) compared hand and ultrasonic condensation for MTA placement and concluded that hand condensation led to improved adaptability and fewer voids than ultrasonic condensation. As a result, manual condensation was utilized in this case to condense MTA at the apex.

The root canal system may not be thoroughly disinfected with mechanical debridement alone. Microorganisms that survive root canal instrumentation can multiply and colonize the root canal between visits (Kim & Kim, 2014). In order to eradicate bacteria between visits, irrigating solutions with antimicrobial properties such as NaOCl and CHX was utilized, and an intracanal medicament with potential antibacterial activity such as calcium hydroxide was employed for two weeks. At high pH, CH dissociates into calcium and hydroxyl ions, inhibiting enzymatic processes required for microbial survival, metabolism, proliferation, and cellular division (Kim & Kim, 2014).

4. CONCLUSION

MTA assisted in the apical barrier formation of the discoloured maxillary right central incisor with an immature apex, in this case, resulting in favorable clinical and radiographic results. Materials such as MTA are a new boon in the appropriate management of teeth with an immature apex.

Author's contribution

Nagaraj NJ: Conception, case analysis, manuscript drafting, approval of the final version

Pallavi S: Case analysis, manuscript drafting, approval of the final version

Ravisankar MS: Case analysis, manuscript drafting, and approval of the final version

Tamil Selvan Kumar: Supervision, critical revision of manuscript, approval of the final version

Informed consent

Written and Oral Consent was obtained from the patient participated in this study.

Acknowledgements

The authors would like to thank the patient and his bystanders for their cooperation.

Funding

This study has not received any external funding.

Conflicts of interest

The authors declare that there are no conflicts of interests.

Data and materials availability

All data associated with this study are present in the paper.

REFERENCES AND NOTES

1. Adel M, Nima MM, Shivaie Kojoori S, Norooz Oliaie H, Naghavi N, Asgary S. Comparison of endodontic biomaterials as apical barriers in simulated open apices. *ISRN Dent* 2012; 2012:359873. doi: 10.5402/2012/359873.
2. Aminoshariae A., Hartwell G.R., Moon P.C. Placement of mineral trioxide aggregate using two different techniques. *J Endod* 2003; 29:10:679-682. doi: 10.1097/00004770-200310000-00017.

3. Bodrumlu E. Biocompatibility of retrograde root filling materials: A review. *Aust Endod J* 2008; 34:30-5. doi: 10.1111/j.1747-4477.2007.00085.x
4. Chaudhari P, Chandak M, Chandak M, Sarangi S, Jaiswal A, Patel A. Integrative management of open apex with regenerative endodontic therapy: A case report. *Medical Science* 2022; 26:ms151e2124. doi: 10.54905/disssi/v26i122/ms151e2124
5. Gawthaman M, Vinodh S, Mathian VM, Vijayaraghavan R, Karunakaran R. Apexification with calcium hydroxide and mineral trioxide aggregate: Report of two cases. *J Pharm Bioallied Sci* 2013; 5(Suppl 2):S131-4. doi: 10.4103/0975-7406.114305.
6. Ingle JI, Bakland LK, Baumgartner JC. *Ingle's endodontics*. 6th ed. India: CBS; 2013.
7. Kim D, Kim E. Antimicrobial effect of calcium hydroxide as an intracanal medicament in root canal treatment: a literature review - Part I. In vitro studies. *Restor Dent Endod* 2014; 39(4):241-52. doi: 10.5395/rde.2014.39.4.241.
8. Komabayashi T, Spångberg LS. Comparative analysis of the particle size and shape of commercially available mineral trioxide aggregates and Portland cement: A study with a flow particle image analyzer. *J Endod* 2008; 34:94-8. doi: 10.1016/j.joen.2007.10.013
9. Kubasad GC, Ghivari SB. Apexification with apical plug of MTA- Report of cases. *Arch Oral Sci Res* 2011; 1:104-7.
10. Nagarajappa R, Ramesh G, Uthappa R, Kannan SPK, Shaikh S. Risk factors and patterns of traumatic dental injuries among Indian adolescents. *J Dent Sci* 2020; 15(1):96-103. doi: 10.1016/j.jds.2019.07.003.
11. Shikha D, Mukunda KS, Aruna A, Rao SM. Apexification. *J Dent Sci Res* 2012; 3(1):41-44.
12. Srinivasan R, Bandyopadhyay TK, Bhagabati N, Jaya R. Aesthetic management of a discoloured non-vital immature maxillary central incisor. *Med J Armed Forces India* 2015; 71(Suppl 2):S462-5. doi: 10.1016/j.mjafi.2014.07.010.
13. Torabinejad M, Chivian N. Clinical applications of mineral trioxide aggregate. *J Endod* 1999; 25:197-205. doi: 10.1016/S0099-2399(99)80142-3.
14. Waterhouse PJ, Nunn JH. Intracoronary bleaching of non-vital teeth in children and adolescents: interim results. *Quintessence Int* 1996; 27:447e453. PMID: 8941820