

**To Cite:**

Sonone SV, Bhakaney PR, Jain M, Yadav V, Vardhan VD. Inpatient pulmonary rehabilitation followed by Tele-Rehabilitation in a patient with Post Tubercular sequelae: A case study. Medical Science, 2022, 26, ms268e2188.

doi: <https://doi.org/10.54905/disssi/v26i125/ms268e2188>

**Authors' Affiliation:**

<sup>1</sup>Intern, Ravi Nair Physiotherapy College, DattaMeghe Institute of Medical Sciences, Wardha, Maharashtra, India; Email: samikshasonone12@gmail.com

<sup>2</sup>Resident, Department of Cardiorespiratory Physiotherapy, Ravi Nair Physiotherapy College, DattaMeghe Institute of Medical Sciences (DU), SawangiMeghe, Wardha, Maharashtra, India; Email: pallavi.bhakaney@dmimsu.edu.in

<sup>3</sup>Resident, Department of Cardiorespiratory Physiotherapy, Ravi Nair Physiotherapy College, DattaMeghe Institute of Medical Sciences (DU), SawangiMeghe, Wardha, Maharashtra, India; Email: molijain05@gmail.com

<sup>4</sup>Assistant Professor, Department of Cardiorespiratory Physiotherapy, Ravi Nair Physiotherapy College, DattaMeghe Institute of Medical Sciences, SawangiMeghe, Wardha, Maharashtra, India; Email: vaishnavi1326@gmail.com

<sup>5</sup>HOD & Professor, Department of Cardiorespiratory Physiotherapy, Ravi Nair Physiotherapy College, DattaMeghe Institute of Medical Sciences (DU), SawangiMeghe, Wardha, Maharashtra, India; Email: vishnudiwakarp@gmail.com

**Corresponding Author**

Assistant Professor, Department of Cardiorespiratory Physiotherapy, Ravi Nair Physiotherapy College, DattaMeghe Institute of Medical Sciences, SawangiMeghe, Wardha, Maharashtra, India; Email: vaishnavi1326@gmail.com

**Peer-Review History**

Received: 25 March 2022

Reviewed & Revised: 27/March/2022 to 27/June/2022

Accepted: 02 July 2022

Published: 04 July 2022

**Peer-review Method**

External peer-review was done through double-blind method.

URL: <https://www.discoveryjournals.org/medicalscience>



This work is licensed under a Creative Commons Attribution 4.0 International License.



**DISCOVERY**  
**SCIENTIFIC SOCIETY**

Copyright © 2022 Discovery Scientific Society.

## Inpatient pulmonary rehabilitation followed by Tele-Rehabilitation in a patient with Post Tubercular sequelae: A case study

Samiksha V Sonone<sup>1</sup>, Pallavi R Bhakaney<sup>2</sup>, Moli Jain<sup>3</sup>,  
Vaishnavi Yadav<sup>4\*</sup>, Vishnu Diwakar Vardhan<sup>5</sup>

**ABSTRACT**

A 52-year-old known case of pleural effusion caused by tuberculosis presented with complaints of breathlessness, right-sided chest pain, and weakness. History revealed that this was her second episode as a post tuberculosis sequel. She was treated with a multidisciplinary approach i.e. pharmacological as well as physiotherapeutic management. Necessary radiological imaging included chest x-ray and HRCT thorax which gave a better understanding of the lung condition of the patient. Pharmacological treatment included oxygen therapy and Inj. Augmentin, Inj. Aminophylline, Inj. Hydrocort, Tab. Mucinac 600mg and Tab. Montair; whereas physiotherapeutic management included airway clearance techniques, chest expansion techniques, early graded mobilization, strengthening, and stretching through telerehabilitation. The progression of the patient was recorded on outcome measures taken such as Dyspnea (MMRC score), 6-minute walk test, and HADS (Hospital Anxiety and Depression Scale).

**Keywords:** Post-Tuberculosis (PTB), Pleural Effusion, Tubercular Pleural Effusion, Telerehabilitation, physiotherapy rehabilitation

**1. INTRODUCTION**

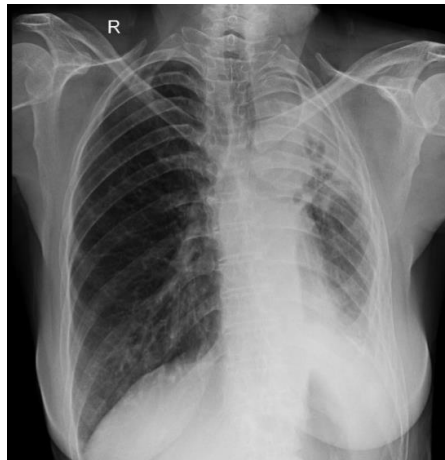Tuberculosis (TB) is one of the highest-ranked factors of mortality worldwide (Khan et al., 2020). Even after being cured of pulmonary tuberculosis (TB), patients might acquire new respiratory infections and lung disease, which can become chronic, increasing morbidity (Hsu et al., 2020). *Mycobacterium Tuberculosis* is a pathogenic bacterial species belonging to the Mycobacteriaceae family that is responsible for the majority of tuberculosis (TB) infections (Vorster et al., 2015). Because of the diversity of manifestations or complications, tuberculosis (TB) diagnosis and therapy remain difficult and complex. Acute and sub-acute TB problems are caused by Mycobacterium tuberculosis-induced structural damage or vascular impairment, as well as

metabolic irregularities and host inflammatory responses. Tuberculosis (TB) is still among the most prominent causes of pleural effusions on a global basis (Shah and Reed, 2014).

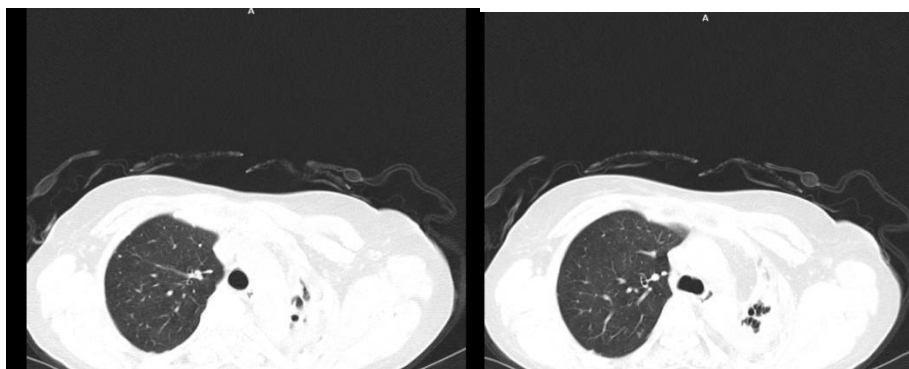
The lung is the most prevalent site of involvement, and radiological abnormalities might persist even after therapy, affecting the quality of life (Khan et al., 2020). Pulmonary tuberculosis is a degenerative disease that causes cicatrization, parenchymal changes, bronchiectasis, and scarring of the lungs, as well as a loss in lung capacity and a negative influence on pulmonary function (Hsu et al., 2020). The underlying cause of pleural effusion, whether it impairs breathing, and whether it can be effectively treated define the severity of the condition. This case study shows positivity on outcome measures in a post tuberculosis sequel patient as a result of supervised and monitored pulmonary rehabilitation followed by tele-rehabilitation.

## 2. CASE REPORT

A case is presented of a 52-year-old nurse whose past medical history included tubercular pleural effusion, for which she was on anti-tuberculosis drugs for 6 months (5 years ago). She underwent the procedure of thoracocentesis twice in the course of her hospitalization. After completion of her dosage, she experienced 2 episodes of restlessness followed by dyspnea at an interval of 2 years, for which she was admitted to the hospital. On presentation, in the pulmonology department, she was treated symptomatically and investigations were done (Fig 1 & 2) which revealed the presence of massive pleural effusion for which pleural tapping was done. Medications were administered and rest was encouraged. On the day of admission of the patient to the hospital, during her working hours, she experienced right-sided chest pain and breathlessness (grade 3 on Modified Medical Research Scale). The last night of the episode, she had a fever with chills followed by night sweats. She informed that she took paracetamol in the night and felt relieved. Immediately after experiencing breathlessness, she was admitted to the casualty and symptomatic treatment was started in which oxygen therapy and Inj. Augmentin, Inj. Aminophylline, Inj. Hydrocort, Tab. Mucinac 600mg and Tab. Montair was given. All the suggested investigations were done and the patient was referred to physiotherapy treatment. As the patient had symptoms like dyspnea, reduced effort tolerance, and generalized weakness, pulmonary rehabilitation was proposed.



**Figure 1** X-ray of chest which is showing homogenous opacity all over the left lung field with prominent bronchi-vesicular margins on the right side.



**Figure 2** High-resolution computed tomography (HRCT) thorax showing volume loss with fibrobronchiectatic changes in the left lung- sequel to old infection

### 3. CLINICAL FINDINGS

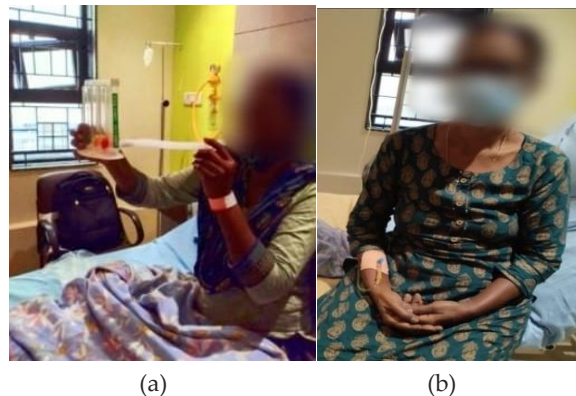
General examination of the patient revealed, cachexia, slouched posture with ectomorph built. The vital signs showed that the patient was hemodynamically stable, with oxygen support of 4L via nasal prongs. Systemic examination revealed increased AP diameter and reduced transverse diameter of the chest wall, along with which the expansion was measured revealing reduced chest expansion at all the three levels anteriorly; Supramammary, Mammary, and Inframammary. On percussion, the dull note was heard on the left lung surface and the hyper resonant note was heard on the right lung surface. Timelines are shown in table 1.

**Table 1** showing the course of hospitalization

Tubercular pleural effusion was detected on this date.	05/05/2016
Date of 1 <sup>st</sup> episode of breathlessness	25/6/2019
Date of 2 <sup>nd</sup> episode of breathlessness	21/9/2021
Date of admission at the hospital	22/9/2021
Date of physiotherapy rehabilitation reference	27/9/2021
Discharge date	29/10/2021
Last follow-up date	24/11/2021

#### Therapeutic intervention

Physiotherapy treatment reference was given because of reduced effort tolerance, weakness, and improving the functional capacity of the patient. Interaction with the patient revealed, her goal was to resume her work as a nurse and her daily life activities as soon as possible without getting fatigued, for which the goal of the therapist became to focus on bronchial hygiene, followed by improving ventilation and oxygenation the lungs, followed by improving the functional capacity of the patient and prevent recurrence of such episodes of breathlessness while walking uphill. Since the patient was a medical service provider by occupation, she was well aware and educated about the importance of physiotherapy in her condition and she was very well motivated to get improved sooner. Promoting bronchial hygiene started with demonstrating and instructing the patient to perform ACBT (Active cycle of breathing technique) twice a day to enhance airway clearance. To improve ventilation and oxygenation, diaphragmatic exercise followed by segmental expansion exercises and incentive spirometer was performed, every 2 hourly (Fig 3).



**Figure 3** (a) Patient performing incentive spirometer; (b) patient taken in bed side sitting without support

As the patient's oxygen support reduced from 4L to 2L further to room air maintaining saturation at 98%, a monitored exercise program was started. The protocol included active limb mobility rehabilitation for upper and the lower extremities, twice daily at 10-12 repetitions. Further to improve functional capacity, light walking was initiated twice a day under the supervision of a physical therapist and monitoring the vitals especially, SPO<sub>2</sub> and pulse rate on an electrical device called Pulse Oximetry. As examination revealed decreased chest expansion, thoracic expansion exercises were also given at a pace of 10-12 repetitions for every 2 hours. The intensity and repetitions followed by the number of sets were gradually increased as tolerated by the patient.

As the patient got a discharge, a home exercise program was planned for the patient which was done through telerehabilitation (Fig 4). Strengthening and stretching exercises were incorporated into her treatment regime. The exercises were demonstrated by the physiotherapist and the patient was made to perform those under supervision. Strengthening of both the upper and the lower limbs was done using the available resources e.g. ½ L water bottle or sandbag targeted to 10 repetitions, 2 sets each; as tolerated by

the patient. Gradually the weight was increased to 1 L. Tele rehabilitation was given thrice every week. Remaining days, the patient was instructed to do the exercises by herself. Stretching included major muscle groups of the upper and lower body with 15 seconds hold repeated for 3 times. The online rehabilitation was given for about 4 weeks. The progression of the patient's condition was recorded on outcome measures mentioned below (Table 2).



**Figure 4** Patient performing upper limb strengthening exercise under the supervision of physiotherapist via telerehabilitation

**Table 2** shows the progression of the patient on the scales.

Outcome	Day 1	Week 4	Week 8
Dyspnea (MMRC score)	3	2	1
6-minute walk test	-	260m	400m
HADS	Severe	Moderate	Mild

## 4. DISCUSSION

Even with effective treatment, pulmonary TB can cause significant pulmonary function loss. Even though TB is treatable, it is nevertheless among the most prominent causes of pleural effusions. With 48–96 percent of sputum and more than 90% of fluid in the pleural space is negative for Acid-Fast Bacilli (AFB) stain & culture, diagnosing tuberculosis pleural effusion remains difficult. Tuberculous pleural effusions have a male-to-female ratio of 2:1, and unilateral TB pleural effusions account for roughly 95% of all TB pleural effusions. Fever and pleuritic chest discomfort are frequent presenting symptoms in this patient. Post-tuberculosis sequel harm all aspects of quality of life. Chronic respiratory disorders are linked to decreased functional capability, poor sleep quality, and a healthy mental state. Prolonged effect of persistent respiratory illnesses on fitness can be effectively tackled with a thorough pulmonary rehabilitation program.

The basic approaches for rehabilitating patients with worsening status due to respiratory problems include patient education, airway clearing procedures, breathing strategies, and a graded exercise training program. In this situation, a specialized rehabilitation program was developed and implemented (Chan et al., 2016). Not only can a well-planned inpatient rehabilitation produces good results, but a telerehabilitation-assisted home exercise program has also proven to be successful. Pulmonary rehabilitation (PR) is a multidisciplinary team-based, tailored, and a complete intervention for people suffering from chronic respiratory illness, such as post-TB sequel (Ando et al., 2003). The basic approach of pulmonary rehabilitation in post-TB sequelae is to treat dyspnoea.

In contrast to COPD, there is limited research on pulmonary rehabilitation in post-tuberculosis patients. Exercise training can be recommended for people with poor effort tolerance and reduced daily life activities. Even though muscle training has been demonstrated to improve exercise performance, there are no clear guidelines for the intensity of training and the appropriate threshold (as there are for COPD). In a study done in Japan, the outcomes in thirty two patients of COPD & post-TB, a nine-week outpatient PR program was examined. Dyspnoea (MRC scale), daily activities and exercise tolerance (6MWT) scores were all above average, the two groups had equal favorable benefits.

## 5. CONCLUSION

In our patient with a sequel from multiple relapses from tuberculosis led to functional and social disability and evidence shows that the pulmonary rehabilitation was safe and successful. The patient did not fully recover during the rehabilitation program, but the

majority of the treatment goals were met, such as clearing the airways to increase ventilation and SPO<sub>2</sub>, increasing the patient's exercise tolerance capacity, and reducing respiration work. Tele rehabilitation has given a new way to reach every patient in need of rehabilitation.

#### Acknowledgment

I am thankful to all the contributors in this study as well as to the patient for being cooperative.

#### Author contributions

All of the authors participated equally in this work, and the final manuscript was read and approved by the author.

#### Informed consent

All individuals who took part in the study gave their written and oral informed consent.

#### Funding

This study has not received any external funding.

#### Conflicts of interest

The authors declare that there are no conflicts of interests.

#### Data and materials availability

All data associated with this study are present in the paper.

## REFERENCES AND NOTES

1. Ando M, Mori A, Esaki H, Shiraki T, Uemura H, Okazawa M, Sakakibara H. The effect of pulmonary rehabilitation in patients with post-tuberculosis lung disorder. *Chest* 2003; 123(6):1988-95
2. Chan C, Yamabayashi C, Syed N, Kirkham A, Camp PG. Exercise Telemonitoring and Telerehabilitation Compared with Traditional Cardiac and Pulmonary Rehabilitation: A Systematic Review and Meta-Analysis. *Physiother Can* 2016; 68(3):242-251.
3. Hsu D, Irfan M, Jabeen K, Iqbal N, Hasan R, Migliori GB, Zumla A, Visca D, Centis R, Tiberi S. Post tuberculosis treatment infectious complications. *Int J Infect Dis* 2020; 92S:S41-S45.
4. Khan R, Malik NI, Razaque A. Imaging of Pulmonary Post-Tuberculosis Sequelae. *Pak J Med Sci* 2020; 36(1):S75-S82.
5. Shah M, Reed C. Complications of tuberculosis. *Curr Opin Infect Dis* 2014; 27(5):403-10.
6. Vorster MJ, Allwood BW, Diacon AH, Koegelenberg CFN. Tuberculous pleural effusions: advances and controversies. *J Thorac Dis* 2015; 7(6):981-91